

# Cyclin D1 as a Useful Marker for the Differentiation of Ewing's Sarcoma from Rhabdomyosarcoma

Tina Shooshtarizadeh, Ladan Fereidooni\*, Dorna Motevalli

Department of Pathology, School of Medicine, Iran University of Medical Sciences, Tehran, Iran

## Abstract

**Background:** The main oncogenic action of CD99 and cyclin D1 biomarkers is referred to any mutation, amplification, and overexpression in cyclin D1 coding gene, altering cell cycle progression as the main mechanism observed in a variety of tumors. A few studies attempted to detect the overexpression of cyclin D1 and CD99 and in certain types of tumors such as Ewing's sarcoma and rhabdomyosarcoma. The present study aimed to assess the prevalence of CD99 and cyclin D1 overexpression in these two types of tumors. We also described this overexpression according to the patients and tumor indicators.

**Methods:** This cross-sectional survey was performed on 30 consecutive patients with Ewing's sarcoma and 22 patients with rhabdomyosarcoma and hospitalized in Shafa hospital in Tehran between 2009 and 2014. The assessment of CD99 and cyclin D1 markers was based on immunohistochemical assessment using the formalin fixed and paraffin embedded tissue samples of the two tumors.

**Results:** Almost all Ewing's sarcomas had membranous patterns of CD99 while this marker was negative in most patients with rhabdomyosarcoma. Therefore, detecting membranous CD99 could specifically detect Ewing's sarcoma and distinguish it from rhabdomyosarcoma. Moreover, contrary to rhabdomyosarcoma which is accompanied with lower cyclin D1 intensity, all Ewing's sarcomas were characterized by moderate to severe cyclin D1 intensity. Similarly, almost all those with Ewing's sarcoma had diffuse cyclin D1 extension; whereas, the pattern of cyclin D1 extension in rhabdomyosarcoma was mostly negative or focal.

**Conclusion:** The detection of CD99 and cyclin D1 overexpression and their intensity and extension patterns can specifically distinguish Ewing's sarcoma from rhabdomyosarcoma.

**Keywords:** Ewing's sarcoma, Rhabdomyosarcoma, Cyclin D1

◆Corresponding Author:  
Ladan Fereidooni, MD  
Department of Pathology,  
School of Medicine, Iran  
University of Medical  
Sciences, Tehran, Iran  
Tel: +98 9173026393  
Email: ladan.fereidooni@gmail.com

## Introduction

Ewing's sarcoma (EWS) and rhabdomyosarcoma (RMS) are both

categorized as small-round-blue-cell tumors (SRBCT), a group of malignant neoplasms sharing similar

histology with vastly different prognosis and treatment. Although the differential diagnosis of these lesions is of clinical importance, their differentiation might be challenging, particularly if EWS arises in the soft-tissue component of the limb, known as extra-osseous EWS. Differentiation of EWS from the solid-variant of alveolar RMS is also a histological challenge. Moreover, EWS may show atypical histologic morphologies, including spindle cell, large cell or "adamantinoma-like" features, as well as diffuse and abundant hyalinized matrix, which poses serious diagnostic problems with other malignancies.<sup>1-4</sup>

Although CD99 and FLI-1 are currently the most accepted immunohistochemical (IHC) markers for EWS, their accuracy is controversial.<sup>4</sup> While CD99 is expressed in nearly all cases of EWS, it is also occasionally expressed in RMS.<sup>5</sup> Similarly, while antibodies against FLI-1 have been tested in EWS with a nearly high sensitivity, its specificity is still a matter of debate.<sup>4,6,7</sup> Actin, Myosin, Myoglobin, and Desmin have proven useful in the diagnosis of RMS; however, these markers lack absolute sensitivity and/or specificity.<sup>8,9</sup> Thus, there is an increasing reluctance among oncologists to accept the diagnosis of EWS and RMS without cytogenetic and molecular genetic analysis of the known translocations.<sup>2, 9, 10</sup> Nonetheless, the diagnosis of EWS and RMS continues to be based on morphology and IHC analyses because cytogenetic testing and/or molecular evaluation are not routinely available in a great majority of surgical pathology departments.<sup>4</sup> Accordingly, several investigations have attempted to identify valuable IHC markers that might be conducive to the differentiation of EWS from its morphological mimics such as RMS.

Cyclin D1 is an important regulator of cell cycle progression, and its overexpression has been associated with the development and progression of many types of cancer.<sup>1</sup> In vitro studies have shown that cyclin D1 is overexpressed in EWS but not in RMS cell lines.<sup>12</sup> Subsequently, Magro et al. performed a comparative IHC analysis on the expression and

distribution of cyclin D1 in a large series of soft tissue EWS and RMS in order to assess its potential usefulness in their differential diagnosis. Based on their results, overexpression of cyclin D1 in EWS/PNET could be exploitable as a diagnostic immunomarker for this tumor and its differentiation from RMS as well.<sup>3</sup> However, there is not sufficient evidence on the diagnostic potential of cyclin D1 in EWS.

Accordingly, the objective of the current study was to further investigate the IHC expression of cyclin D1 in the context of CD99 in EWS and RMS paraffin-embedded tissue. This was done to explore how this combination of markers could contribute to the differential diagnosis of these lesions.

### Patients and Methods

In a cross-sectional study, approved by the Ethics Committee of Iran University of Medical Sciences (code No.: 2218), we assessed and compared the extent and intensity of cyclin D1 and pattern of CD99 expression in formalin fixed paraffin-embedded tissues of EWS and RMS.

IHC was performed on a 4 µm tissue section using mouse monoclonal antibody anti-human CD99 (company, country, cat num) and anti-human cyclin D1 (company, country, cat num). We carried out staining according to the manufacturer's instructions and using the envision method. In brief, sections were mounted on poly-lysine coated slides and dried in an oven at 60°C for 60 min. Following deparaffinization and rehydration, we immersed the tissue sections in methanol containing 0.3% hydrogen peroxide for 20 min so as to block the potential endogenous peroxidase activity. Subsequently, the sections underwent antigen retrieval process by autoclaving in citrate buffer (pH=6) for 10 min. The sections were then incubated with primary antibody for 1 h at an optimal dilution of 1/50 and secondary antibody (Envision System, Dako, Denmark) for 30 min. Afterwards, the sections were treated with 3,3'-Diaminobenzidine (DAB, Dako) as the chromogen and counterstained with hematoxylin (Dako). Finally, after the dehydration steps, we mounted the sections under glass coverslips and

analyzed them under a light microscope. For negative control slides, the primary antibody was replaced with washing buffer.

Using the Allred scoring method, we semi-quantitatively scored the expression extent and intensity of cyclin D1 immunoreactivity. In this respect, we recorded the intensity as 0 (negative) when no staining of the tumoral cells' nuclei was observed even at high magnifications, 1 (weak) if staining was visible only at high magnifications, 2 (moderate) when staining was readily visible at low magnifications, and 3 (strong) if staining was strikingly positive even at low power magnifications.<sup>13</sup> The expression pattern was stratified as negative, focal, heterogeneous, or diffuse. We categorized the CD99 expression pattern into three groups, namely negative, membranous, and cytoplasmic.<sup>14</sup>

### Statistical analysis

The mean and standard deviation (SD) showed the central tendency and variability for continuous variables, respectively. Categorical variables were compared using chi-square test or Fisher's exact test. *P*-Values less than 0.05 were considered as statistically significant. All statistical analyses were performed by use of IBM SPSS for windows, version 16.

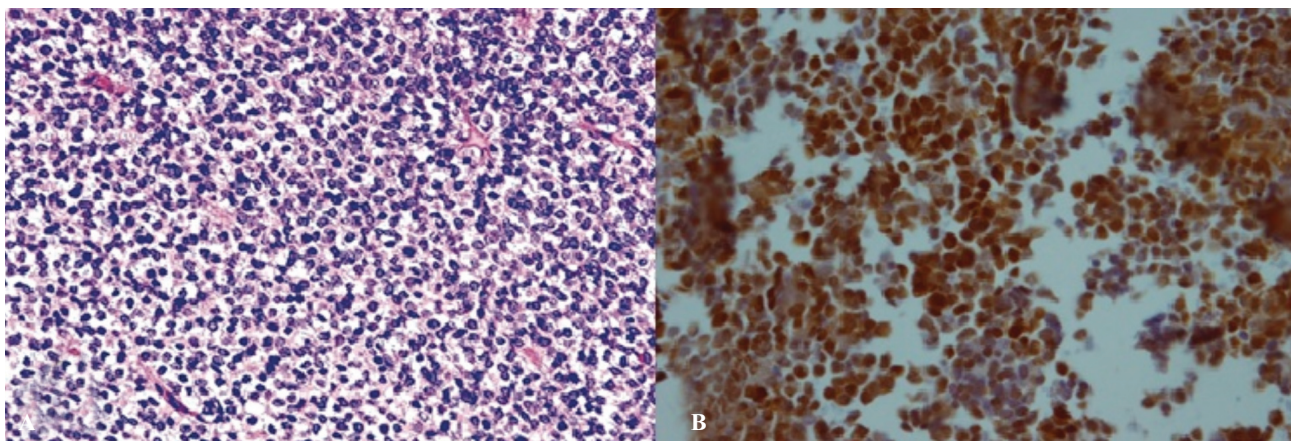
### Results

In total, 30 EWS patients (19 males and 11 females) and 22 RMS patients (11 males and 11 females) were enrolled in this study. The mean

age of EWS and RMS patients was (18.23±10.4) and (9.5±14.3) years, respectively. Regarding tumor location, 43.3% of EWS cases were located in long bones while 20% and 36.7% were located in flat bones and soft tissues, respectively. In RMS patients, 40.9% and 59.1% of the cases were located in soft tissues and mucosal tissues, respectively.

While CD99 pattern was membranous in all EWS tumors (100%), it was negative in 86.4% of RMS tumors and cytoplasmic in 9.1% (*P*< 0.001). A strong cyclin D1 intensity was observed in 2/3 of EWS tumors; whereas, moderate intensity was observed in the remaining 1/3 of EWS tumors. By contrast, 45.5% of RMS sections demonstrated negative cyclin D1 intensity, followed by 31.8% and 22.7% presenting with weak and moderate intensity, respectively (*P*< 0.001) (Figure 1). The two types of tumors were significantly different regarding cyclin D1 extension pattern such that 93.3% of EWS sections showed diffuse pattern of cyclin D1; however, 90% of those with RMS demonstrated negative or focal extension pattern of cyclin D1 (*P*< 0.001) (Figure 2). Table 1 shows the demographic and pathologic characteristics of the patients in detail.

There was no significant association between the demographic characteristics of the patients and the expression patterns of CD99 and cyclin D1. Moreover, we did not observe a significant relationship between the location of the tumors and the expression patterns of CD99 and cyclin D1.



**Figure 1.** Positive cyclin D1 immunostaining in Ewing's sarcoma: A) H&E section B) Diffuse positive immunostaining pattern.

**Table 1.** The clinicopathologic and demographic characteristics of the patients

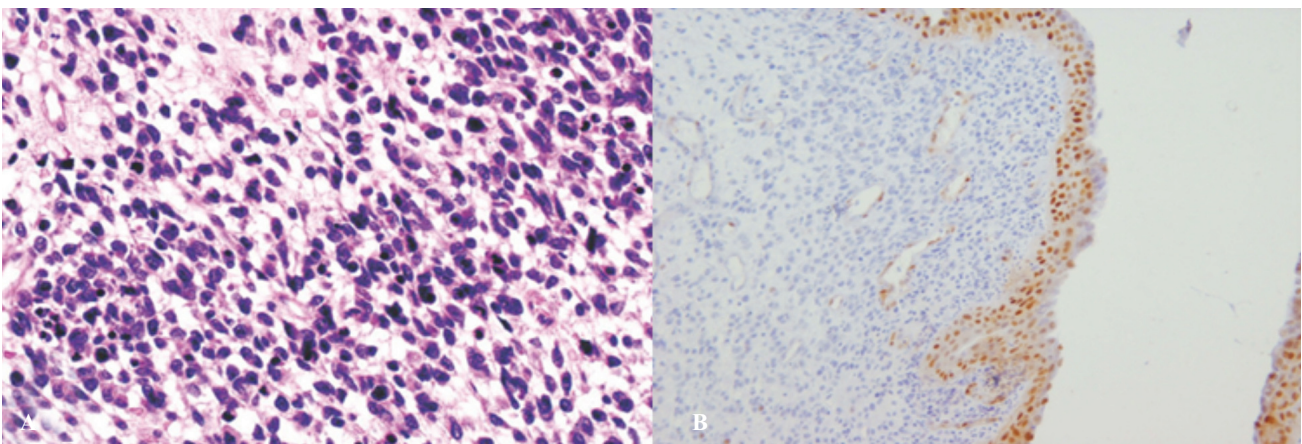
Characteristics	EWS (n=30)	RMS (n=22)
Age	18.23±10.4	9.5±14.3
<b>Gender</b>		
Male	19 (63.7)	11 (50)
Female	11 (36.7)	11 (50)
<b>Location</b>		
Long bone	13 (43.3)	-
Flat bone	6 (20)	-
Soft tissue	11 (36.7)	9 (40.9)
Mucosal Tissue	-	13 (59.1)
<b>CD99 pattern</b>		
Negative	-	19 (86.4)
Membranous	30 (100)	1 (3.2)
Cytoplasmic	-	2 (9.1)
<b>Cyclin D1 intensity</b>		
Negative	-	10 (45.5)
Weak	-	7 (31.8)
Moderate	10 (33.3)	5 (22.7)
Strong	20 (66.7)	0
<b>Cyclin D1 pattern</b>		
Negative	-	10 (45.5)
Focal	-	10 (45.5)
Heterogeneous	2 (6.7)	2 (9)
Diffused	28 (93.3)	-

EWS: Ewing's sarcoma; RMS: Rhabdomyosarcoma; Data are shown as mean±SD or number (%).

## Discussion

Our results showed the moderate to strong intensity of cyclin D1 in EWS sections; however, the intensity of cyclin D1 was negative or weak in the majority of RMS sections (17 out of 22 cases). In this respect, no strong cyclin D1 intensity existed in the cases of the latter group, while it was seen in two thirds of EWS lesions. In addition, the pattern of expression was diffused in the majority of EWS cases (28 out of 30 cases)

and negative or focal in the majority of RMS sections (20 out of 22 cases). In this regard, there was no diffused expression pattern of cyclin D1 in RMS tissues' staining. Our investigation further demonstrated a membranous pattern of CD99 in all EWS tissues while CD99 expression was negative in the majority of evaluated RMS sections (19 sections) and positive in only three sections (two cytoplasmic and one membranous). Based on these results, it can be concluded that the



**Figure 2.** Negative cyclin D1 immunostaining in rhabdomyosarcoma: A) H&E section B) Negative immunostaining pattern.

strong intensity and diffused expression pattern of cyclin D1 and the membranous pattern of CD99 favor the diagnosis of EWS; therefore, cyclin D1 could be suggested as a reliable complementary marker in the differential diagnosis of EWS and RMS, particularly when their differentiation imposes a challenge.

Despite the development of several IHC diagnostic markers for small round blue cell tumors, the differential diagnosis of these lesions is still challenging and poses serious problems in certain cases. Among the pediatric small round blue cell tumors, it might be more challenging to differentiate EWS from alveolar RMS.<sup>4</sup> Consequently, it is highly necessary to identify reliable IHC markers for the diagnosis of EWS and RMS.

Cyclin D1 is a protein required for the progression of cell proliferation through G1 phase of the cell cycle.<sup>15</sup> Deregulation of cyclin D1 has been reported in several types of cancer and its overexpression has been correlated with shorter survival and increased metastasis rates.<sup>16</sup> Analysis of cyclin D1 expression also provides vital diagnostic information regarding carcinogenesis and contains prognostic values in several cancers.<sup>17</sup> Its deregulation in small round blue cell tumors has also been recently reported.<sup>18,19</sup> Accordingly, we aimed to further evaluate the diagnostic value of cyclin D1 in the differentiation of EWS from RMS.

Fuchs et al. evaluated the expression of cyclin D1 in EWS sections for the first time in 2004. They stained 31 tissue samples from patients suffering from EWS with antibodies against cyclin D1. Based on their report, positive cyclin D1 staining was present in 42% of all evaluated tumors. There was no report on the intensity and expression pattern of cyclin D1 in their study. They concluded that cyclin D1 overexpression is of importance in EWS pathogenesis.<sup>19</sup> In line with this evidence, Margo et al. decided to evaluate the diagnostic potential of cyclin D1 in 2015. They performed a comparative IHC analysis on the expression and distribution of cyclin D1 in a large series of soft tissue EWS/pPNETs and RMS (both embryonal and alveolar subtypes) to assess

its potential usefulness in their differential diagnosis. Based on their report, cyclin D1 was strongly and diffusely expressed in all cases (20/20) of EWS/pPNET, while it was absent in all RMS cases (15/15). They concluded that a strong and diffuse nuclear expression of cyclin D1 is of complementary diagnostic value to CD99 and FLI-1 in confirming the diagnosis of EWS/pPNET, and ruling out RMS.<sup>3, 18</sup>

Although our results are very similar to that of Margo's study, some minor differences can also be observed. As the most important difference, the intensity of cyclin D1 was moderate in one third of our patients, while strong in all patients of Margo's study. This inconsistency could be attributed to the difference in tumor characteristics. While both intra- and extra-osseous EWS patients were included in our study, Margo et al. only included soft-tissue EWS in their study.<sup>18</sup>

Moreover, the stage of the included tumors was not considered in either studies. This could be considered as the biggest limitation of the present study. Potentially, staging is able to influence the expression pattern of markers, where a higher expression is expected at higher stages. Therefore, this feature is recommended for consideration in future investigations. Among other limitations of our study, we can mention the lack of confirmatory molecular tests and the limited sample size. An important strength of this study is the precise evaluation of IHC patterns of staining in the examined tumors.

## Conclusion

Consistent with previous studies, our results showed that CD99 is an important primary marker for the differentiation of EWS and RMS, and cyclin D1 is a complementary immunomarker of EWS. Moreover, given different expression pattern of cyclin D1 in EWS and RMS, it may successfully be used in differentiating EWS from RMS when their differentiation is challenging.

## Conflicts of Interest

None declared.

## References

- Harms D, Leuschner I, Krams M, Pilgrim TB, Treuner J. Rhabdomyosarcoma and extraosseous Ewing's sarcoma. [Article in German] *Verh Dtsch Ges Pathol.* 1998;82:83-98.
- Weiss SW, Goldblum JR. *Liposarcoma enzinger and Weiss's soft tissue tumors.* 5<sup>th</sup> ed. Mosby Inc.: St. Louis; 2008.p. 903-941.
- Magro G, Brancato F, Musumeci G, Alaggio R, Parenti R, Salvatorelli L. Cyclin D1 is a useful marker for soft tissue Ewing's sarcoma/peripheral primitive neuroectodermal tumor in children and adolescents: A comparative immunohistochemical study with rhabdomyosarcoma. *Acta Histochem.* 2015;117(4-5):460-7. doi: 10.1016/j.acthis.2015.01.005.
- Tsokos M, Alaggio RD, Dehner LP, Dickman PS. Ewing sarcoma/peripheral primitive neuroectodermal tumor and related tumors. *Pediatr Dev Pathol.* 2012;15(1 Suppl):108-26. doi: 10.2350/11-08-1078-PB.1.
- Hess E, Cohen C, DeRose PB, Yost BA, Costa M J. Nonspecificity of p30/32MIC2 immunolocalization with the O13 monoclonal antibody in the diagnosis of Ewing's sarcoma: application of an algorithmic immunohistochemical analysis. *Appl Immunohistochem.* 1997;5(2):94-103
- Folpe AL, Hill CE, Parham DM, O'Shea PA, Weiss SW. Immunohistochemical detection of FLI-1 protein expression: a study of 132 round cell tumors with emphasis on CD99-positive mimics of Ewing's sarcoma/primitive neuroectodermal tumor. *Am J Surg Pathol.* 2000;24(12):1657-62. doi: 10.1097/00000478-200012000-00010.
- Llombart-Bosch A, Navarro S. Immunohistochemical detection of EWS and FLI-1 proteins in Ewing sarcoma and primitive neuroectodermal tumors: comparative analysis with CD99 (MIC-2) expression. *Appl Immunohistochem Mol Morphol.* 2001 Sep;9(3):255-60.
- Miettinen M. Antibody specific to muscle actins in the diagnosis and classification of soft tissue tumors. *Am J Pathol.* 1988;130(1):205-15.
- Parham DM, Dias P, Kelly DR, Rutledge JC, Houghton P. Desmin positivity in primitive neuroectodermal tumors of childhood. *Am J Surg Pathol.* 1992;16(5):483-92.
- Sorensen PH, Lynch JC, Qualman SJ, Tirabosco R, Lim JF, Maurer HM, et al. PAX3-FKHR and PAX7-FKHR gene fusions are prognostic indicators in alveolar rhabdomyosarcoma: a report from the children's oncology group. *J Clin Oncol.* 2002;20(11):2672-9.
- Alao JP. The regulation of cyclin D1 degradation: roles in cancer development and the potential for therapeutic invention. *Mol Cancer.* 2007;6(1):24.
- Zhang J, Hu S, Schofield DE, Sorensen PH, Triche TJ. Selective usage of D-Type cyclins by Ewing's tumors and rhabdomyosarcomas. *Cancer Res.* 2004;64(17):6026-34.
- Hammond ME, Hayes DF, Dowsett M, Allred DC, Hagerty KL, Badve S, et al. American Society of Clinical Oncology/College of American Pathologists guideline recommendations for immunohistochemical testing of estrogen and progesterone receptors in breast cancer (unabridged version). *Arch Pathol Lab Med.* 2010;134(7):e48-72. doi:10.1043/1543-2165-134.7.e48.
- Olsen SH, Thomas DG, Lucas DR. Cluster analysis of immunohistochemical profiles in synovial sarcoma, malignant peripheral nerve sheath tumor, and Ewing sarcoma. *Mod Pathol.* 2006;19(5):659-68.
- Baldin V, Lukas J, Marcote MJ, Pagano M, Draetta G. Cyclin D1 is a nuclear protein required for cell cycle progression in G1. *Genes Dev.* 1993;7(5):812-21.
- Donnellan R, Chetty R. Cyclin D1 and human neoplasia. *Mol Pathol.* 1998;51(1):1-7.
- John RR, Malathi N, Ravindran C, Anandan S. Mini review: Multifaceted role played by cyclin D1 in tumor behavior. *Indian J Dent Res.* 2017;28(2):187-192. doi: 10.4103/ijdr.IJDR\_697\_16.
- Magro G, Salvatorelli L, Alaggio R, D'Agata V, Nicoletti F, Di Cataldo A, et al. Diagnostic utility of cyclin D1 in the diagnosis of small round blue cell tumors in children and adolescents. *Hum Pathol.* 2017;60:58-65. doi: 10.1016/j.humpath.2016.07.038.
- Fuchs B, Inwards CY, Janknecht R. Vascular endothelial growth factor expression is up-regulated by EWS-ETS oncoproteins and Sp1 and may represent an independent predictor of survival in Ewing's sarcoma. *Clin Cancer Res.* 2004;10(4):1344-53.