

## Low-grade Myxofibrosarcoma in the Mandible: A Rare Case Report

Neda Kargahi\*, Elham Arjang\*\*, Shirin Shahnasari\*\*\*, Forooz Keshani\*<sup>♦</sup>

\*Dental Research Center, Department of Oral and Maxillofacial Pathology, School of Dentistry, Isfahan University of Medical Sciences, Isfahan, Iran

\*\*Post-Graduate Student of Oral and Maxillofacial Pathology, School of Dentistry, Isfahan University of Medical Sciences, Isfahan, Iran

\*\*\*Dental Implant Research Center, Department of Oral and Maxillofacial Surgery, School of Dentistry, Isfahan University of Medical Sciences, Isfahan, Iran

### Abstract

Myxofibrosarcoma is a malignant neoplasm of connective tissue origin commonly found in the extremities. It is very rare in the head and neck regions. Only 25 cases of myxofibrosarcoma have been reported in the head and neck regions until 2014. Here we report a 61-year-old male with this neoplasm in the lower border of his mandible. During a two-year follow-up, this case recurred four times despite a complete resection. This study suggested combined surgical and adjuvant radiotherapy for unresectable lesions and tumors with positive margins to prevent recurrence and risk of progression.

**Keywords:** Mandible, Myxofibrosarcoma

### Introduction

Sarcomas comprise less than one percent of all malignancies in the head and neck areas.<sup>1</sup> Myxofibrosarcoma (MFS) and myxosarcoma are connective tissue neoplasms with a fibroblastic origin in a myxoid stroma.<sup>2</sup> Since this lesion is extremely rare in the head and neck areas and has a tendency toward multiple local recurrences, its correct and rapid diagnosis is very important. Morphology and immunohistochemistry are two powerful tools that help confirm its diagnosis.<sup>3</sup> According to the English literature, 20 cases of

this neoplasm have been reported in the head and neck regions; few cases have been reported in the mandible.<sup>4</sup> This study reported the second case of MFS that arose from the mandible and reviewed the clinical, histopathological features, differential diagnosis, immunohistochemical analysis, and treatment approaches of this neoplasm.

### Case report

In August 2015, a 61-year-old male patient with complaints of a painless, swollen, firm mass in the lower border of his mandible referred to the Department of Oral and

#### <sup>♦</sup>Corresponding Author:

Forooz Keshani, DDS, MSc  
Dental Research Center,  
Department of Oral and  
Maxillofacial Pathology, School  
of Dentistry, Isfahan University  
of Medical Sciences, Isfahan,  
Iran  
Tel: 09133088878  
Email: f\_keshani@dent.mui.ac.ir

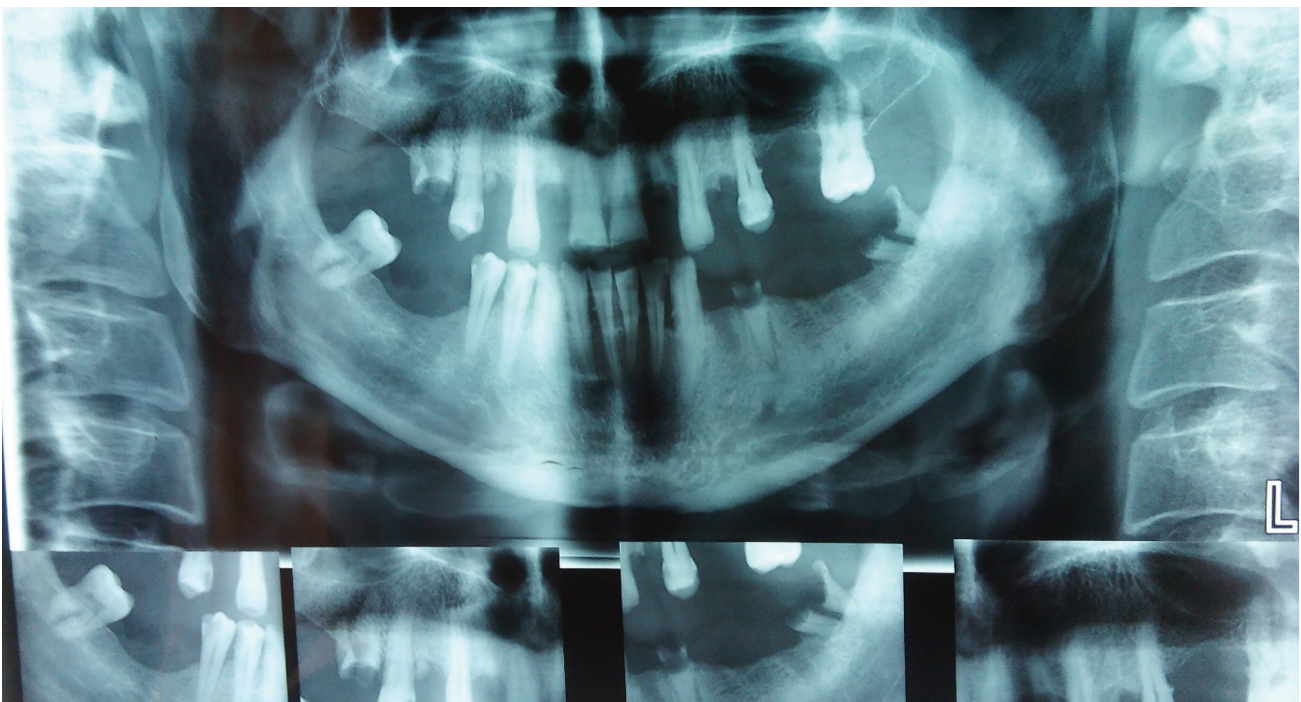
Maxillofacial Surgery at Isfahan Dental School, Isfahan, Iran. He had no history of trauma or infection in this region. The cervical lymph node was not palpable. Clinical examination showed no intraoral findings, and the patient had no history of systemic diseases. There were no significant radiographic findings (Figure 1).

In 2013, the tumor initially arose from the lower border of the right mandible and was removed. Unfortunately, despite numerous follow-ups, we could not obtain information about the previous diagnosis and surgical conditions. In March 2014, the lesion recurred at the same site and the patient underwent excision by a general surgeon. The follow-up showed that the lesion recurred for the third time in August 2015 at the same location. The lesion was capsulated and removed in one piece by an oral and maxillofacial surgeon. For the fourth time, the patient follow-up in January 2016 showed tumor recurrence, which was removed by the previous surgeon. This time, due to facial nerve involvement, the lesion was not completely removed in order to prevent nerve damage. The patient was recommended for adjuvant radiotherapy. However, at a recent follow up, he explained that he had not started radiotherapy. Because of the patient's

imagination of well-being, he did not return for subtle clinical and paraclinical follow-up examinations. Microscopic examination revealed spindle cell proliferation with mild atypia and increased nuclear-to-cytoplasmic ratio. The tumor was composed of hypocellular and moderate cellular areas. The stroma was myxoid with characteristic curvilinear blood vessels (Figure 2).

Based on pathologic findings, the differential diagnosis consisted of benign and malignant myxoid soft tissue tumors such as nodular fasciitis, myxoma, spindle cell lipoma, nerve sheath tumor, myxoid liposarcoma, low grade fibromyxoid sarcoma, malignant fibrous histiocytoma (MFH), and extraskeletal myxoid chondrosarcoma.

Immunohistochemically, the tumor cells were positive for vimentin and negative for S100 and CK. The Ki67 labeling index was 1%, which indicated a low proliferative tumor cell activity (Figure 3). Accordingly, we eliminated tumors of neural, epithelial or cartilage origins. Low grade MFS could be considered based on the immunohistochemical staining. There was no evidence of recurrence during the 10-month postoperative follow-up.



**Figure 1.** Radiographic view which did not show any pathologic bone destruction.



## Discussion

Sarcomas are rare malignancies in the head and neck areas without any obvious etiology.<sup>5</sup> Myxofibrosarcomas are one of the most common sarcomas in elderly patients with a slight male predominance.<sup>6</sup> This tumor mostly arises in the extremities, whereas they rarely present in the head and neck areas. Merely 20 cases of this tumor have been reported in the head and neck areas until 2014.<sup>4</sup> This case study was the second case reported in the mandible region. Myxofibrosarcoma has been divided into three<sup>6,7</sup> to four<sup>6-8</sup> grades based on presence of pleomorphic nuclei, mitotic activity, and cellularity.

Low grade MFS can sometimes be confused with myxoid malignant MFH. The myxoid type of MFH is composed of myxoid stroma. It is associated with the cellular area and distinguishable from ordinary MFH. Low-grade MFS occurs in younger people, with multiple recurrences, and rarely has distant metastasis. Histopathological features are remarkable for mild spindle cells in a spiral pattern and arranged in myxoid and fibrous stromas.<sup>9</sup> Weiss and Enzinger have indicated that MFHs that contain more myxoid and hypocellular features had better prognosis compared to the non-myxoid type.<sup>10</sup> This finding has been

observed in other lesions such as low grade fibromyxoid sarcoma, MFS, and myxoid MFHs; therefore, it is difficult to differentiate these lesions.<sup>9</sup>

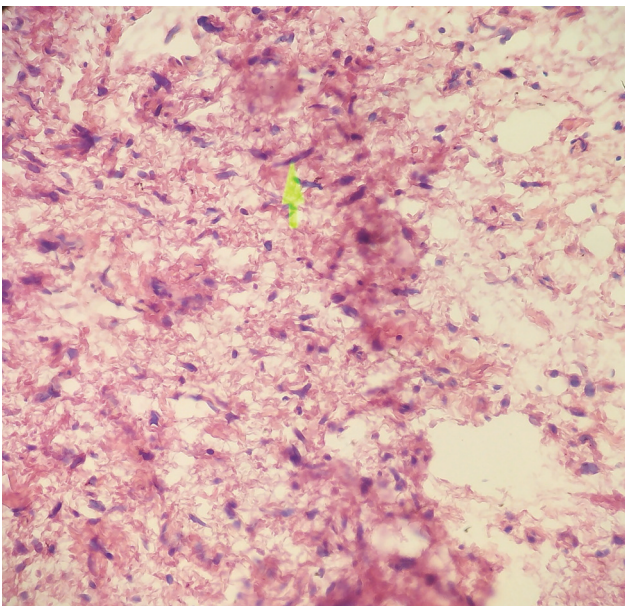
Immunohistochemical analysis is the basis of diagnosis after histopathological analysis. Based on the study of Antonescu and Baren, microscopic analysis, S100 immunostaining, and ultrastructural assessment assist with differentiation of MFS from fibromyxoid sarcoma.<sup>11</sup>

Positive reaction to vimentin and negative reaction to CK, S100 and desmin confirm the diagnosis of MFS in addition to low proliferative activity estimated by low mitotic count and a low Ki67 labeling index.<sup>3</sup> Low-grade MFS is considered a low-grade malignancy that rarely undergoes distant metastasis and its short time prognosis is good.<sup>12</sup>

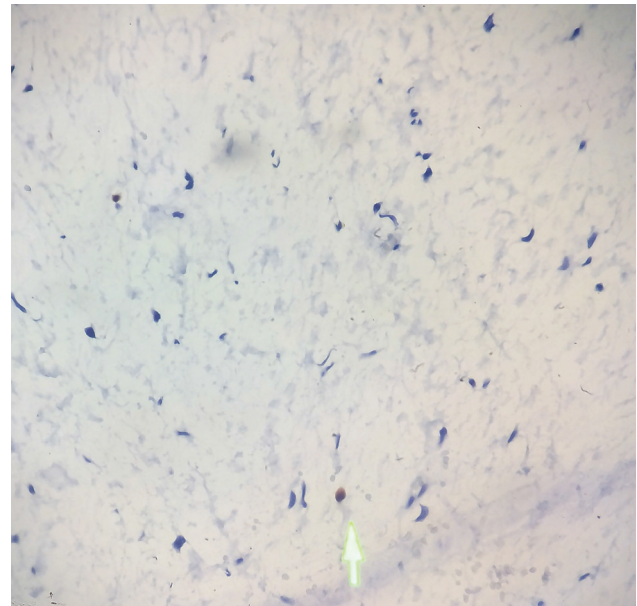
In their study, Mentzel et al. in a review of 75 patients with low-grade MFS showed 55% local recurrence and 33% distant metastasis.<sup>6</sup>

Weiss and Enzinger have proposed that these tumors have a higher metastatic ability and are more aggressive in deep structures.<sup>10</sup>

The main treatment for this tumor is complete excision with safe margins. Radiotherapy is used for recurrent, unresectable lesions or tumors with positive resection margins in order to prevent



**Figure 2.** Spindle cell proliferation with mild atypia and increased nuclear-to-cytoplasmic ratio (H & E; 100×).



**Figure 3.** Immunohistochemistry. Ki67 labeling index was 1% (IHC; 100×).

local recurrence and risk of progression. Use of chemotherapy for low-grade MFS is still debatable.<sup>13</sup>

In the above case, the patient underwent surgery and was recommended for adjuvant radiotherapy due to multiple recurrences and positive margins (because of facial nerve involvement). The overall 5-year survival rate of patients is 60%-70%.<sup>12</sup> However, the local recurrence rate of low-grade MFS is as high (50%-60%) as high-grade MFS.<sup>3</sup> Thus, the patient should be followed for an extended period of time.

### Conflict of Interest

No conflict of interest is declared.

### References

1. Farhood AI, Hajdu SI, Shiu MH, Strong EW. Soft tissue sarcomas of the head and neck in adults. *Am J Surg.* 1990;160(4):365-9.
2. O'brien JE, Stout AP. Malignant fibrous xanthomas. *Cancer.* 1964;17:1445-55.
3. Salama A, Hafez N, Abu-Sinna E, Hassouna A, Amin AA. Myxofibrosarcoma of the thyroid: Second case in Africa. *J Cytol Histol.* 2014 ;5(5):257.
4. Dell'Aversana Orabona G, Iaconetta G, Abbate V, Piombino P, Romano A, Maglitta F, et al. Head and neck myxofibrosarcoma: a case report and review of the literature. *J Med Case Rep.* 2014;8:468.
5. Sturgis EM, Potter BO. Sarcomas of the head and neck region. *Curr Opin Oncol.* 2003;15(3):239-52.
6. Mentzel T; Van den, BE.; Molenaar, WM. Myxofibrosarcoma. In Fletcher, C; Unni, KK; Mertens, F, editors. WHO classification of tumours. Pathology and genetics. Tumours of soft tissue and bone. Lyon: IARC Press; 2002.p.102-103.
7. Huang HY, Lal P, Qin J, Brennan MF, Antonescu CR. Low-grade myxofibrosarcoma: a clinicopathologic analysis of 49 cases treated at a single institution with simultaneous assessment of the efficacy of 3-tier and 4-tier grading systems. *Hum Pathol.* 2004;35(5):612-21.
8. Angervall L, Kindblom LG, Merck C. Myxofibrosarcoma. A study of 30 cases. *Acta Pathol Microbiol Scand A.* 1977;85A(2):127-40.
9. Nishimura G, Sano D, Hanashi M, Yamanaka S, Tanigaki Y, Taguchi T, et al. Myxofibrosarcoma of the hypopharynx. *Auris Nasus Larynx.* 2006;33(1):93-6.
10. Weiss SW, Enzinger FM. Myxoid variant of malignant fibrous histiocytoma. *Cancer.* 1977;39(4):1672-85.
11. Antonescu CR, Baren A. Spectrum of low-grade fibrosarcomas: a comparative ultrastructural analysis of low-grade myxofibrosarcoma and fibromyxoid sarcoma. *Ultrastruct Pathol.* 2004;28(5-6):321-32.
12. Nishio J, Iwasaki H, Nabeshima K, Naito M. Cytogenetics and molecular genetics of myxoid soft-tissue sarcomas. *Genet Res Int.* 2011;2011:497148.
13. Lam PK, Trendell-Smith N, Li JH, Fan YW, Yuen AP. Myxofibrosarcoma of the sphenoid sinus. *J Laryngol Otol.* 2002;116(6):464-6.