

The Role of Radical Dose of Radiotherapy in Hepatocellular Carcinoma

Maher Soliman, MD, PhD

Oncology Department, Faculty of Medicine, Alexandria University, Alexandria, Egypt

Please cite this article as:
Soliman M. The role of radical dose of radiotherapy in hepatocellular carcinoma. Middle East J Cancer. 2022;13(3):483-90. doi: 10.30476/mejc.2022.87504.1417.

Abstract

Background: The incidence of hepatocellular carcinoma has significantly increased over the last decades and the prognosis of hepatocellular carcinoma still remains poor. The present study aimed to evaluate the efficacy and safety of 3D conformal hypofractionated radiotherapy in patients with small hepatocellular carcinoma.

Method: Between 2015 and 2018, a total of 61 patients presented to our institution with hepatocellular carcinoma ≤ 5 cm, who were recruited in this prospective study. All the patients underwent 3D conformal hypofractionated radiotherapy with a total dose of 51 Gy in 17 fractions. We evaluated the treatment response and toxicity and calculated the local progression-free survival and overall survival.

Results: The objective response rate was 68.9%, including seven patients (11.5%) achieving complete response and 35 patients (57.4%) with partial response. In addition, nine subjects (14.8%) had stable disease. The 1-, 2-, and 3-year overall survival rates were 65.1%, 38.7%, and 26.4%, respectively. In multivariate Cox regression model, GTV was found to be the only prognostic factor for local control ($P = 0.001$) and overall survival ($P < 0.001$). Only one patient showed grade 3 radiation-induced hepatic toxicity (1.6%).

Conclusion: 3D conformal hypofractionated radiotherapy could be effective and safe in small hepatocellular carcinoma.

Keywords: Carcinoma, Hepatocellular, Hypofractionated, Radiotherapy, Survival

Introduction

Hepatocellular carcinoma (HCC) is the sixth most prevalent cancer worldwide and the third most common cause of cancer-related death.^{1,2} There has been a significant increase in the incidence of HCC among Egyptian population over the last decades.^{3,4} The reason behind this rising incidence could be (1)

implementation of national presidential campaign of hepatitis C virus treatment, allowing further population to be registered for screening program and diagnostic tools, (2) the increased survival rate of patients with cirrhosis, which raises the chance of developing HCC, and (3) the rise in the incidence of hepatitis C virus, which is considered

♦Corresponding Author:
Maher Soliman, MD
Oncology department, Faculty of Medicine, Alexandria University, Alexandria, Egypt
Tel/Fax: (+2) 03-4848280
E-mail: mahersoliman@daad-alumni.de



as the predominant risk factor in developing HCC in Egypt.^{3,4}

Despite the great improvements in the diagnosis and treatment of HCC over the recent years, its prognosis remains poor. This is due to the difficulty in diagnosis of HCC at an early stage and quick progression. Surgery remains the mainstay treatment for localized HCC. However, surgery is often precluded by poor hepatic functional reserve, and unfortunately, liver transplantation has prolonged waiting times and waiting list for donors. Moreover, a number of patients deny surgery or unfit for surgery due to comorbidities.⁵⁻⁸

The recently-developed non-surgical management for unresectable HCC, such as percutaneous ethanol injection, percutaneous microwave coagulation therapy, percutaneous radiofrequency ablation, transcatheter arterial chemoembolization, and radiotherapy, have been shown to improve local tumor control, prolong survival time, and improve the quality of life to some extent.^{5,9}

Lately, growing evidence has indicated that HCC is sensitive to radiotherapy unlike the previous general belief. In addition, the advanced radiotherapeutic techniques have broaden the therapeutic horizons by increasing the dose delivered to focal hepatic lesions and minimizing the X-ray toxicity to normal liver tissue. Despite the fact that several clinical trials have evaluated the role of radiotherapy in HCC, the optimal radiotherapy dose and fractionation still remain undetermined.¹⁰⁻¹⁵

The current prospective study aimed to evaluate the efficacy of radical dose of hypofractionated radiotherapy in patients with a small HCC lesion deemed unsuitable for other locoregional therapies.

Materials and Methods

Patients

In this single-arm prospective clinical trial, a total of 61 patients who presented to Alexandria Main University Hospital with established diagnosis of HCC between July 2015 and June 2018 were enrolled in the trial. The eligibility

criteria were as follows: (a) primary HCC without previous treatment; (b) patients unfit for surgery due to comorbidities or who refused to undergo surgery or other ablative therapies; (c) solitary HCC lesion ≤ 5 cm; (d) Child-Pugh class A or B cirrhosis; (e) Eastern Cooperative Oncology Group performance status of 0 - 1; (f) signing the informed consent. The exclusion criteria were as follows: (a) extrahepatic metastases; (b) multicentric HCC; (c) sizable lesion > 5 cm; (d) liver metastases; and/or (e) intrahepatic cholangiocarcinoma; (f) prior chemotherapy or targeted therapy. Our institutional research ethics committee approved the present work which is registered under the number 38/29/16/4/2015.

Radiation therapy

For radiotherapy planning, all the patients were simulated using computed tomography (CT) scan in the supine position with both arms raised above the head. Every patient was instructed to fasten a graded belt to a fixed point at the level of umbilicus to restrict the respiration induced organ movement. CT scan data were transferred to the treatment planning system. The gross tumor volume (GTV) was generated based on contrast CT scan and positron emission tomography (PET) scan if available, subsequent to which a margin of 5 mm was added to create the clinical target volume (CTV). We generated the planning target volume (PTV) by adding 10 mm to CTV margin in order to allow for daily set-up errors and respiratory motion of the liver. The organs at risk (OAR), including liver, kidneys, and spinal cord, were contoured and reconstructed to form a 3D representation. We designed the treatment plan as well as the field number and orientations with 3D view techniques and evaluated them using dose-volume histogram to cover the target volumes and minimize the dose delivered to OAR. A daily fraction of 3 Gy was administered to deliver a total dose of 51 Gy, which is equivalent to a BED of 66.3 Gy with α/β ratio = 10. Radiotherapy was delivered with a 6-10 MV linear accelerator.

Follow-up

Through physical examination, complete blood cell counts, and liver function tests, we evaluated

the patients on a weekly basis during radiotherapy. CT and/or PET/CT scan studies were performed initially prior to the treatment, 3-6 weeks after the end of radiotherapy, and every 3-6 months thereafter. The treatment response was evaluated using the Response Evaluation Criteria in Solid Tumors (RECIST)¹⁶ and the tumor was considered as locally controlled so far there has been no progression (in field), whereas progression was defined as an increase by $\geq 20\%$ in the diameter of the target tumor. Radiation-induced toxicity was graded via the Common Terminology Criteria for Adverse Events version 3.0.¹⁷

Statistical analysis

We carried out the analysis using SPSS software version 22 (<http://www.ibm.com>). The primary endpoint was local progression-free survival (LPFS), and the secondary endpoints were toxicity and overall survival (OS).

LPFS was defined as the time from the date of diagnosis to that of local tumor progression. The patients without local disease progression were censored at the last follow-up. OS was calculated based on the date of diagnosis to the date of death. LPFS and OS were estimated

utilizing the Kaplan-Meier product-limit method. The patients and tumor characteristics were studied to determine the effect of each variable on LPFS and OS. The age, GTV, and AFP were considered as continuous variables. We categorized the subjects into dichotomous groups according to gender (male versus female), Child-Pugh class (A versus B), and portal vein thrombosis (yes versus no). Multivariate analyses were performed to determine the importance of each variable in the presence of other variables. Cox proportional hazard regression model was used (enter method) to select the best predictor factor for each endpoint. $P \leq 0.05$ was considered to be significant.

Results

We assessed 61 patients with a median follow-up of 14 months (range: 2-42 months). Only four patients were female, the majority of patients (91.8%) had cirrhosis Child-Pugh class A. The median GTV was 52.8 (range 24.8-102.9 cm³). The tumor was localized in left lobe in about two-third of the patients. All the participants had hepatitis C virus, except for three, who had hepatitis B virus. 10 patients had portal vein

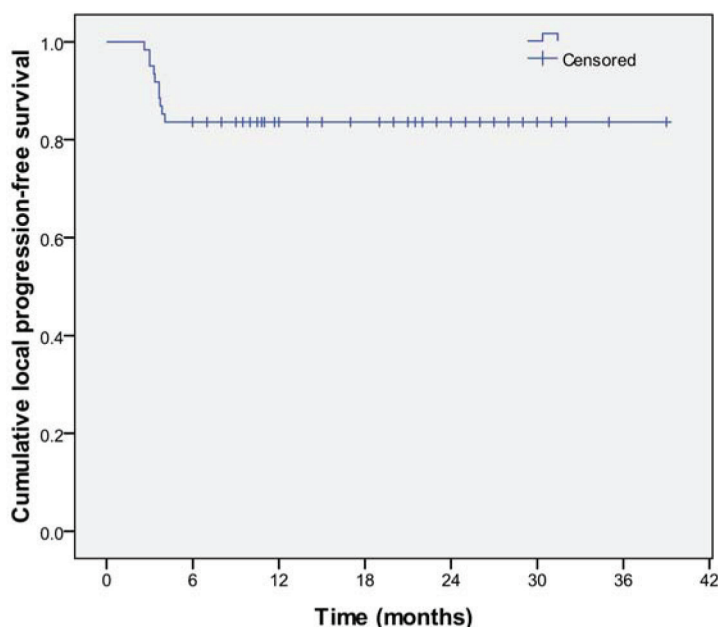


Figure 1. This figure shows the local progression-free survival rate of 61 patients with HCC, who were treated via 3D conformal radiotherapy.

HCC: Hepatocellular carcinoma

Table 1. Patient and tumor characteristics of 61 patients with HCC, who were treated via 3D conformal radiotherapy

Variables	No	(%)
Age (median)	56y	(range: 34-77)
GTV (median)	52.8	(range: 24.8-102.9 cm ³)
AFP(IU/mL) (median)	300	(range: 2.4 -83134)
Gender		
Male	57	(93.4)
Female	4	(6.6)
Child-Pugh class		
A	56	(91.8)
B	5	(8.2)
Lobe		
Right	20	(32.8)
Left	41	(67.2)
PVT		
No	51	83.6
Yes	10	16.4
Hepatitis virus type		
HCV	58	95.1
HBV	34.9	

GTV: Gross tumor volume; AFP: α -fetoprotein; PVT: Portal vein thrombosis; HCV: Hepatitis C virus; HBV: Hepatitis B virus; HCC: Hepatocellular carcinoma

thrombosis (Table 1). The objective response rate was 68.9%, including seven patients (11.5%) achieving complete response and 35 patients (57.4%) with partial response. In addition, nine cases (14.8%) had stable disease. Local tumor progression was observed in 10 patients (16.4%). The LPFS rate at 12 months was 83.6%, which was maintained to 36 months (Figure 1). At the time of the analysis, six patients were alive. The median OS was 17 months and the OS rate at years 1, 2, and 3 were 65.1%, 38.7%, and 26.4%, respectively (Figure 2). According to multivariate Cox regression model, GTV was the only prognostic factor for both LPFS ($P = 0.001$) and OS ($P = 0.000$) with patients presented with smaller tumor having significantly more favorable outcomes (Table 2).

Acute radiation-induced hepatic toxicity was observed as grade 1 in 23 patients (37.7%), grade 2 in seven patients (11.5%), and only one patient (1.6%) experienced grade 3. We observed no apparent late hepatic toxicity.

Discussion

HCC is a major global health issue as most of patients present in advanced stages due to non-specific symptoms.^{1,2} In addition, nearly all patients have underlying cirrhotic diseased liver,

which impairs the efficacy of the available anticancerous treatments (systemic chemotherapy and conventional external beam radiotherapy therapy). Finally, the whole liver is liable to develop de novo tumor lesions, as the liver is diffusely affected by cirrhosis. 3D conformal radiotherapy (3D-CRT) is a non-invasive well-tolerated treatment modality, which is highly suitable for patients with small HCCs in cirrhotic liver, who deny other local ablative therapies.^{5,10,11}

Since there is accumulating evidence suggesting a dose-response relationship in the irradiation of HCC, we tried to escalate the dose without increasing the overall treatment time and fractionations in this study.^{13,15,18} Hence, a hypofractionated short course treatment with a total dose of 51 Gy was delivered in 17 fractions. This schedule is translated to a BED of 66.3 Gy with the α/β ratio = 10, which could be considered as a radical dose.

It is difficult to compare the outcomes of radiotherapy in HCC patients between publications on account of the differences concerning treatment regimens, doses, fractionation schemes, radiotherapy techniques, and endpoint definitions, in addition to heterogeneous patient populations. In the present study, the objective response rate was 68.9%. Our data are consistent with those

reported by Huang et al.¹⁸ who evaluated 40 patients with HCC. They were treated via hypofractionated radiotherapy with a fraction size of 3 Gy and a total dose of 40-66 Gy in 14-23 fractions. The authors reported an objective response rate of 70.0%. Similar to our results, Park et al.¹⁵ evaluated 59 patients treated with localized radiotherapy with a curative intent. They found that 66.1% of the subjects achieved an objective tumor response, with complete response in 8.5% patients and partial response in 57.6% patients. Oh et al.,¹⁹ in a prospective study, also reported an objective response of 62.8% in 40 patients with unresectable HCC treated via hypofractionated 3D-CRT. Comparable to our results, Seong et al.¹³ documented that the response rate was 67.1% in 158 patients with unresectable HCC treated with radiotherapy. Liu et al.²⁰ reported an objective response of 61.4% in 44 patients with unresectable HCC, who underwent 3D-CRT.

On the contrary to our findings, Liang et al.²¹ reported that the response rate for hypofractionated

3D-CRT in HCC was 55%, which is inferior to our results. Additionally, Seo et al.²² evaluated the efficacy of radiotherapy in 65 patients with unresectable HCC and stated that the objective response was 56.9%. Kim et al.¹² evaluated 3D-CRT in 70 unresectable HCC patients and found a response rate of 54.3%. This may be due to the larger tumor size and lower total dose received in these three studies compared with those in our work.

In the current research, the LPFS rate at 12 months was 83.6%. This is consistent with Bae et al.²³ who reported that in-field local control was achieved in 85% of 20 patients with recurrent small HCC treated with hypofractionated radiotherapy after the failure of previous treatment. In another report, Park et al.¹⁵ showed that the in-field failure rate was 16.9% for patients treated with doses >50 Gy, and concluded that a BED of 50 Gy was a criterion for an effective radiation dose.

Our results demonstrated that the OS rate at years 1, 2, and 3 were 65.1%, 38.7%, and 26.4%,

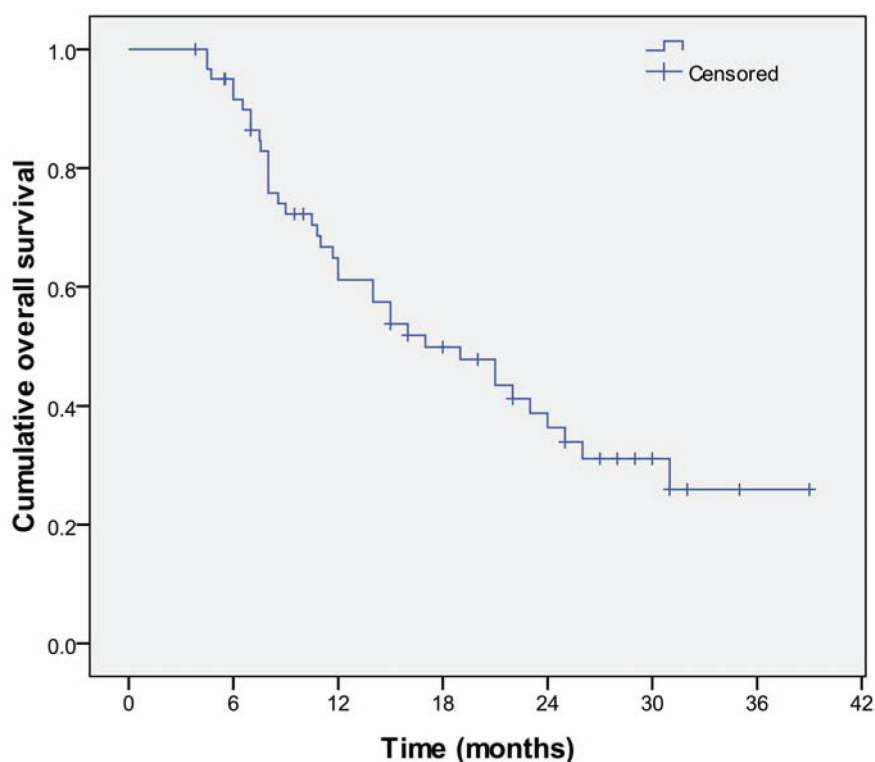


Figure 2. This figure shows the overall survival rate of 61 patients with HCC, who were treated via 3D conformal radiotherapy. HCC: Hepatocellular carcinoma

Table 2. Multivariate analysis of the local progression-free survival and overall survival of 61 patients with HCC, who were treated via 3D conformal radiotherapy

Variables	Local progression-free survival			Overall survival		
	P-Value	OR	95% CI for OR	P-Value	OR	95% CI for OR
Age	0.512	0.975	0.905 - 1.051	0.747	0.993	0.950 - 1.038
GTV	0.001	1.059	1.022 - 1.096	0.000	1.047	1.028 - 1.067
AFP	0.821	1.000	0.999 - 1.001	0.403	1.000	1.000 - 1.000
PVT	0.772	0.731	0.088 - 6.085	0.390	1.539	0.576 - 4.112

OR: Odds ratio; GTV: Gross tumor volume; AFP: α -fetoprotein; PVT: Portal vein thrombosis; HCC: Hepatocellular carcinoma; CI: Confidence interval

respectively. In line with our findings, Liu et al.²⁰ stated that the survival rates at years 1, 2, and 3 were respectively 60.5%, 40.3%, and 32.0% in 44 patients with unresectable HCC, who underwent 3D-CRT. Similarly, Liang et al.²¹ presented a report about hypofractionated 3D-CRT for HCC and found the OS rates at years 1, 2, and 3 to be 65%, 43%, and 33%, respectively. In another study by Huang et al.,¹⁸ they reported that the 1- and 2-year OS rates in 40 patients with HCC treated via hypofractionated radiotherapy were 60% and 40%, respectively.

As expected, in the present study, GTV was found to be a prognostic factor for OS in multivariate analysis. Similarly, Liang et al.²¹ reported that the GTV was identified through Cox regression analysis as independent predictors for survival in HCC, who underwent hypofractionated 3D-CRT. Moreover, Seong et al.¹³ analyzed the treatment results in 158 patients with unresectable HCC, who received local radiotherapy, and reported that tumor size was a significant factor associated with survival.

Herein, radiotherapy was tolerable with only one patient experiencing grade 3 radiation-induced liver toxicity. In accordance with our study, Li et al.²⁴ reported that radiotherapy was well-tolerated; severe adverse effects were only observed in two patients who presented with deterioration of liver function. Oh et al.¹⁹ prospectively evaluated the toxicity of 3D-CRT in 40 patients with unresectable HCC and found no grade 3 or greater acute toxicity. Bae et al.²³ observed no grade 3 or greater treatment-related toxicities in 20 patients with recurrent small HCC treated with hypofractionated radiotherapy. Park et al.¹⁵ evaluated 59 patients who were treated with localized radiotherapy with a curative intent, and found no

grade 3 or 4 acute toxicity.

The current study was a single-arm study with a small sample size. However, our research included patients with HCC, who received homogenous 3D-CRT protocols at a single institution. Furthermore, to the best of our knowledge, this is the first prospective study of 3D-CRT dose escalation for HCC in Egyptian population. The current investigation adds to the growing evidence on the efficiency and tolerability of radiotherapy. Moreover, hypofractionated schedules have the advantage of being more convenient for the patient and helping to save medical resources. Therefore, well-designed large prospective randomized studies are warranted.

Conclusion

In conclusion, radical dose 3D conformal hypofractionated radiotherapy for HCC could be effective with satisfactory high rates of tumor control, OS, and acceptable treatment-related toxicity. This study presented an alternative convenient therapy for those with small tumor size, who deny other local therapies or where stereotactic body radiotherapy is unavailable.

Conflict of Interest

None declared.

References

1. Global Burden of Disease Liver Cancer Collaboration, Akinyemiju T, Abera S, Ahmed M, Alam N, Alemayohu MA, et al. The burden of primary liver cancer and underlying etiologies from 1990 to 2015 at the global, regional, and national level: Results from the global burden of disease study 2015. *JAMA Oncol.* 2017;3(12):1683-91. doi: 10.1001/jamaoncol.2017.3055.
2. Forner A, Reig M, Bruix J. Hepatocellular carcinoma.

- Lancet*. 2018;391(10127):1301-14. doi: 10.1016/S0140-6736(18)30010-2.
3. Ibrahim AS, Khaled HM, Mikhail NN, Baraka H, Kamel H. Cancer incidence in Egypt: results of the national population-based cancer registry program. *J Cancer Epidemiol*. 2014;2014:437971. doi: 10.1155/2014/437971.
 4. Abd-Elsalam S, Elwan N, Soliman H, Ziada D, Elkhalawany W, Salama M, et al. Epidemiology of liver cancer in Nile delta over a decade: A single-center study. *South Asian J Cancer*. 2018;7(1):24-6. doi: 10.4103/sajc.sajc_82_17.
 5. Lau WY, Lai ECH. Hepatocellular carcinoma: current management and recent advances. *Hepatobiliary Pancreat Dis Int*. 2008;7(3):237-57.
 6. Yamamoto J, Kosuge T, Saiura A, Sakamoto Y, Shimada K, Sano T, et al. Effectiveness of hepatic resection for early-stage hepatocellular carcinoma in cirrhotic patients: subgroup analysis according to Milan criteria. *Jpn J Clin Oncol*. 2007;37(4):287-95. doi: 10.1093/jjco/hym025.
 7. Yamamoto M, Takasaki K, Otsubo T, Katsuragawa H, Katagiri S, Yoshitoshi K, et al. Favorable surgical outcomes in patients with early hepatocellular carcinoma. *Ann Surg*. 2004;239(3):395-9. doi:10.1097/01.sla.0000114215.03112.e0.
 8. Mazzaferro V, Regalia E, Doci R, Andreola S, Pulvirenti A, Bozzetti F, et al. Liver transplantation for the treatment of small hepatocellular carcinomas in patients with cirrhosis. *N Engl J Med*. 1996;334(11):693-9. doi: 10.1056/NEJM.1996.03.14.3341104.
 9. Lau WY, Leung TW, Yu SC, Ho SK. Percutaneous local ablative therapy for hepatocellular carcinoma: a review and look into the future. *Ann Surg*. 2003;237(2):171-9. doi: 10.1097/01.SLA.0000048443.71734.BF.
 10. Rim CH, Seong J. Application of radiotherapy for hepatocellular carcinoma in current clinical practice guidelines. *Radiat Oncol J*. 2016;34(3):160-7. doi: 10.3857/roj.2016.01970.
 11. Hawkins MA, Dawson LA. Radiation therapy for hepatocellular carcinoma from palliation to cure. *Cancer*. 2006;106(8):1653-61. doi: 10.1002/cncr.21811.
 12. Kim TH, Kim DY, Park JW, Kim YI, Kim SH, Park HS, et al. Three-dimensional conformal radiotherapy of unresectable hepatocellular carcinoma patients for whom transcatheter arterial chemoembolization was ineffective or unsuitable. *Am J Clin Oncol*. 2006;29(6):568-75. doi: 10.1097/01.coc.0000239147.60196.11.
 13. Seong J, Park HC, Han KH, Chon CY. Clinical results and prognostic factors in radiotherapy for unresectable hepatocellular carcinoma: a retrospective study of 158 patients. *Int J Radiat Oncol Biol Phys*. 2003;55(2):329-36. doi: 10.1016/s0360-3016(02)03929-9.
 14. Mornex F, Girard N, Beziat C, Kubas A, Khodri M, Trepo C, et al. Feasibility and efficacy of high-dose three-dimensional-conformal radiotherapy in cirrhotic patients with small-size hepatocellular carcinoma non-eligible for curative therapies: mature results of the French Phase II RTF-1 trial. *Int J Radiat Oncol Biol Phys*. 2006;66(4):1152-8. doi: 10.1016/j.ijrobp.2006.06.015.
 15. Park W, Lim DH, Paik SW, Koh KC, Choi MS, Park CK, et al. Local radiotherapy for patients with unresectable hepatocellular carcinoma. *Int J Radiat Oncol Biol Phys*. 2005;61(4):1143-50. doi: 10.1016/j.ijrobp.2004.08.028.
 16. Eisenhauer EA, Therasse P, Bogaerts J, Schwartz LH, Sargent D, Ford R, et al. New response evaluation criteria in solid tumours: revised RECIST guideline (version 1.1). *Eur J Cancer*. 2009;45(2):228-47. doi: 10.1016/j.ejca.2008.10.026.
 17. Trotti A, Colevas AD, Setser A, Rusch V, Jaques D, Budach V, et al. CTCAE v3.0: Development of a comprehensive grading system for the adverse effects of cancer treatment. *Semin Radiat Oncol*. 2003;13(3):176-81. doi: 10.1016/S1053-4296(03)00031-6.
 18. Huang BS, Tsang NM, Lin SM, Lin DY, Lien JM, Lin CC, et al. High-dose hypofractionated X-ray radiotherapy for hepatocellular carcinoma: tumor responses and toxicities. *Oncol Lett*. 2013;6(5):1514-20. doi: 10.3892/ol.2013.1582.
 19. Oh D, Lim do H, Park HC, Paik SW, Koh KC, Lee JH, et al. Early three-dimensional conformal radiotherapy for patients with unresectable hepatocellular carcinoma after incomplete transcatheter arterial chemoembolization: a prospective evaluation of efficacy and toxicity. *Am J Clin Oncol*. 2010;33(4):370-5. doi: 10.1097/COC.0b013e3181b0c298.
 20. Liu MT, Li SH, Chu TC, Hsieh CY, Wang AY, Chang TH, et al. Three-dimensional conformal radiation therapy for unresectable hepatocellular carcinoma patients who had failed with or were unsuited for transcatheter arterial chemoembolization. *Jpn J Clin Oncol*. 2004;34(9):532-9. doi: 10.1093/jjco/hyh089.
 21. Liang SX, Zhu XD, Lu HJ, Pan CY, Li FX, Huang QF, et al. Hypofractionated three-dimensional conformal radiation therapy for primary liver carcinoma. *Cancer*. 2005;103(10):2181-8. doi: 10.1002/cncr.21012.
 22. Seo YS, Kim JN, Keum B, Park S, Kwon YD, Kim YS, et al. Radiotherapy for 65 patients with advanced unresectable hepatocellular carcinoma. *World J Gastroenterol*. 2008;14(15):2394-400. doi: 10.3748/wjg.14.2394.
 23. Bae SH, Park HC, Lim DH, Lee JA, Gwak GY, Choi MS, et al. Salvage treatment with hypofractionated radiotherapy in patients with recurrent small hepato-

- cellularcarcinoma. *Int J Radiat Oncol Biol Phys*. 2012; 82(4):e603-7. doi: 10.1016/j.ijrobp.2011.09.053.
24. Li N, Feng S, Xue J, Wei XB, Shi J, Guo WX, et al. Hepatocellular carcinoma with main portal vein tumor thrombus: a comparative study comparing hepatectomy with or without neoadjuvant radiotherapy. *HPB (Oxford)*. 2016;18(6):549-56. doi: 10.1016/j.hpb.2016.04.003.