

Large Phyllodes Tumor: A Case Report

Sedigheh Tahmasebi*, Majid Akrami*, Sam Moslemi***, Maryam Tahamtan***, Mohammad Hasan Hashemizadeh**

*Department of Surgical Oncology, Faghihi Hospital, Shiraz, Iran

**General Surgery Department, Shiraz University of Medical Sciences, Shiraz, Iran

***Department of Internal Medicine, Nemazee Teaching Hospital, Shiraz, Iran

Abstract

Phyllodes tumors account for less than 1% of breast tumors in women. Giant phyllodes tumors are larger than 10 cm in diameter. A 40-year-old lady presented with a left breast lump that was present for two years. She underwent a simple mastectomy. The tumor was 30×26×21 cm in size, weighed 15 kg and had a density of 0.915 gr/cm³. We believe this patient had the third largest breast phyllodes tumor according to size, the second largest according to weight and had the highest density among all cases thus reported in English-language publications.

Keywords: Phyllodes tumor, Breast, Simple mastectomy

Introduction

The phyllodes tumor, first described by Johannes Muller in 1838 has presented a diagnostic and treatment dilemma for physicians since its original description. Classically, the name cystosarcoma phyllodes was assigned because of the tumor's fleshy appearance and tendency to contain macroscopic cysts. The term, however, is a misnomer as these tumors are usually benign. Phyllodes tumor is the currently accepted nomenclature according to the World Health Organization (WHO).

Phyllodes tumors are rare fibroepithelial tumors that account for about 0.4% of all female breast tumors.

Clinically it resembles a fibroadenoma and can be mistakenly left alone. Giant phyllodes tumors are those larger than 10 cm and account for about 20% of all phyllodes tumors.

Routinely, patients present with a firm, circular, mobile, well-defined and painless mass without any significant pathognomonic mammographic or ultrasound features.

Therefore, early diagnosis of the phyllodes tumor is extremely difficult. A variety of techniques, including color Doppler ultrasound, magnetic resonance imaging (MRI), fine needle aspiration (FNA), and core tissue biopsy have been utilized

Corresponding Author:

Sam Moslemi, MD
General Surgery Department,
Shiraz University of Medical
Sciences, Shiraz, Iran
Tel: +98-9370928760
Email: moslemis@sums.ac.ir

to improve the pre-operative diagnosis.²⁻⁴ Phyllodes tumors are sharply demarcated from surrounding tissue which is compressed and distorted. Connective tissue composes of the bulk of these tumors which have mixed gelatinous, solid and cystic areas. Most malignant phyllodes tumors contain liposarcomatous/rhabdomyosarcomatous elements rather than a fibrosarcomatous component. Evaluation of the numbers of mitosis may help in diagnosis of a malignant tumor.⁵ Approximately 20% of phyllodes tumors may be considered as giant as or greater than 10 cm in maximum diameter.⁶

Case Report

A 40-year-old lady with a lump in her left breast that progressed in size during the past two years was seen in the Surgical Oncology Group for further evaluation and management. The patient referred to the Breast Cancer Clinic, where on physical examination, it was observed that the left breast was significantly greater in size than the right breast. She had a giant left breast with red discoloration. No lymphadenopathy was detected. The patient underwent an FNA which showed a phyllodes tumor. She had no family history of breast or ovarian malignancy and no history of radiation. The patient underwent surgical management. Because of good breast peduncle and no significant lymph nodes, a simple mastectomy was performed with primary closure

of the skin, with no need for any skin graft or latissimus dorsi pedicle flap reconstruction (Figures 1-4). She had an uneventful post-operative course and was discharged. Pathologic evaluation of the specimen revealed a 30×26×21 cm mass that weighed 15kg. Histological examination showed biphasic tumoral growth that was composed of two components, a bland epithelial part that formed glandular structures and hypercellular stroma. Stromal cells were round-to-oval cells that showed moderate degree of pleomorphism and a high mitotic index (approximately 10/10 HPF). Stromal overgrowth was also evident (Figures 5-6). The diagnosis based on histological examination was malignant phyllodes tumor. At the six months follow up there were no significant subjective or objective problems.

Discussion

The phyllodes tumor, firstly described by Johannes Muller in 1838 has presented a diagnostic and treatment dilemma for physicians since its original description.

Classically, the name cystosarcoma phyllodes was assigned because of the tumor's fleshy appearance and tendency to contain macroscopic cysts. The term, however, is a misnomer as these tumors are usually benign. Phyllodes tumor is the currently accepted nomenclature according to the World Health Organization (WHO).¹

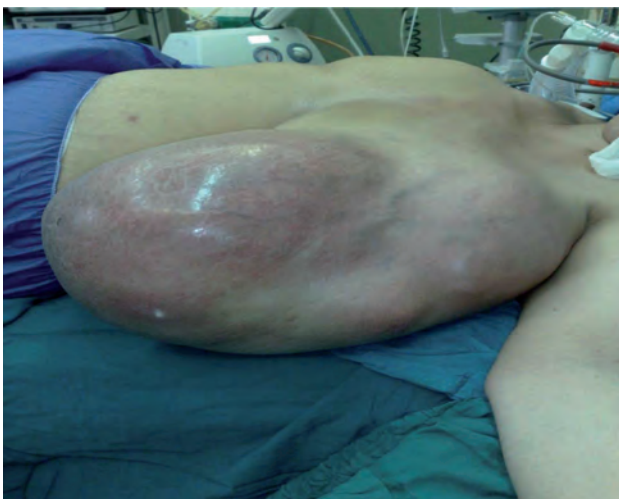

Figure 1. Left breast appearance before operation.

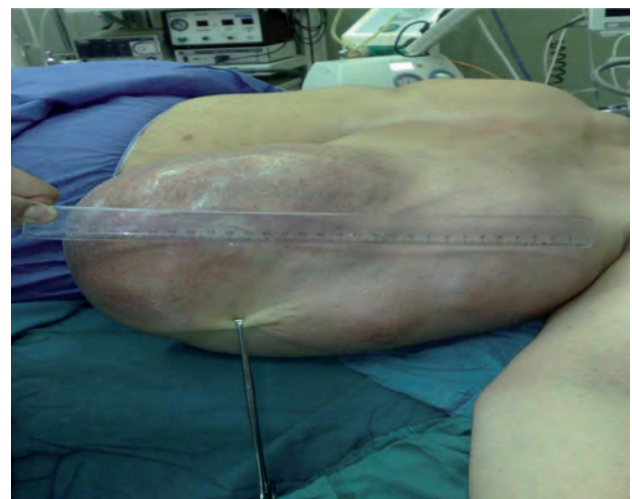

Figure 2. Measurement of breast length.

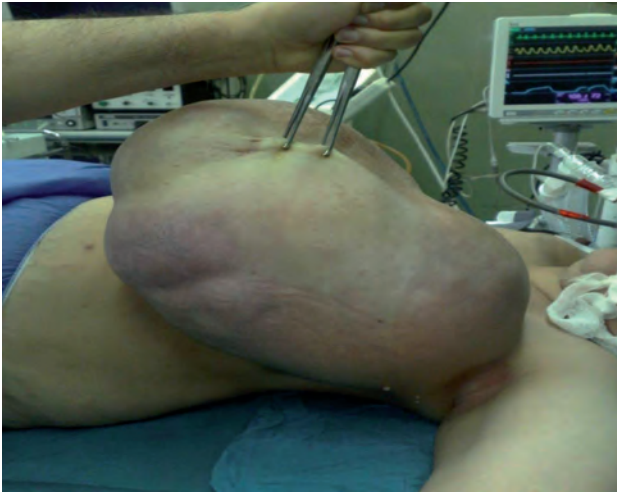

Figure 3. Left Breast appearance.

Although surgery is the treatment of choice for phyllodes tumors of the breast, the best type of surgery for benign or borderline tumors is debatable (wide local excision or total mastectomy). However for tumors of similar size as the current patient, we recommend a total mastectomy to ensure complete removal of the tumor and an immediate or delayed breast reconstruction to provide an added psychological benefit.

We believe this case has one of the largest phyllodes tumor of the breast with the highest density. Kumar et al. have stated that their patient had the largest phyllodes breast tumor at 50×25.2×16.4 cm, 15 kg in weight and a density of 0.726 gr/cm³.⁷ Xia et al. presented their case as a

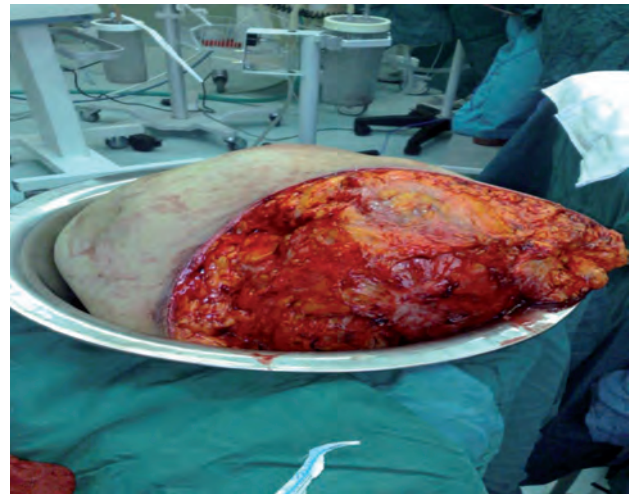


Figure 4. The specimen.

giant phyllodes tumor of the breast which measured 47.5×37.0×28.0 cm and weighed 9.79 kg ex-vivo with 0.199 gr/cm³ in density.⁸ In addition, Sarvanandan et al. presented their case 28×25×18 cm in size, 8.27 kg with a density of 656 gr/cm³.⁹ These are the largest phyllodes tumors in all cases reported in English language publications, thus far. According to these cases, our case was the third case in size, the second one in weight (equal to the first case) and had the highest density (0.915 gr/cm³) according to size and weight.

The usual surgical technique includes simple mastectomy or modified radical mastectomy according to the pathologic report and lymph node evaluation.⁷⁻⁹ In addition, in most cases the

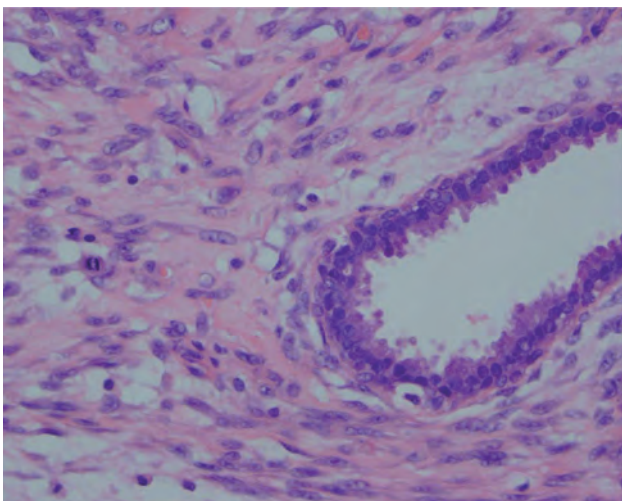


Figure 5. Biphasic tumor showing bland-looking glandular structures and hypercellular stroma. Pleomorphism and mitotic figures are evident in the stroma. (H&E, 400×)

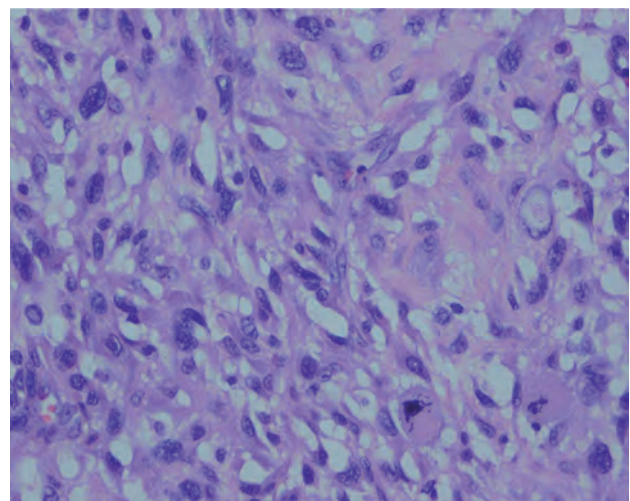


Figure 6. stroma shows round to oval cells with pleomorphism and scattered bizarre cells. (H&E, ×400)

latissimus dorsi pedicle flap is reconstructed because of skin loss and inability to obtain a primary closure,⁷⁻⁹ however in this case, the patient had a primary closure due to the pedunculated breast and simple mastectomy as the surgical technique.

Conclusion

Giant phyllodes tumors are rare. Mastectomy is preferred for complete tumor excision. In recent years, there has been an increased incidence of large phyllodes tumor which maybe attributed to low patient disease compliance or better medical reporting. Surgical management of large phyllodes tumor includes simple mastectomy or modified radical mastectomy according to the pathologic report and surgical evaluation. We believe no additional treatment modality is necessary for definite diagnosis of breast phyllodes tumors.

References

1. Liang MI, Ramaswami B, Patterson CC, McKelvey MT, Gordillo G, Nuova GJ, et al. Giant breast tumors: Surgical management of phyllodes tumors, potential for reconstructive surgery and a review of literature. *World J Surg Oncol* 2008;6:117.
2. Chao TC, Lo YF, Chen SC, Chen MF. Sonographic features of phyllodes tumors of the breast. *Ultrasound Obstet Gynecol* 2002;20:64-71.
3. Kinoshita T, Fukutomi T, Kubochi K. Magnetic resonance imaging of benign phyllodes tumors of the breast. *Breast J* 2004;10:232-6.
4. Veneti S, Manek S. Benign phyllodes tumour vs fibroadenoma: FNA cytological differentiation. *Cytopathology* 2001;12:321-8.
5. Khan SA, Badve S. Phyllodes tumors of breast. *Curr Treat Options Oncol* 2001; 2:139-47.
6. Tan PH, Jayabaskar T, Chuah KL, Lee HY, Tan Y, Hilmy M, et al. Phyllodes tumors of the breast: The role of pathologic parameters. *Am J Clin Pathol* 2005;123:529-40.
7. Kumar T, Patel MD, Bhargavan R, Kumar P, Patel MH, Kothari K, et al. Largest phyllodes tumor- case report and brief review article. *Indian J Surg Oncol* 2011;2(2):141-4.
8. Dong Xia, Huaiquan Zuo, Yi Quan, Hongliang Dong, Liang Xu. Giant phyllodes tumor of the breast: A case report. *Chinese-German Journal of Clinical Oncology* 2010; 9(11):674-6.
9. Sarvanandan R, Thangaratnam R, Leong AC. Immediate latissimus dorsi pedicle flap reconstruction following the removal of an eight kilogram giant phyllodes tumour of the breast: A case report. *J Med Case Rep* 2011;5:44.