

The Clinical Value of Axillary Ultrasonography for Detection of Axillary Lymph Node Metastasis in Cases with Breast Cancer

Sedigheh Tahmasebi*, Behnam Dalfardi**, Majid Akrami*, Arash Talei*, Abdolrasoul Talei*, Alireza Rasekhi***

*Department of Surgery, Shiraz University of Medical Sciences, Shiraz, Iran

**Student Research Committee, Shiraz University of Medical Sciences, Shiraz, Iran

***Department of Radiology, Shiraz University of Medical Sciences, Shiraz, Iran

Abstract

Background: The axillary lymph node stage is one of the single most important determinants in the prognosis of breast cancer patients. The disadvantages of the two previous methods used for evaluating axillary node metastasis, i.e., axillary lymph node dissection and sentinel lymph node biopsy, have directed researchers to investigate new techniques for this purpose. The aim of the current study was to evaluate the clinical usefulness of axillary ultrasonography in detecting axillary metastasis.

Methods: This study was conducted during a 12-month period. The breast cancer cases included in this study were all clinically diagnosed as stages I and II, with no prior treatment to the axillary region by surgery and/or chemo-radiotherapy. Excluded from the study group were patients with palpable axillary lymph nodes, those who had major organ failure or concomitant malignancy. All included patients with non-palpable axillary lymph nodes underwent axillary ultrasound examination. An ultrasound-guided core needle biopsy was performed on patients with suspected metastasis.

Results: There were 125 female patients with a mean age of 49.6 years included in this study. From these, 16 (12.8%) cases had positive axillary sonographic findings. Pathologic evaluation of tissue specimens (taken by ultrasound-guided core needle biopsy) in 10 (62.5%) out of 16 patients were positive, and in the patient group of 6 (37.5%) cases, studies were negative. Axillary ultrasonography had a sensitivity of 35.7%, specificity of 93.8%, positive predictive value of 62.5%, and negative predictive value of 83.5%.

Conclusion: The axillary ultrasonogram is a reliable technique in the determination of axillary nodal metastatic involvement in breast cancer patients. By use of this method a significant amount of complications and costs related to the previous techniques can be avoided.

Keywords: Axilla, Biopsy, Breast neoplasms, Lymph nodes, Neoplasm metastasis, Ultrasonography

♦Corresponding Author:

Behnam Dalfardi, MD
Student Research Committee,
Shiraz University of Medical
Sciences, Shiraz, Iran
Tel: +98-913-2483359
Fax: +98-711-2122970
Email: Dalfardibeh@gmail.com

Introduction

Breast malignancies are the second most common cause of cancer-related mortality among women.¹ The status of axillary lymph node metastasis, in addition to being the most important prognostic factor in this group of patients, has a critical place in the management of this disease.^{2,3}

For many years, axillary lymph node dissection (ALND) was the choice of method for axillary nodal evaluation which reliably staged and effectively treated metastatic lymph node involvement. However, for those cases that had no nodal involvement ALND gave no advantage and sometimes was associated with significant complications such as lymphedema, wound infections, stiffness, shoulder weakness, pain and numbness of the affected arm.⁴⁻⁷

Afterwards, the concept of sentinel lymph node biopsy (SLNB) was developed. This method has been shown to be a valuable tool in

determining whether the cancer has spread from its original site and for axillary staging. It has proven to be an effective alternative to ALND. Those patients whose SLNB is disease-free require no further treatment and are spared from unnecessary axillary surgery.^{8,9} Despite its wide acceptance for practice, SLNB has some drawbacks; it is a slow and meticulous process for surgeons in the operating room, requires the administration of radioisotopes to patients, and needs multiple microscopic sections for final histological examination.⁹⁻¹²

Currently, the selection of breast cancer patients who should undergo the SLNB procedure is based on a negative axillary clinical examination. However, the sensitivity of such clinical examination remains at only 15%-60%. In fact, a large number of patients with non-palpable axillary lymph nodes have metastatic involvement.^{13,14}

An ultrasound (US) examination has been

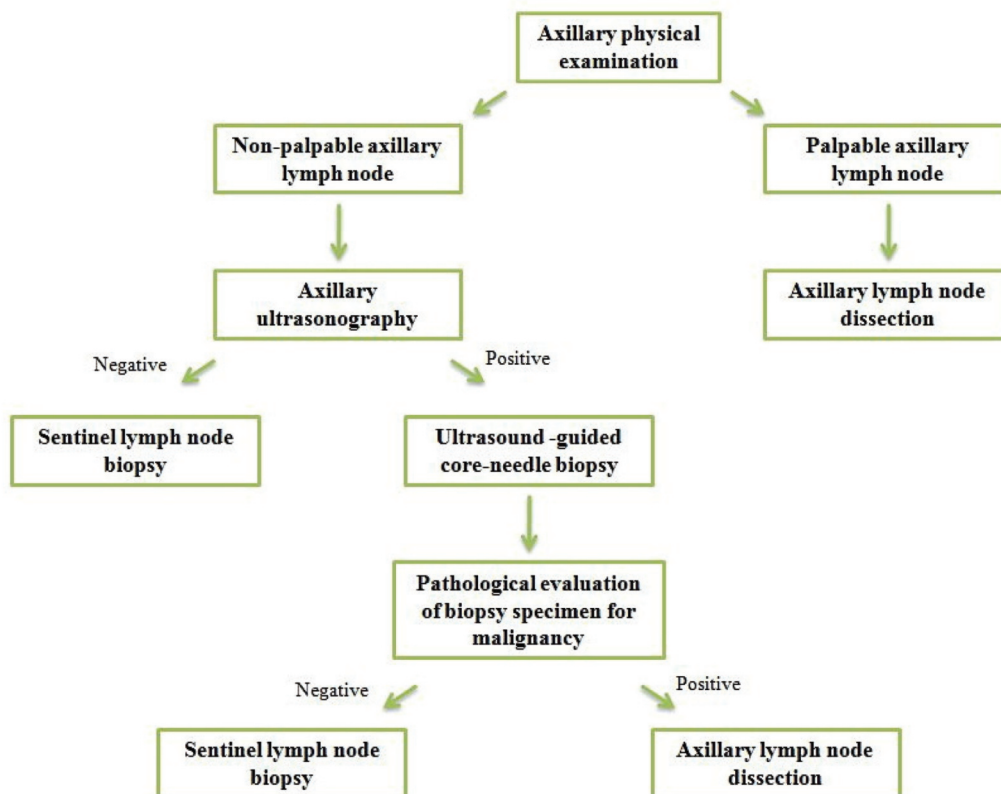


Figure 1. The current study protocol for evaluating clinical usefulness of axillary ultrasonography in diagnosing the metastatic status of axillary nodes.

Table 1. Sonographic criteria for the detection of lymph nodes with metastatic involvement.

- Cortical thickening (more than one-half of the lymph node thickness, in short axis)
- Absence of hilum
- Increased hilar or central cortical blood flow, or non-hilar cortical blood flow (assessed by color-doppler ultrasonography)

recommended by previous studies to detect suspicious involved axillary lymph nodes.¹³ In this respect, US-guided fine needle aspiration (FNA) is a suggested technique for axillary lymph node staging.^{2,3,15} However, US-guided FNA is not as sensitive as SLNB and its false-negative rate is too high to entirely replace SLNB. Patients with negative findings at US-guided FNA will still need to undergo SLNB for evaluation of the axilla.³ Additionally, FNA is more operator dependent compared with other methods such as the core-needle biopsy (CNB).¹⁶ The reported rate of insufficient cytological material following US-guided FNA is 0%-54%.¹⁷

Until now, the findings of ALND or its alternative method, SLNB, have been used as the gold standard for axillary staging in breast cancer cases that have clinically negative axilla. However, if nodal positivity can be proven pre-operatively, it helps diagnosing one-stage axillary clearance and SLNB can be avoided. In addition, it may also have an impact on the decisions to offer neo-adjuvant therapy and breast reconstruction.^{2,12,15-17} Therefore, it is helpful for both the patient and surgeon to establish a simple pre-operative method in patients with metastatic lymph nodes who could directly undergo an axillary dissection and eliminate the need to search for the sentinel lymph node. The aim of this study is to evaluate the clinical usefulness of axillary ultrasonogram in diagnosing axillary nodal metastasis in cases with breast cancer.

Materials and Methods

This research was designed in the form of a cross-sectional study conducted during a 12-month period (November 2010 to November 2011). It was performed at Shahid Faghihi Hospital in Shiraz, a tertiary health-care center affiliated with Shiraz University of Medical Sciences, Shiraz, Iran. The study protocol was

approved by both the Institutional Review Board (IRB) and the Ethics Committee of Shiraz University of Medical Sciences, and all participants gave their written informed consent.

In this survey, all patients clinically diagnosed with stages I and II breast cancer were included in the study group. Cases with previous history of axillary region surgery, and/or history of chemo-radiotherapy of the axilla, and those who had palpable axillary lymph nodes at physical examination were excluded from the study. Also excluded were patients with major organ failure such as cirrhosis of the liver, heart failure, etc., and/or documented concomitant malignancy of any site (other than the breast).

The attending physician (surgeon-oncologist) obtained a complete, comprehensive medical history and performed a physical examination on each patient with particular attention to assessment of any palpable axillary lymph nodes. Patients with palpable axillary lymph nodes were excluded from the study and referred for ALND; those patients with no palpable nodes underwent axillary ultrasonography, which was performed by the attending radiologist (Table 1). Patients who had a negative axillary sonographic examination were referred for pre-operative sentinel lymph node mapping (by the use of methylene blue and scintigraphy) and biopsy. Those, cases with positive sonographic findings became candidates for further evaluation by way of a core needle biopsy of suspicious lymph nodes. Core needle biopsy specimens were sent for pathological evaluation. Finally, cases with negative pathologic findings underwent sentinel lymph node mapping and biopsy and patients diagnosed with a positive pathologic finding for malignancy were referred for an ALND procedure (Figure 1).

All sonographies were performed in real-time with use of the 7.5 MHz Sono line G50 Ultrasound System (Siemens, Germany). All core needle

biopsies were accomplished and performed using a 14-gauge biopsy needle (Cardinal Health, Dublin, OH, USA). The data was analyzed using SPSS Analytic Software, version 16.0 (SPSS, Inc., Chicago, IL, USA).

Results

There were 125 female patients enrolled in the study. Patients had clinically confirmed stages I and II breast cancer. The mean±SD age of the study population was 49.6±10.4 years (range: 25-79 years). From the total number of the patients, 16 (12.8%) cases were diagnosed positive for metastasis by their axillary sonogram. Sonographic assessment was negative in the remaining 109 (87.2%) patients.

Pathological evaluation of the tissue specimens obtained by US-guided CNB was performed. The findings detected that 10 (62.5%) out of 16 patients with significant axillary sonographic examination were positive for metastatic lesions and the remaining group of 6 (37.5%) cases tested negative for metastasis. Sentinel lymph node mapping and biopsy were performed for 109 (87.2%) patients who had negative sonography results of the axilla and 6 cases that had negative pathologic findings. From among these aforementioned cases, all 10 patients with positive pathology reports had positive ALND results; sentinel lymph node mapping and biopsy was negative in 4 of the 6 patients with negative pathological findings. No important complications related to the CNB were reported.

Axillary ultrasonography for the detection of metastasis to the axillary lymph nodes showed a sensitivity of 35.7%, specificity of 93.8% and an accuracy of 87.5%. Furthermore, 10 out of 16 patients with sonographic findings positive for axillary metastasis had positive pathological findings; therefore, the positive predictive value of the axillary ultrasonogram was 62.5%. The 91 out of 109 cases with negative sonograms of the axilla also had no significant pathologic findings which resulted in a negative predictive value of 83.5% for axillary ultrasonography. Data is summarized in Table 2.

Table 2. Ultrasonography characteristics for the detection of metastasis to axillary lymph nodes.

Characteristics	Value (%)
Sensitivity	35.7
Specificity	93.8
Accuracy	87.5
Positive predictive value	62.5
Negative predictive value	83.5

Discussion

Axillary nodal staging has a key role in the prognosis of patients with breast cancer.^{2,3} Thus, knowing a simple and reliable study technique for determination of this nodal status could be of significant value for both the surgeon and the patient.⁷

State-of-the-art technology is presently being used to evaluate the axillary nodal status, such as a variety of imaging modalities that include ultrasonograms, magnetic resonance imaging and nuclear studies.¹⁸ Among these techniques, the ultrasonogram because of its wide availability, non-invasive nature and high-quality imaging remains a leading diagnostic tool for axillary assessment.^{5,18} However, a drawback of the US is its failure in the accurate detection of malignant deposits in lymph nodes which could appear to be morphologically normal. To prevent this error, histopathological studies are performed in addition to the US.³

In the past, a few studies were carried out to support the role of the US-guided CNB in the evaluation of axillary nodal metastasis in breast cancer patients. Topal et al. evaluated a series of 39 patients and reported that the US-guided CNB had a sensitivity of 90%, specificity of 100% and accuracy of 92%, as well as positive and negative predictive values of 100% and 66%, respectively. They concluded that the US-guided CNB was a trustworthy, easily conducted technique for the assessment of axillary lymph node metastasis.¹⁸ Another study by Britton et al. included a total number of 139 breast cancer patients. Of these, 121 cases underwent US-guided CNB of the axillary node. In that survey, the overall reported sensitivity of CNB in detection of lymph node

metastases was 53.4%.⁵ The results of our survey were consistent with those of these two aforementioned studies that assessed and established the US-guided CNB as a reliable diagnostic tool for evaluation of axillary node metastasis.

A number of previous studies defend and consider the diagnostic role of US-guided FNA for the axillary staging in breast cancer as an excellent tool.^{2,3,7,13,15} Although a negative US-guided CNB (similar to that of US-guided FNA) does not preclude the need for SLNB, the benefit in comparison with that of the US-guided FNA is its applicability in situations in which adequate cytology equipment and experienced cytopathologists are not available.¹⁹

There were some limitations to our study, in particular the limited number of assessed cases. We extended the study time to 12 months to acquire additional cases for the study and reduce the impact of this factor. Additionally, the US-guided CNB might lead to false-negative diagnoses in cases with small metastatic deposits. Sonography is an operator dependent technique; hence to eliminate this factor, we have used an expert radiologist in this study.

Conclusion

The results of this study, in accordance with the previous findings in the literature, support and promote the practical value of the US-guided CNB for the analysis and evaluation of axillary node metastasis in breast cancer patients. By application of this method a large number of SLNBs, their related complications, and costs can be avoided. Additionally, in this technique there is no need for specific cytopathological examination requirements.

Acknowledgement

This article is the result of a thesis research project by Dr. Arash Talei, a general surgery resident (proposal code: 88-01-01-1577) under the guidance of Dr. Sedigheh Tahmasebi and Dr. Abdolrasoul Talei.

Conflict of interest

No conflict of interest is declared.

References

1. Tahmasebi S, Dalfardi B, Talei A, Safaei A, Monabati A, Akrami M. Concordant expression of estrogen and progesterone receptors in primary and loco-regional recurrent breast cancer. *MEJC*. 2013;4(3):113-8.
2. Oruwari JU, Chung MA, Koelliker S, Steinhoff MM, Cady B. Axillary staging using ultrasound-guided fine needle aspiration biopsy in locally advanced breast cancer. *Am J Surg*. 2002;184(4):307-9.
3. Mainiero MB, Cinelli CM, Koelliker SL, Graves TA, Chung MA. Axillary ultrasound and fine-needle aspiration in the preoperative evaluation of the breast cancer patient: an algorithm based on tumor size and lymph node appearance. *AJR Am J Roentgenol*. 2010;195(5):1261-7.
4. Warmuth MA, Bowen G, Prosnitz LR, Chu L, Broadwater G, Peterson B, et al. Complications of axillary lymph node dissection for carcinoma of the breast: a report based on a patient survey. *Cancer*. 1998;83(7):1362-8.
5. Britton PD, Goud A, Godward S, Barter S, Freeman A, Gaskarth M, et al. Use of ultrasound-guided axillary node core biopsy in staging of early breast cancer. *Eur Radiol*. 2009;19(3):561-9.
6. Meric F, Buchholz TA, Mirza NQ, Vlastos G, Ames FC, Ross MI, et al. Long-term complications associated with breast-conservation surgery and radiotherapy. *Ann Surg Oncol*. 2002;9(6):543-9.
7. Altomare V, Guerriero G, Carino R, Battista C, Primavera A, Altomare A, et al. Axillary lymph node echo-guided fine-needle aspiration cytology enables breast cancer patients to avoid a sentinel lymph node biopsy. Preliminary experience and a review of the literature. *Surg Today*. 2007;37(9):735-9.
8. Xing Y, Foy M, Cox DD, Kuerer HM, Hunt KK, Cormier JN. Meta-analysis of sentinel lymph node biopsy after preoperative chemotherapy in patients with breast cancer. *Br J Surg*. 2006;93(5):539-46.
9. Holwitt DM, Swatske ME, Gillanders WE, Monsees BS, Gao F, Aft RL, et al. Scientific presentation award: The combination of axillary ultrasound and ultrasound-guided biopsy is an accurate predictor of axillary stage in clinically node-negative breast cancer patients. *Am J Surg*. 2008;196(4):477-82.
10. Sabel MS, Schott AF, Kleer CG, Merajver S, Cimmino VM, Diehl KM, et al. Sentinel node biopsy prior to neoadjuvant chemotherapy. *Am J Surg*. 2003;186(2):102-5.
11. Lucci A, McCall LM, Beitsch PD, Whitworth PW, Reintgen DS, Blumencranz PW, et al. Surgical complications associated with sentinel lymph node dissection (SLND) plus axillary lymph node dissection

- compared with SLND alone in the American College of Surgeons Oncology Group Trial Z0011. *J Clin Oncol.* 2007;25(24):3657-63.
12. Sato K, Tamaki K, Tsuda H, Kosuda S, Kusano S, Hiraide H, et al. Utility of axillary ultrasound examination to select breast cancer patients suited for optimal sentinel node biopsy. *Am J Surg.* 2004; 187(6):679-83.
 13. Van Rijk MC, Deurloo EE, Nieweg OE, Gilhuijs KG, Peterse JL, Rutgers EJ, et al. Ultrasonography and fine-needle aspiration cytology can spare breast cancer patients unnecessary sentinel lymph node biopsy. *Ann Surg Oncol.* 2006;13(1):31-5.
 14. Specht MC, Fey JV, Borgen PI, Cody HS 3rd. Is the clinically positive axilla in breast cancer really a contraindication to sentinel lymph node biopsy? *J Am Coll Surg.* 2005;200(1):10-4.
 15. Swinson C, Ravichandran D, Nayagam M, Allen S. Ultrasound and fine needle aspiration cytology of the axilla in the pre-operative identification of axillary nodal involvement in breast cancer. *Eur J Surg Oncol.* 2009;35(11):1152-7.
 16. Kuijt GP, van de Poll-Franse LV, Voogd AC, Nieuwenhuijzen GA, Roumen RM. Survival after negative sentinel lymph node biopsy in breast cancer at least equivalent to after negative extensive axillary dissection. *Eur J Surg Oncol.* 2007;33(7):832-7.
 17. Holwitt DM, Gillanders WE, Aft RL, Eberlein TJ, Margenthaler JA. Sentinel lymph node biopsy in patients with multicentric/multifocal breast cancer: low false-negative rate and lack of axillary recurrence. *Am J Surg.* 2008;196(4):562-5.
 18. Topal U, Punar S, Taşdelen I, Adim SB. Role of ultrasound-guided core needle biopsy of axillary lymph nodes in the initial staging of breast carcinoma. *Eur J Radiol.* 2005;56(3):382-5.
 19. Abe H, Schmidt RA, Kulkarni K, Sennett CA, Mueller JS, Newstead GM. Axillary lymph nodes suspicious for breast cancer metastasis: sampling with US-guided 14-gauge core-needle biopsy--clinical experience in 100 patients. *Radiology.* 2009;250(1):41-9.