

Cutaneous Metastases from Different Internal Malignancies in Egypt

Amen Hamdy Zaky*[†], Mostafa Elsayed Abd El-Wanis*, Hisham Hamza*,
Hisham Zayan Abdel-Hafez**, Nagwa Essa Abdel-Azim**

*Departments of Medical Oncology, Radiotherapy and Surgical Oncology, South Egypt
Cancer Institute, Assuit University, Assuit, Egypt

**Dermatology Department, Faculty of Medicine, Assuit University

Abstract

Background: Cutaneous metastasis is defined as the spread of malignant cells from a primary malignancy to the skin. Generally, cutaneous involvement from internal malignancies is uncommon. No reports have focused on the cutaneous metastasis profiles in Egypt or the Middle Eastern population. In this study, we seek to determine the rates at which different internal malignancies give rise to cutaneous metastases upon first diagnosis of the primary tumor.

Methods: Patients with internal malignancies who attended the South Egypt Cancer Institute from January 2004 through May 2010 were examined and followed to identify cutaneous metastases, which were confirmed by biopsy and histological evaluation.

Results: Among 2208 cases of internal malignancies, 48 cases of cutaneous metastases were detected. The clinical profiles were similar to those from western and Asian countries, although the frequencies of primary tumors differed. Most commonly in Egypt breast cancer and urinary bladder cancers were seen.

Conclusion: The risk of skin metastases depends largely on the characteristics of tumor cells, which are similar among different groups.

Keywords: Internal malignancy, Cutaneous metastases, Egypt

Introduction

Cutaneous metastasis is defined as the spread of malignant cells from a primary malignancy to the skin. Generally, cutaneous involvement from internal malignancies is uncommon and has been estimated to occur in 0.7% to 9% of patients with internal cancer.¹⁻⁸ Skin infiltration

by cancer can occur via several different pathways: hematogenous, lymphatic, direct contiguous tissue invasion and iatrogenic implantation. Only the first two pathways have been widely regarded to represent true metastatic spread.³⁻⁹ Very few reports have examined variations in the frequencies of cutaneous

◆Corresponding Author:

Amen Hamdy Zaky, Medical
Oncology Department, South
Egypt Cancer Institute, Assuit
University, Assuit, Egypt
Tel: 002-88-2347671
Fax: 002-88-2302016
Email: Amenzaky74@yahoo.com



metastases from different internal malignancies.¹⁻⁶

In this retrospective study, we aimed to determine the rates at which different internal malignancies give rise to cutaneous metastases upon initial diagnosis of the primary tumor. In addition, cases were identified retrospectively based on the analysis of autopsy results. No similar studies of the rates of cutaneous metastases from different internal malignancies have been published for the Middle Eastern population.

Patients and Methods

This prospective study examined the rate of cutaneous metastases from various visceral malignancies in an Egyptian medical center population. Excluded were hematogenous malignancies (e.g., lymphoma or leukemia) and other primary skin malignancies. This study was approved by our local institutional board and Ethics Committee, and written informed consent was provided by all participants.

Patients who attended the South Egypt Cancer Institute from January 2004 through May 2010 underwent comprehensive examination and investigation to identify cases of proven visceral malignancies and cutaneous metastases. Cutaneous metastases were defined as cancer that spread through the blood stream or lymphatic system to involve the skin. Cutaneous involvement by direct extension of the tumor or iatrogenic implantation (e.g., needle tracts or surgical incision scars) was excluded, since the tumor did not spread via the hematogenous or lymphatic route.

Pathological examination of primary tumors for

all cases was done to determine the histologic characteristics; the diagnosis of skin metastases was based on clinicopathologic assessment of the involved skin and immune markers to determine tumor origin to confirm cutaneous metastasis.

Results

From January 2004 through May 2010, 2208 new cases of internal malignancies were seen at the South Egypt Cancer Institute, Assiut, Egypt. The most frequent cancers were urinary bladder and gastrointestinal tract followed by breast cancer. Among males, urinary bladder and gastrointestinal tract malignancies were the most common, followed by lung cancer. In females, breast and gastrointestinal tract malignancies were most common, followed by urinary bladder cancer (Table 1).

Frequency of distant metastases

Distant "extra-cutaneous" metastases occurred in 49.7% (n=183) of the cases. In general, 45% of the metastases were to the lymph nodes, followed by lung (19%), liver (18%) and brain (3%). Cutaneous metastases related to internal malignancies were present in 2% of the cases (Table 2).

Features of cutaneous metastases

Cutaneous metastases were diagnosed in patients with a proven newly diagnosed primary cancer. The majority of cutaneous lesions were correctly identified as metastases by the clinician before the pathologic diagnosis was available

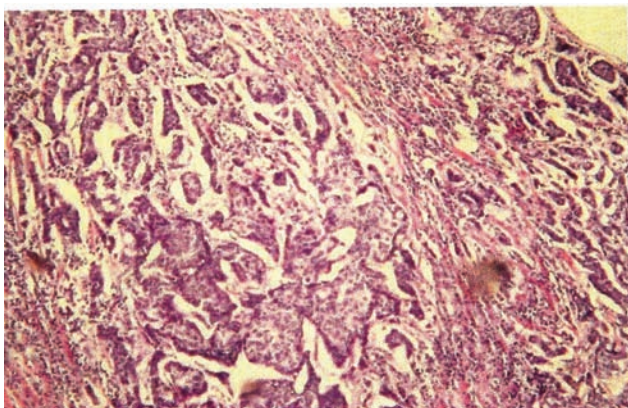


Figure 1. Histological evaluation of cutaneous metastatic nodule (H & E, 100 \times).

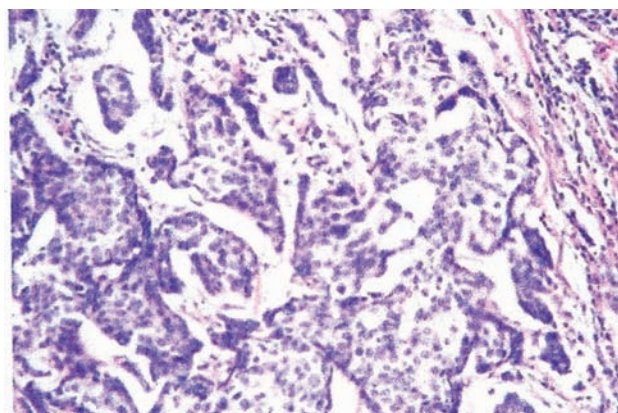


Figure 2. Infiltrating duct carcinoma of the breast (H & E, 100 \times).

Table 1. The frequency of visceral malignancies among studied cases.

Malignancies	Males (n=205)		Females (n=163)		Total
	No.	%	No.	%	
Urinary bladder	528	85	90	15	618
Gastrointestinal tract	360	60	240	40	600
Breast	0	0	354	100	354
Genital tract	18	17	90	83	108
Lung	78	76	24	24	102
Metastases of unknown origin	42	50	42	50	84
Laryngeal	66	92	6	8	72
Endocrine	18	30	42	70	48
Nervous system	36	75	12	25	48
Renal	30	71	12	29	42
Urinary tract	24	80	6	20	30
Muscle, bone and cartilage	6	20	24	80	30
Mouth	6	25	18	75	24
Throat	12	67	6	33	18
Nose	6	50	6	50	12
Peritoneal	0	0	6	100	6
Total	1230	56	978	44	2208

(Figure 1). However, some lesions were suspicious for benign entities. We identified 48 cases with cutaneous metastases, which represented 2% of all cases.

Twenty-four cases of cutaneous metastases originated from infiltrating ductal carcinoma of the breast, ten cases originated from urinary bladder cancer, eight cases of lung cancer, four cases of gastrointestinal tumors and one case was from an unknown primary malignancy (Table 2). The most common sites of cutaneous metastases were the chest (30.3%), abdomen (20.0%) and scalp

(12.6%). Metastases in the extremities and face were uncommon. Metastases tended to occur in the vicinity of the primary tumor. Multiple cutaneous metastatic lesions were seen in 56% of the cases whereas single lesions were present in 44%.

Discussion

Previous reports examining the rates of cutaneous metastases associated with different internal malignancies are limited to the Caucasian and Asian populations.¹⁻⁶ Prior studies of skin

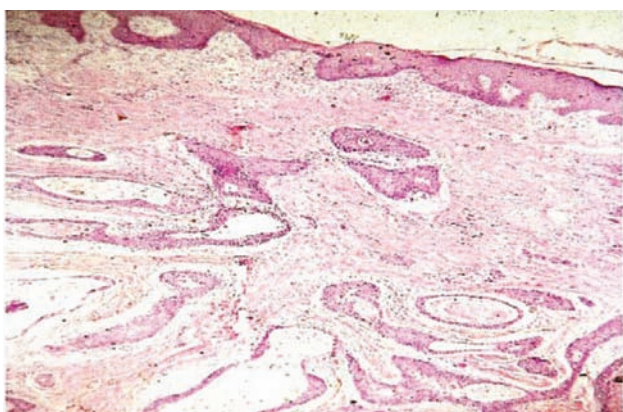


Figure 3. Histological evaluation of cutaneous metastatic nodule (H & E, 100×).

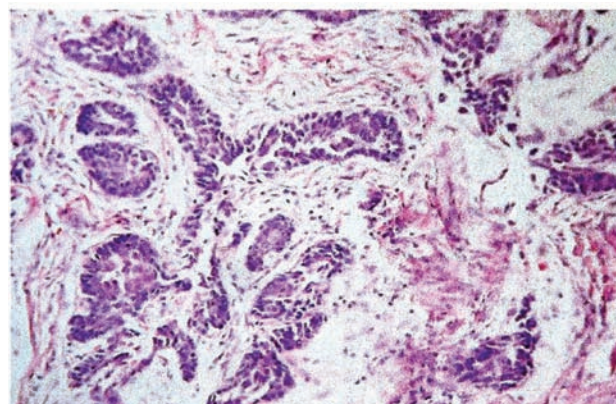


Figure 4. Squamous cell urinary bladder carcinoma (H & E, 100×).

Table 2: The frequency and sites of distant metastases.

Malignancy	Lymph nodes		Lung		Liver		Bone		Brain		Cutaneous	
	Freq	%	Freq	%	Freq	%	Freq	%	Freq	%	Freq	%
Urinary bladder	66	39.2	36	21.4	30	18	36	21.4	-	-	10	2
Gastrointestinal tract	222	55.2	66	16.4	84	21	30	7.5	-	-	4	14
Breast	29	51.8	78	23.2	42	12.5	42	12.5	-	-	24	7
Genital tract	30	41.6	18	25	12	16.7	12	16.7	-	-	-	-
Lung	54	50	-	-	12	11.1	24	22.2	18	16.7	8	10
Metastases of unknown origin	30	16.7	42	23.3	30	16.7	60	33.3	18	10	1	7
Laryngeal	24	50	6	25	6	25	-	-	-	-	-	-
Endocrine	24	44.4	12	22.2	6	11.1	12	22.2	-	-	-	-
Renal	6	12.5	12	25	18	37.5	12	25	-	-	-	-
Urinary tract	12	29	6	14	18	43	6	14	-	-	-	-
Muscle, bone and cartilage	6	100	-	-	-	-	-	-	-	-	-	-
Mouth	-	-	6	50	6	50	-	-	-	-	-	-
Throat	18	75	-	-	-	-	-	-	6	25	-	-
Nose	6	100	-	-	-	-	-	-	-	-	-	-
Total	666	45	282	19	264	18	234	16	42	3	48	2

involvement by malignant tumors have mostly involved Caucasian populations. No extensive reports in the literature have analyzed the clinical features of cutaneous metastases in Egypt despite differences in the frequencies of different primary tumors between these populations. In this study, cutaneous metastases originated most commonly from breast cancer in females whereas lung and bladder cancers were more common in males. This was different from studies in Caucasian and Asian populations.⁷⁻¹⁴

Several factors may have influenced the different rate of cutaneous metastases in our study. First, we included only newly diagnosed, pathology-proven primary internal malignancies and cutaneous metastases. Known cases that developed cutaneous metastases were excluded. Second, the study included a number of malignancies known to have low frequencies of cutaneous metastasis but a high incidence in Egypt, such as urinary bladder carcinoma. Third, previous studies were based on autopsy reports, which were likely to find more cases of cutaneous metastases that were not clinically apparent. Finally, the exclusion of patients with direct tumor extension or iatrogenic implantation may have contributed to the low cutaneous metastatic rate in the population we studied.

The mechanisms that predispose certain

internal malignancies to metastasize to the skin have rarely been discussed in the scientific literature. Paget first described the "soil-seed" hypothesis, which states that tumors preferentially metastasize to those organs with an intrinsically favorable environment.¹⁵ It is possible that the skin may provide a favorable environment for the colonization and survival of only certain types of cancer cells. In addition, the interaction between tumor cells and certain factors secreted from the dermis or epidermis may play a crucial role in the skin homing mechanism of metastatic cells.

Cutaneous metastases are known to frequently occur in anatomical areas close to the primary tumor.^{3,16,17} In our study, a large proportion of breast cancers metastasized to the trunk, which most likely resulted from the lymphatic dissemination of cancer cells. However, some cutaneous lesions occurred in regions distant from the primary tumor. For example, the scalp has been described as a common location for distant metastases.^{3,7,17-22} In our study, eight patients had scalp metastases. On the other hand, metastases to the lower limbs were rare, despite the large surface area of this anatomic site. In addition, gastrointestinal tumors frequently presented as umbilical nodules (so-called Sister Mary Joseph nodules).²³⁻²⁷ This phenomenon reflects hematogenous dissemination through vascular

Table 3. The distribution of cutaneous metastasis.

Sites of cutaneous metastases	Frequency
Chest	22
Abdomen	15
Scalp	8
Face	1
Upper extremity	1

anastomoses between the umbilical skin and the gastrointestinal tract.³

Our results indicate that the clinical profiles of skin metastases depend largely on the characteristics of tumor cells, which are similar among different ethnic groups. Our findings indicate that the rates of cutaneous metastases arising from different internal malignancies differ due to differences in the incidence of types of malignancy, as exemplified by breast and urinary bladder cancers.

References

- Abrams HL, Spiro R, Goldstein N. Metastases in carcinoma; analysis of 1000 autopsied cases. *Cancer* 1950;3:74-85.
- Reingold IM. Cutaneous metastases from internal carcinoma. *Cancer* 1966;19:162-8.
- Rosen T. Cutaneous metastases. *Med Clin North Am* 1980;64:885-900.
- Spencer PS, Helm TN. Skin metastases in cancer patients. *Cutis* 1987;39:119-21.
- Lookingbill DP, Spangler N, Sexton FM. Skin involvement as the presenting sign of internal carcinoma. A retrospective study of 7316 cancer patients. *J Am Acad Dermatol* 1990; 22:19-26.
- Schwartz RA. Cutaneous metastatic disease. *J Am Acad Dermatol* 1995; 33: 161-82.
- Krathen RA, Orengo IF, Rosen T. Cutaneous metastasis: A meta-analysis of data. *South Med J* 2003;96:164-7.
- Mueller TJ, Wu H, Greenberg RE, Hudes G, Topham N, Lessin SR, et al. Cutaneous metastases from genitourinary malignancies. *Urology* 2004;63:1021-6.
- White JW Jr. Evaluating cancer metastatic to the skin. *Geriatrics* 1985;40:67-73.
- Brownstein MH, Helwig EB. Metastatic tumors of the skin. *Cancer* 1972;29:1298-307.
- Brownstein MH, Helwig EB. Patterns of cutaneous metastasis. *Arch Dermatol* 1972;105:862-8.
- Sariya D, Ruth K, Adams-McDonnell R, Cusack C, Xu X, Elenitsas R, et al. Clinicopathologic correlation of cutaneous metastases: Experience from a cancer center. *Arch Dermatol* 2007;143:613-20.
- Saeed S, Keehn CA, Morgan MB. Cutaneous metastasis: A clinical, pathological, and immunohistochemical appraisal. *J Cutan Pathol* 2004;31:419-30.
- Marcovall J, Moreno A, Peyri J. Cutaneous infiltration by cancer. *J Am Acad Dermatol* 2007;57:577-80.
- Paget S. The distribution of secondary growths in cancer of the breast. *Lancet* 1889;1:571-3.
- Saeed S, Keehn CA, Morgan MB. Cutaneous metastasis: A clinical, pathological, and immunohistochemical appraisal. *J Cutan Pathol* 2004;31:419-30.
- Lookingbill DP, Spangler N, Helm KF. Cutaneous metastases in patients with metastatic carcinoma: A retrospective study of 4020 patients. *J Am Acad Dermatol* 1993;29:228-36.
- Faust HB, Treadwell PA. Metastatic adenocarcinoma of the scalp mimicking a kerion. *J Am Acad Dermatol* 1993;29: 654-5.
- Prasoon D. Follicular carcinoma of thyroid gland presenting as scalp metastasis. *Acta Cytol* 1998;42:451-2.
- Park JY, Lee HS, Cho KH. Cutaneous metastasis to the scalp from squamous cell carcinoma of the cervix. *Clin Exp Dermatol* 2003;28:28- 30.
- Roh EK, Nord R, Jukic DM. Scalp metastasis from esophageal adenocarcinoma. *Cutis* 2006;77:106-8.
- Estrada-Chavez G, Vega-Memije ME, Lacy-Niebla RM, Toussaint-Caire S. Scalp metastases of a renal cell carcinoma. *Skin Med* 2006;5:148-50.
- Gabriele R, Conte M, Egidi F, Borghese M. Umbilical metastases: Current viewpoint. *World J Surg Oncol* 2005;3:13-5.
- Scudeler D, Wakely PE Jr. Fine needle aspiration biopsy of gastrointestinal stromal tumor presenting as an umbilical mass (Sister Mary Joseph's Nodule). *Ann Diagn Pathol* 2006;10:100-3.
- Kundranda MN, Daw AH. Sister Mary Joseph nodule: An important sign of an ominous diagnosis. *Intern Med J* 2006; 36:617-20.
- Sina B, Deng A. Umbilical metastasis from prostate carcinoma (Sister Mary Joseph's nodule): A case report and review of literature. *J Cutan Pathol* 2007;34:581-3.
- Stanko C, Grandinetti L, Baldassano M, Mohmoodi M, Kantor GR. Epidermotropic metastatic prostate carcinoma presenting as an umbilical nodule-Sister Mary Joseph nodule. *Am J Dermatopathol* 2007;29:290-2.