

## Bilateral Synchronous Male Breast Cancer in Iran: A Case Report

Vahid Zangouri\*, Mohammad Yasin Karami\*\*\*, Maral Mokhtari\*\*\*,  
Majid Akrami\*, Sedighe Tahmasebi\*, Abdolrasoul Talei\*,  
Mehrnoosh Maalhigh\*\*

\*Breast Diseases Research Center, Department of Surgery, School of Medicine, Shiraz University of Medical Sciences, Shiraz, Iran

\*\*Student Research Committee, School of Medicine, Shiraz University of Medical Sciences, Shiraz, Iran

\*\*\*Department of Pathology, School of Medicine, Shiraz University of Medical Sciences, Shiraz, Iran

### Abstract

Bilateral synchronous male breast cancer is very rare. A 63-year-old male presented with rapidly progressive enlarging bilateral breast masses without ulceration and bloody nipple discharge. Synchronous bilateral breast cancer was diagnosed by fine needle aspiration cytology. Pathology study revealed grade 2 invasive ductal carcinoma in both breasts. He underwent a bilateral modified radical mastectomy followed by chemotherapy and hormone therapy. The importance of this case report is to create increased attention to the fact that, although rare, breast cancer can occur in males. Early presentation and compliance with treatment modality provide a better outcome.

**Keywords:** Breast, Cancer, Male, Synchronous

### Introduction

Male breast cancer is an uncommon malignancy with a paucity of information in the literature that accounts for 1.2%-2% of all cancers in males and less than 1% of all breast cancers in both sexes.<sup>1,2</sup> Bilateral synchronous male breast cancer (BSMBC) is extremely rare and accounts for just 1% of male breast cancers.<sup>3,4</sup> Carcinoma of the male breast presents in a similar pattern to female breast cancer,

however there is limited data regarding treatment of male breast cancer.<sup>5</sup> We present this case of BSMBC for its rarity in conjunction with its clinical and pathological findings.

### Case Report

A 63-year-old male referred to the Breast Clinic Division of our central Surgical Oncology Hospital for complaints of bilateral breast lumps since 3 months prior to presentation.

♦Corresponding Author:

Mohammad Yasin Karami, MD  
Department of Surgery, Faghihi  
Hospital, Shiraz University of  
Medical Sciences, Shiraz, Iran  
Tel: +98-917-1800710  
Fax: +98-71-32330724  
Email: karamiy@sums.ac.ir

The patient mentioned a small, painless lump in his right breast which progressively increased in size. After one month, he noticed another painless lump in his left breast region which also gradually increased in size. There was no nipple retraction, nor evidence of any ulceration, edema, itching, or bloody discharge in either breast. Axillary lymphadenopathies were not found on clinical examination. There was no history of trauma, familial breast disease/malignancy, gynecomastia, or hormone treatment. He had no history of smoking or alcohol consumption.

A general examination revealed non-tender, firm masses in the right breast outer lower quadrant (2x1 cm) and left breast inner lower quadrant (2x2 cm). There were no palpable axillary lymph nodes bilaterally. Both testicles were normal. Hematological and biochemical analyses were normal.

The patient's hormone profile of testosterone, prolactin and thyroid function tests, estradiol, luteinizing hormone (LH), and follicular stimulating hormone (FSH) were normal.

Abdominal and pelvis ultrasonography and X-rays of the chest and abdomen detected no evidence of metastases. Fine needle aspiration cytology (FNAC) was positive for malignancy and similar for both right and left breast masses.

The patient underwent a bilateral modified radical mastectomy and specimens were sent for histopathological studies.

The left mastectomy specimen showed a 2.5x1.5x1.8 cm mass with blood, lymphatic vessels and perineural invasion without microcalcifications and necrosis. The skin and nipple had tumor involvement. Out of 23 left axillary lymph nodes, none had any evidence of metastasis.

The right mastectomy specimen showed a 2.5x2x2.5 cm mass with lymphatic vessel invasion and microcalcifications, but no blood vessel or perineural invasion. The skin and nipple were without tumor. Out of 13 right axillary lymph nodes, none showed any evidence of metastasis.

Histopathological diagnosis was grade 2 bilateral invasive ductal carcinoma according to the Nottingham Modification of the Bloom-Richardson Breast Cancer Grading System (Figure

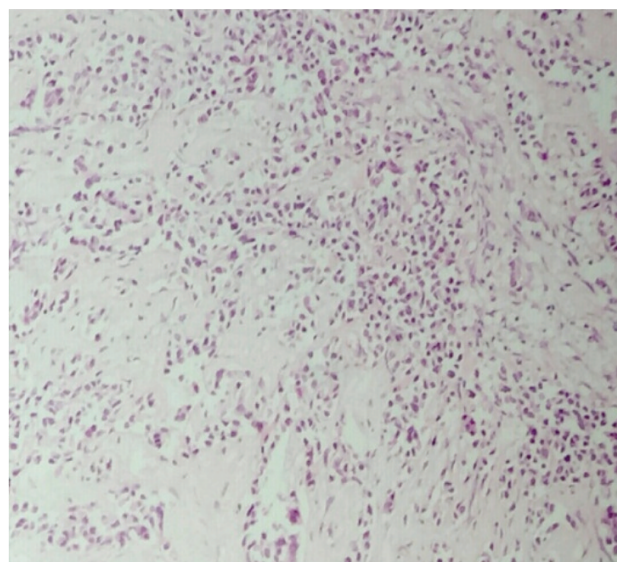
1 and 2). All margins were free from tumor. Immunohistochemistry analysis showed the tumor to be strongly ER, PR positive in 90% of the right cells and 80% of the left cells. The patient was treated with tamoxifen. Her-2-neu status was negative and he did not receive trastuzumab (Herceptin). BRCA 1 and BRCA 2 were negative. He received 6 cycles of the cyclophosphamide, doxorubicin, and 5-fluorouracil chemotherapy regime. To the best of our knowledge, this was the first case of BSMBC in Iran.

Currently, the patient has survived for 48 months and is asymptomatic with stable disease (Figure 3). The patient provided written informed consent for publication of this case report and accompanying images. A copy of the written consent is available for review by the Editor-in-Chief of this journal.

## Discussion

Bilateral breast cancer is defined as the occurrence of an independent primary malignant tumor in each breast tissue. The term "synchronous" refers to the concurrent diagnosis of primary tumors in both breasts. The risk factors for male breast cancer include familial and genetic factors (BRCA2), radiation exposure, Klinefelter's syndrome, hormonal imbalance, and obesity.<sup>6</sup>

Testicular conditions associated with an



**Figure 1.** Histological section of the left breast mass shows diffuse infiltration of malignant epithelial cells with scant duct formation. (H&E, 400x)

**Table 1.** Risk factors for breast cancer in men.

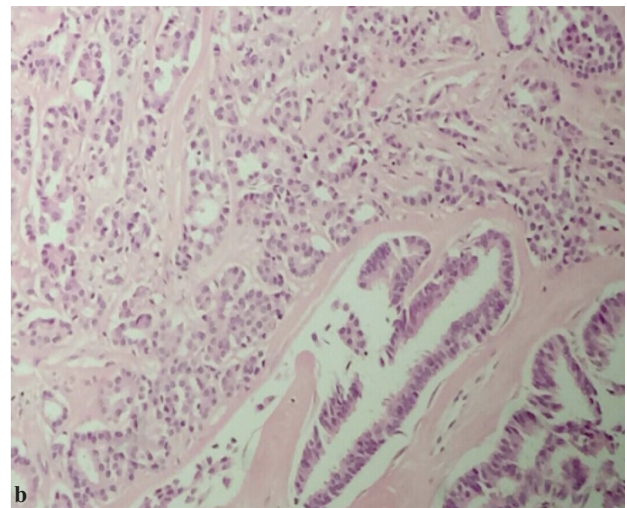
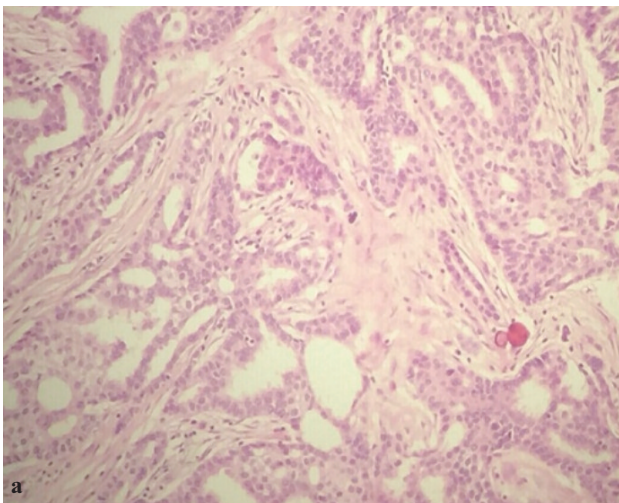
Age	
<b>Genetic factors</b>	Well-established
	Possible
<b>Conditions associated with an abnormal estrogen-to-androgen ratio</b>	
<b>Lifestyle Exposures</b>	Possible
<b>Miscellaneous possible risk factors</b>	

Reproduced from: Ruddy KJ, Winer EP. Male breast cancer: Risk factors, biology, diagnosis, treatment, and survivorship. *Ann Oncol* 2013; 24:1434, by permission of Oxford University Press on behalf of the European Society for Medical Oncology. Copyright © 2013.

increased risk of breast cancer in males include testicular disease (cryptorchidism, orchitis, orchiectomy, and testicular injury).

Breast cancer in males presents in a similar mode to that in females, however there is inadequate data about treatment of male breast cancer. Breast cancers in males appear to allocate parallel risk factors with postmenopausal breast cancer in females.<sup>7</sup> The vast majority of males with

breast cancer have no identifiable risk factors (Table 1). A family history of breast cancer in a male first-degree relative is related with an increased risk of breast cancer among males, as with breast cancer in females.<sup>8</sup> Inherited mutations in BRCA, higher with inherited BRCA2 rather than BRCA1 mutations and germline BRCA2 mutations, also increase the risk of breast cancer in men.<sup>9</sup> For this reason, all males diagnosed with



**Figure 2.** a) Section from the right breast mass shows infiltrating growth of malignant ducts in desmoplastic stroma. Microcalcifications are present. H&E, 250×, b) Histological section of right breast mass shows infiltration of various sized ducts with mild nuclear pleomorphism and few mitotic figures. (H&E, 400×)

breast cancer should be referred for genetic counseling and BRCA testing.

Mutations in the PTEN tumor suppressor gene (Cowden's syndrome); mutations in TP53 (Li-Fraumeni syndrome); PALB2 mutations; and mutations in mismatch repair genes associated with hereditary nonpolyposis colorectal cancer (Lynch syndrome) are associated with an increased risk of breast cancer in males.<sup>10-12</sup> However, the authors do not recommend screening mammography or mastectomy in affected males. In the current case, no such risk factor was identified.

Our patient had tumors in both breasts on hospital admission. A total of 25 cases of BSMBC have been reported as of August 2015 using a PubMed search.<sup>13</sup>

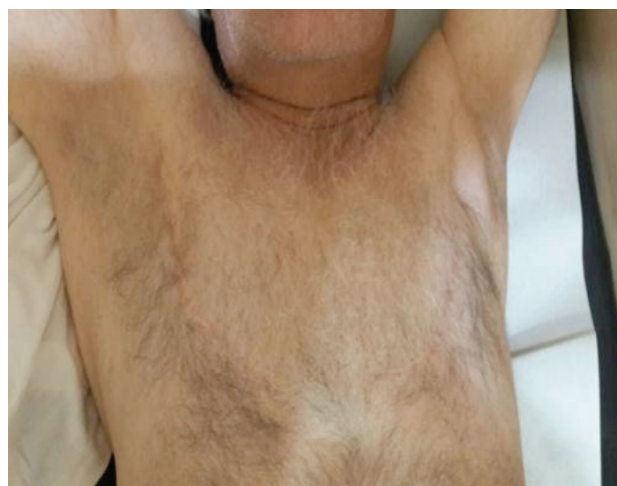While breast cancers concern men of all ages, the median age at diagnosis is 60-70 years<sup>14</sup> which is in keeping with the age of our patient (63 years). The mean age is 67 years, older than that seen in women.

Presentation is usually late with more than 46% of patients having stage 3 or 4 of the disease at the time of diagnosis,<sup>5</sup> which is dissimilar to our case. This presentation can be attributed to high alertness in our clinical system, thus allowing rapid diagnosis. The approach to the male patient who presents with a suspicious breast mass is similar to that of women and includes mammography and biopsy.

The most common histological form in men is invasive ductal carcinoma (90%); most of the invasive carcinomas seen in men are the ductal and papillary types, while a smaller portion is of lobular and mucinous type,<sup>15</sup> which is like the result of this case.

Tumor size and lymph node involvement are two clear prognostic factors for male breast cancer. Higher survival rates of up to 85% are seen with tumor sizes of <2 cm. Men with lymph node involvement have a 50% higher risk of death than those without lymph node involvement.<sup>16</sup>

Clinically, most breast cancers in men present as lumps and bloody nipple discharges or retractions,<sup>8</sup> but they are often detected late. In our



**Figure 3.** Photograph showing bilateral breast mastectomy incision site 4 years after surgery.

case, the patient presented early with small masses without skin ulceration or bloody nipple discharge, nipple retraction and axillary nodal involvement.

On histopathology analysis identified grade 2 invasive ductal carcinomas with blood, lymphatic vessel, and perineural invasion, which favored poor prognostic criteria. He had an uneventful post-operative period. The patient received chemotherapy and hormone therapy and he responded well to treatment.

The basis of treatment is local and regional disease control with surgery, adjuvant chemotherapy, and hormone therapy.<sup>8</sup>

This was similar to the management of our patient, whose treatment comprised Modified Radical Mastectomy (MRM), chemotherapy, and hormone therapy. The prognosis of male breast cancer has remained poor because of late diagnosis, irregular course, and high potential for metastasis.

The importance of this case is to create more awareness that breast cancer can occur in males just like females, although it is uncommon in males. A painless lump without bloody nipple discharge or retraction in an elderly male requires careful assessment and proof of cancer.

## Conclusion

Bilateral synchronous male breast cancer is an exclusive finding although its incidence is increasing, as reported here. To the best of our

knowledge this is the first case of BSMBC in the Iranian population.

Although breast cancer in men was once associated with a considerably worse prognosis compared to women, most modern-day reports have not validated a significantly poorer survival in men.<sup>7,17,18</sup> As in women, tumor size and the presence in addition to number of involved nodes are the most important prognostic factors for breast cancers in males.<sup>19</sup> Breast cancer does occur in males. Patients must become conscious of its existence and the value of surgical assessment for any lump in their breasts. Aggressive surgical and medical treatment can decrease progress and the incidence of tumor recurrence, and offer a better prognosis for the patient.

### Conflict of interest

No conflict of interest is declared.

### References

- Ravandi-Kashani F, Hayes TG. Male breast cancer: a review of the literature. *Eur J Cancer*. 1998;34(9):1341-7.
- Ozet A, Yavuz AA, Kömürçü S, Oztürk B, Safali M, Arpacı F, et al. Bilateral male breast cancer and prostate cancer: a case report. *Jpn J Clin Oncol*. 2000;30(4):188-90.
- Kahla PB, Cassaro S, Vladimir FG, Wayne MG, Cammarata A. Bilateral synchronous breast cancer in a male. *Mt Sinai J Med*. 2005;72(2):120-3.
- Camus MG, Joshi MG, Mackarem G, Lee AK, Rossi RL, Munson JL, et al. Ductal carcinoma in situ of the male breast. *Cancer*. 1994;74(4):1289-93.
- dos Santos VM, Cintra Osterne EM, de Castro RA, Marques HV Jr. Bilateral male breast cancer: too many concerns? *Asian Pac J Cancer Prev*. 2007;8(4):640-1.
- Weiss JR, Moysich KB, Swede H. Epidemiology of male breast cancer. *Cancer Epidemiol Biomarkers Prev*. 2005;14(1):20-6.
- Anderson WF, Althuis MD, Brinton LA, Devesa SS. Is male breast cancer similar or different than female breast cancer? *Breast Cancer Res Treat*. 2004;83(1):77-86.
- Gómez-Raposo C, Zambrana Tévar F, Sereno Moyano M, López Gómez M, Casado E. Male breast cancer. *Cancer Treat Rev*. 2010;36(6):451-7.
- Tai YC, Domchek S, Parmigiani G, Chen S. Breast cancer risk among male BRCA1 and BRCA2 mutation carriers. *J Natl Cancer Inst*. 2007;99(23):1811-4.
- Ding YC, Steele L, Kuan CJ, Greilac S, Neuhausen SL. Mutations in BRCA2 and PALB2 in male breast cancer cases from the United States. *Breast Cancer Res Treat*. 2011;126(3):771-8.
- Silvestri V, Rizzolo P, Zanna I, Falchetti M, Masala G, Bianchi S, et al. PALB2 mutations in male breast cancer: a population-based study in Central Italy. *Breast Cancer Res Treat*. 2010;122(1):299-301.
- Boyd J, Rhei E, Federici MG, Borgen PI, Watson P, Franklin B, et al. Male breast cancer in the hereditary nonpolyposis colorectal cancer syndrome. *Breast Cancer Res Treat*. 1999;53(1):87-91.
- Nwashilli NJ, Ugiagbe EE. Bilateral synchronous male breast cancer. *Saudi Med J*. 2015;36(3):359-62.
- Sosnovskikh I, Naninato P, Gatti G, Caldarella P, Masullo M, De Brito LL, et al. Synchronous bilateral breast cancer in men: a case report and review of the literature. *Tumori*. 2007;93(2):225-7.
- Burga AM, Fadare O, Lininger RA, Tavassoli FA. Invasive carcinomas of the male breast: a morphologic study of the distribution of histologic subtypes and metastatic patterns in 778 cases. *Virchows Arch*. 2006;449(5):507-12.
- Jagtap SV, Chougule PG, Khatib W, Shukla DB, Jagtap SS. Male breast cancer: presenting as synchronous, large, bilateral masses. *J Clin Diagn Res*. 2014;8(4):FD07-8.
- Gnerlich JL, Deshpande AD, Jeffe DB, Seelam S, Kimbuende E, Margenthaler JA. Poorer survival outcomes for male breast cancer compared with female breast cancer may be attributable to in-stage migration. *Ann Surg Oncol*. 2011;18(7):1837-44.
- El-Tamer MB, Komenaka IK, Troxel A, Li H, Joseph KA, Ditkoff BA, et al. Men with breast cancer have better disease-specific survival than women. *Arch Surg*. 2004;139(10):1079-82.
- Vetto J, Jun SY, Paduch D, Eppich H, Shih R. Stages at presentation, prognostic factors, and outcome of breast cancer in males. *Am J Surg*. 1999;177(5):379-83.