

Adenocarcinoma of the Rectum with Cutaneous Metastases

Gamal Abdul Hamid**, Nohad Hanbala**

*Hematology-Oncology Department, Al-Gamhouria Teaching Hospital, Aden, Yemen

** Pathology department, Faculty of Medicine, University of Aden, Aden, Yemen

Abstract

Cutaneous metastases of rectal carcinoma is a rare event. It occurs in fewer than 4% of all patients with rectal cancer. When present, it typically signifies a disseminated disease with a poor prognosis. Early detection and proper diagnosis of metastatic rectal cancer can significantly alter treatment and prognosis. We report a 70-year-old male who underwent rectal resection with permanent colostomy for rectal adenocarcinoma since seven years. The patient recently developed multiple skin nodules, mainly in his face, scalp, and upper trunk, associated with itching. Fine needle aspiration cytology from a face nodule was done which revealed metastatic adenocarcinoma associated with severe inflammation. Cutaneous metastasis of rectal adenocarcinoma is an unusual event that presents mainly in the form of skin nodules and could be the first sign of metastasis. Early diagnosis of cutaneous metastasis in these patients is important because it can alter treatment and prognosis.

Keywords: Rectal carcinoma, Adenocarcinoma, Cutaneous, Skin, Metastases

Introduction

Cutaneous metastases of rectal carcinoma is a rare event, it occurs in fewer than 4% of all patients with rectal cancer.¹⁻⁴ When present, it typically signifies disseminated disease with a poor prognosis. The early detection and proper diagnosis of metastatic rectal cancer can significantly alter treatment and prognosis.^{1, 2}

Case Report

A 70-year-old male with a seven year history of documented rectal

adenocarcinoma (T3N0M0) presented to the Pathology Department of Al-Gamhouria Teaching Hospital from Al-Amal Oncology Center with a two-month history of cutaneous nodules, approximately 1 to 2 cm in dimension, which were hard on palpation. The nodules were located on the face, scalp, and upper trunk and were associated with itching. During this period, the patient was followed by a dermatologist, with no benefit. This aroused the suspicions of the dermatologist, who sent the

♦Corresponding Author:

Gamal Abdul Hamid, MD
Hematology-Oncology
Department, Oncology Center
(Al-Amal), Al-Gamhouria
Teaching Hospital, Aden, Yemen
Tel/Fax: +967-2-271111
Email: drgamal2000@yahoo.com

patient to the Oncology Unit. On examination the patient looked well and had no complaints, except for the nodules and weight loss. There was neither clinical nor radiological evidence of visceral involvement. The skin nodules were firm, fixed, and some were erythematous and tender. Other areas showed diffuse erythema.

After resection and permanent colostomy, the patient was disease-free and did not receive chemotherapy. Blood tests were as follows: hemoglobin(12.3 g/dl); white blood cell count (5200 cm); platelets (254,000); and differential WBC count: neutrophils (52%), lymphocytes (47%), and eosinophils (1%). Liver and renal function tests were normal. The carcinoembryonic antigen (CEA) level at that time was 65 ng/ml. Repeat fine needle aspiration cytology (FNAC) from a face nodule was obtained and stained for routine H&E. Microscopic examination revealed a moderately differentiated adenocarcinoma associated with severe inflammation. Chemotherapy was started and the patient received eight courses of a Mayo Clinic regimen (5-fluorouracil and leuovorin), with good response.

Discussion

Most previous studies have found that cutaneous metastases occur infrequently and are rarely present at the time the cancer is initially diagnosed. From the Tumor Registry data of 7316 cancer patients, Looking bill et al.⁵ found 5.0%

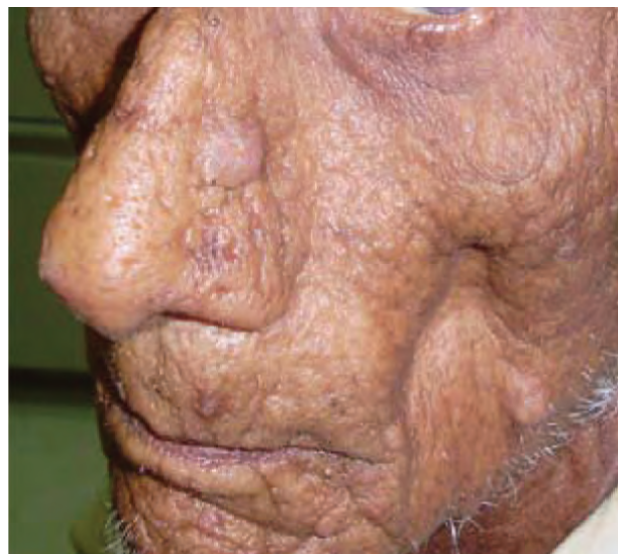

Figure 1. Clinical photograph showing multiple skin nodules.

with skin involvement. Skin involvement was present at the time of presentation in 1.3%, and was the first sign of cancer in 0.8%. In another study by Lookingbill et al.,⁶ 10% of the 4020 patients with metastatic carcinoma had cutaneous metastasis.

Although skin metastasis of rectal cancer is usually detected around surgical scars or on the abdominal wall, especially in the periumbilical region, it rarely presents at other sites.^{1,7} Kilickap et al.¹ have reported a case of cutaneous metastases of signet cell carcinoma of the rectum without accompanying visceral involvement that occurred 14 months after completion of adjuvant therapy.

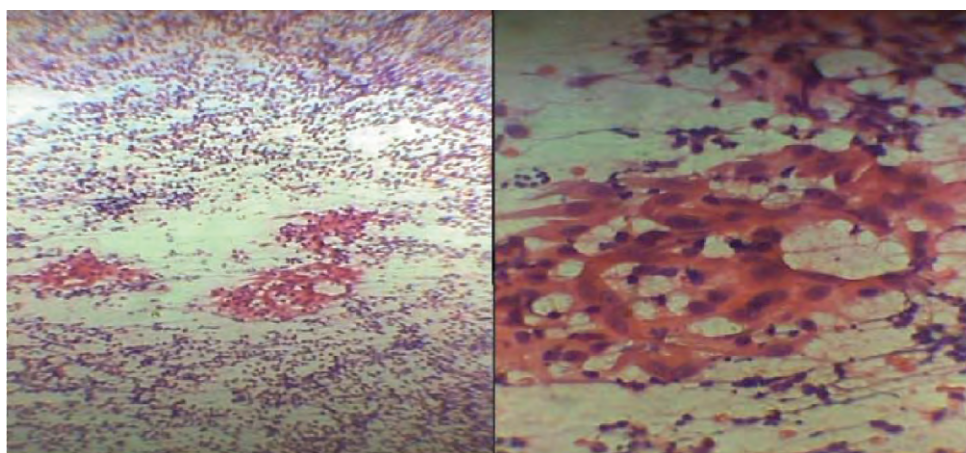


Figure 2. Microscopical examination revealed a moderately differentiated adenocarcinoma with dermal infiltration associated with severe inflammation. (H&E staining, Magnification:10× and 40×).

Gazoni et al.³ made a retrospective review of six patients with rectal cancer metastatic to the dermis; they found that a 100% histopathologic concordance existed between the tissue of the dermal metastases and the primary rectal tumor. The progression of systemic metastatic disease was the cause of death in 83.3% of patients, and no patient survived more than seven months from the time of diagnosis. Wong et al.⁸ have described a patient with colonic carcinoma who developed an inflammatory pattern of cutaneous metastases, which showed that this entity is important as it may be mistaken for erysipelas and radiation recall phenomenon. Kauffman and Sina⁹ have reported the case of a patient with adenocarcinoma of the rectum with inflammatory metastases to the skin. Moonda and Fatteh⁴ described a case of colorectal signet ring carcinoma with metastasis to the upper lip. This was reported to be a case of colorectal carcinoma with metastasis to the lip, first with signet ring features that should have been considered in the differential diagnosis of adnexal tumors, as it may have been an initial presentation of colon carcinoma. Tsai et al.¹⁰ reported a 45-year-old male who underwent abdominoperineal resection for an advanced rectal signet-ring cell carcinoma and developed multiple skin metastases to the scalp, face, neck, back, and abdomen despite postoperative adjuvant chemotherapy. The patient died from lung metastases 15 months after resection of the primary rectal tumor.

Our patient was disease-free for seven years, giving the diagnosis of early stage rectal carcinoma both at the time of resection and more recently with the development of cutaneous metastasis. He had no evidence of visceral involvement, either clinical or radiological. He received eight courses of 5-fluorouracil and leuovorin, with good response and complete relief from itching.

Conclusion

Cutaneous metastases of rectal adenocarcinoma are an unusual event that presents mainly in the form of skin nodules, and could be the first sign of metastasis. Early diagnosis of cutaneous

metastasis in these patients is important because it can alter treatment. It is crucial that practitioners educate patients with a history of rectal adenocarcinoma to recognize the signs of cutaneous metastasis. A follow up of these patients should always include a careful dermatologic examination.

References

1. Kilickap S, Aksoy S, Dincer M, Saglam E, Yalcin S. Cutaneous metastasis of signet cell carcinoma of the rectum without accompanying visceral involvement. *South Med J* 2006;99(10):1137-9.
2. Rendi MH, Dhar AD. Cutaneous metastasis of rectal adenocarcinoma. *Dermatol Nurs* 2003;15(2):131-2.
3. Gazoni LM, Hedrick TL, Smith PW, Friel CM, Swenson BR, Adams JD, et al. Cutaneous metastasis in patients with rectal cancer: A report of six cases. *Am Surg* 2008;74(2):138-40.
4. Moonda A, Fatteh S. Metastatic colorectal carcinoma: An unusual presentation. *J Cutan Pathol* 2009; 36(1):64-6.
5. Lookingbill DP, Spangler N, Sexton FM. Skin involvement as the presenting sign of internal carcinoma. A retrospective study of 7316 cancer patients. *J Am Acad Dermatol* 1990;22(1):19-26.
6. Lookingbill DP, Spangler N, Helm KF. Cutaneous metastasis in patients with metastatic carcinoma: A retrospective study of 4020 patients. *J Am Acad Dermatol* 1993;29(2 Pt 1):228-36.
7. Kronic AL, Chen HM, Lopatka K. Signet ring cell carcinoma of the gallbladder with skin metastasis. *Australas J Dermatol* 2007;48(3):187-9.
8. Wong NS, Chang BM, Toh HC, Koo WH. Inflammatory metastatic carcinoma of the colon: A case report and review of the literature. *Tumori* 2004;90(2):253-5.
9. Kauffman CL, Sina B. Metastatic inflammatory carcinoma of the rectum: Tumour spread by three routes. *Am J Dermatopathol* 1997;19(5):528-32.
10. Tsai HL, Huang YS, Hsieh JS, Huang TJ, Tsai KB. Signet-ring cell carcinoma of the rectum with diffuse and multiple skin metastasis- a case report. *Kaohsiung J Med Sci* 2002;18(7):359-62.