

Hodgkin's Lymphoma with Cutaneous Involvement

Ahmad Ameri, Ainaz Sourati*

Department of Radiation Oncology, Imam Hossein Hospital, Shahid Beheshti University of Medical Sciences, Tehran, Iran

Abstract

Cutaneous Hodgkin's lymphoma is a rare disease (0.5% to 3.4%) which tends to be in the setting of an advanced disease and has a poor prognosis. Treatment of patients with cutaneous involvement of Hodgkin's lymphoma is according to dissemination of disease (systemic or localized therapy). The majority of data in this context are based on individual case reports or literature reviews. We have reported a case of Hodgkin's lymphoma that relapsed with isolated cutaneous involvement two years after completion of his first treatment. Our case had no response to systemic chemotherapy but obtained a complete remission to radiation therapy and had long-term disease-free survival. Radiotherapy might be considered a good salvage treatment in patients with cutaneous Hodgkin's lymphoma with long-term disease-free survival.

Keywords: Hodgkin's lymphoma, Cutaneous, Radiation therapy

Introduction

Hodgkin's lymphoma (HL) is relatively rare type of cancer which includes about 10% of all lymphomas and approximately 0.6% of all cancers diagnosed annually.¹ Painless lymphadenopathy is the most common presentation of HL. Cutaneous lesions associated with HL may occur in 17% to 53% of patients² and can be attributed to paraneoplastic syndrome, other cutaneous lymph-proliferative disorders such as mycosis fungoides, or cutaneous involvement with HL. The latter is a rare disease (0.5% to 3.4% of all cases) that usually occurs

late in the course of the disease and is often secondary to visceral or nodal involvement.³⁻⁵

Hodgkin's lymphoma with cutaneous involvement usually presents as an advanced disease and has a poor prognosis.⁶ Treatment of patients with cutaneous involvement of HL is according to dissemination of disease (systemic or localized therapy). Most existing data are based on individual case reports or literature reviews.

Here we describe a case of HL that relapsed with isolated cutaneous involvement two years after completion of his first treatment.

*Corresponding Author:

Ainaz Sourati, MD
Department of Radiation
Oncology, Imam Hossein
Hospital, Shahid Beheshti
University of Medical Sciences,
Tehran, Iran
Tel: 09113335193
Email: ainazsourati@yahoo.com

Although he did not respond to systemic chemotherapy, radiotherapy delivery showed good salvage treatment in this patient with long-term disease-free survival.

Case Report

A 49-year-old man with a history of nodular sclerosis HL presented with cutaneous lesions two years after completion of his treatment. In 2007, he presented for the first time with right solitary axillary lymph node enlargement. After biopsy and histologic examination, as well as staging work up evaluation, he was considered to have stage I (Ann Arbor Classification) nodular sclerosis HL and treated with ABVD regimen chemotherapy. He obtained complete response after eight cycles of chemotherapy. Approximately two years after completion of the treatment, he found two large separate asymptomatic erythematous nodular non-ulcerated cutaneous lesions in his right arm and forearm (Figures 1, 2). These cutaneous lesions began approximately three months prior and did not resolve with medication. He had no B symptoms such as fever, weight loss or night sweats. General physical exam revealed no lymphadenopathy or organomegaly. With the exception of an elevated C-reactive protein, other laboratory tests were within normal range. He underwent a biopsy of the skin lesions suggestive for HL involvement, which was subsequently confirmed by pathologic review and Immunohistochemistry (IHC) results.

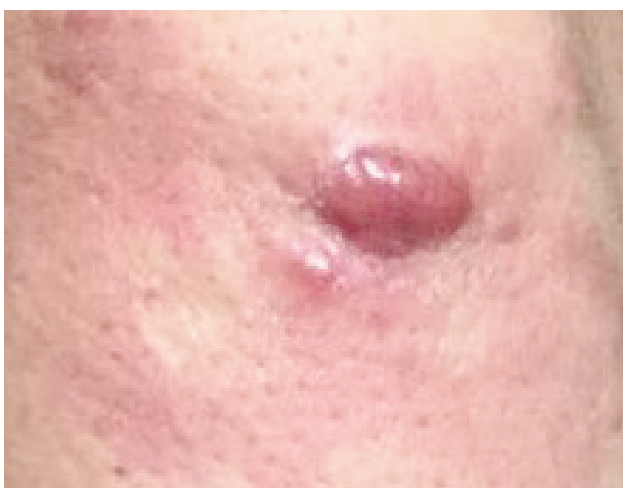

Figure 1. Pretreatment photograph of nodular erythematous skin lesion from the patient's forearm.

Microscopic sections of the skin lesion biopsy showed a dense mononuclear band-like infiltration in the upper dermis with focal mild perivascular lymphocytic infiltration in the deep dermis. IHC panel was positive for CD30 in large atypical cells, CD20 in a few scattered small lymphocytes, CD3 in the majority of infiltrating lymphocytes, and weakly positive for CD4 in some infiltrating lymphocytes, as well as negative for CD15. At this time he referred for neck, thorax, and abdominopelvic CT scans which were unremarkable. Treatment began with the ABVD regimen of chemotherapy. After six cycles of treatment, the skin lesions showed no clinical response, so local therapy was considered for symptomatic disease control at this time. He received radiotherapy delivered with 4 enface fields (2 for the arm and 2 for the forearm lesions) for a total dose of 27 Gy in 18 fractions (24 days) with a 12 MeV electron beam. He showed complete remission three months after radiotherapy completion. The patient was in seen in follow up and at six years considered free from any relapse.

Discussion

Hodgkin's lymphoma is a relatively rare type of cancer which includes approximately 10% of all lymphomas.¹ The most common presentation of HL is painless lymphadenopathy. Most lymphadenopathy is found above the diaphragm. B symptoms are identified in one-third of the patients

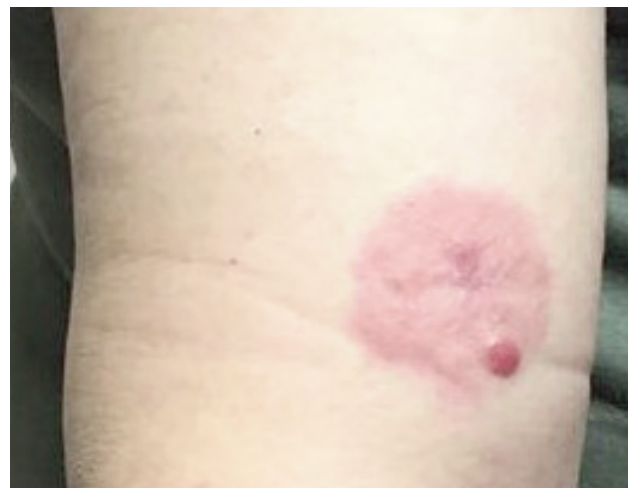


Figure 2. Pretreatment photograph of nodular erythematous skin lesion from the patient's arm.

and include unexplained fever, drenching night sweats, and weight loss. These patients have a poor prognosis.⁷ Extranodal, extralymphatic HL is a rare disease.⁸

Cutaneous lesions associated with HL may occur in 17% to 53% of patients.² They may be a paraneoplastic syndrome presentation like pruritus, hyperpigmentation, urticaria, erythroderma, erythema nodosum, or scaly eruption with hyperkeratosis.⁹ These lesions can also be due to other cutaneous lymph-proliferative disorders such as mycosis fungoides, lymphatoid papulosis, or anaplastic large cell lymphoma that are in differential diagnosis with HL. Finally, another underlying reason for cutaneous lesions associated with HL is involvement with HL,⁹ as with the current case.

Cutaneous HL tends to be in the setting of advanced disease and has a poor prognosis.⁴ Rarely does it primarily involve the skin and often occurs with systemic HL as a secondary cutaneous manifestation.² Our patient had cutaneous involvement as his only relapse presentation.

Cutaneous HL is a rare disease (0.5% to 3.4%). The earliest reported case of a 21-year-old man with lymphadenopathy and several brown-red cutaneous tumors was described by the German physician Grosz in 1906.^{10,11} Since then, other cases have been reported which showed that different features could be found at presentation and include single or multiple, dermal or subcutaneous, or ulcerated or non-ulcerated skin lesions.⁹ The current case has presented with dermal nodules, considered to be the most common presentation in patients with cutaneous HL.¹² The mechanisms for the cutaneous involvement in HL are postulated to be retrograde lymphatic spread from tumor-involved lymph nodes, direct extension into skin by tumor cells in underlying lymph nodes, or hematogenous tumor.¹⁰ Patients suspicious for cutaneous HL need histological (binucleated Reed-Sternberg cells or mononuclear Hodgkin's cells within an inflammatory milieu) and immunohistochemical (CD30, CD15) confirmation.⁹ Pathologic review

of our case revealed mononuclear Hodgkin's cells that were CD 30 positive but CD15 negative, which has variable frequency in HL.^{13,14}

Treatment of patients with cutaneous HL is according to dissemination of the disease (systemic or localized therapy); most data are based on individual case reports or literature reviews. In two case reports, patients with cutaneous HL who presented with advanced stage disease received systemic chemotherapy and had complete response in the cutaneous lesions.^{9,10}

Another case report of a patient who developed cutaneous HL six months after stem cell transplantation for recurrent systemic disease showed that the patient's cutaneous lesions did not respond to radiation therapy. He was considered for donor lymphocyte infusion.⁴

Our case had no response to systemic chemotherapy but obtained a complete remission with radiation therapy. In respect to localized involvement without systemic disease, he had long-term disease-free survival.

Conclusion

This case of cutaneous HL, in contrast to most reported cases, demonstrated a good response to radiotherapy and had long-term disease-free survival. Radiotherapy might be considered as promising salvage treatment in patients with cutaneous HL.

Conflict of interest

No conflict of interest is declared.

References

1. Introcaso CE, Kantor J, Porter DL, Junkins-Hopkins JM. Cutaneous Hodgkin's disease. *J Am Acad Dermatol.* 2008;58(2):295-8.
2. Rubenstein M, Duvic M. Cutaneous manifestations of Hodgkin's disease. *Int J Dermatol.* 2006;45(3):251-6.
3. Hsia CC, Howson-Jan K, Rizkalla KS. Hodgkin lymphoma with cutaneous involvement. *Dermatol Online J.* 2009;15(5):5.
4. Fernandez-Flores A. The early reports on cutaneous involvement by Hodgkin lymphoma. *Am J Dermatopathol.* 2009;31(8):853-4.
5. Dhull AK, Soni A, Kaushal V. Hodgkin's lymphoma with cutaneous involvement. *BMJ Case Rep.*

- 2012;2012. pii: bcr2012007599.
6. Perifanis V, Sfikas G, Tziomalos K, Sotiriadis D, Garipidou V. Skin involvement in Hodgkin's disease. *Cancer Invest.* 2006;24(4):401-3.
 7. Dinand V, Malik A, Unni R, Arya LS, Pandey RM, Dawar R. Unfavorable outcome in CD15 negative pediatric classical Hodgkin lymphoma. *Pediatr Blood Cancer.* 2008;50(2):280-3.
 8. Maeda L, Hoppe R, Warnke R, Natkunam Y, Rosenberg S, Horning S, et al. Prognostic significance of CD15 expression in classical Hodgkin lymphoma (cHL): The Stanford University experience. *J Clin Oncol.* 2010;28(suppl 15):e18521.