

GLUT1 Expression in Oral Squamous Cell Carcinoma and Its Significance

Aayisha Neloufar Mohamed Haneef*, MDS, Sivakumar Gopalakrishnan**,***, MDS, Vijayashree Priyadharsini Jayaseelan***, PhD, Raghini Ramamurthi**, MDS, Sivakumar Muniapillai**, MDS

*Department of Oral and Maxillofacial Pathology, Madha Dental College and Hospital, Kundrathur, Chennai, Tamil Nadu, India

**Department of Oral Pathology, Madha Dental College, Chennai, India

***Centre for Cellular and Molecular Research, Saveetha Dental College and Hospital, Saveetha Institute of Medical and Technical Sciences [SIMATS], Saveetha University, Chennai, India

Please cite this article as:
Mohamed Haneef AN, Gopalakrishnan S, Jayaseelan VP, Ramamurthi R, Muniapillai S. GLUT1 expression in oral squamous cell carcinoma and its significance. Middle East J Cancer. 2024;15(3):189-98. doi:10.30476/mejc.2023.99243.1935.

Abstract

Background: GLUT1, a glucose transport protein, exhibits heightened expression in malignant cells, leading to increased glucose absorption. The detection of GLUT1 through immunohistochemical methods in these cancerous cells suggests elevated rates of cell proliferation, heightened energy requirements, and a more aggressive nature. The influence of GLUT1 on prognosis and its utility as a biomarker may manifest as tumour hypoxia and adaptive upregulation of anaerobic glycolysis, promoting tumour cell survival. Thus, GLUT1 may be considered a negative prognostic biomarker in patients with squamous cell carcinoma. We aimed to evaluate the expression of GLUT1 in typical and oral squamous cell carcinoma (OSCC) cases at different clinical stages and histopathological grades to ascertain its role as a prognostic marker.

Method: A case-control study was conducted with a sample size of $n = 25$, comprising 20 biopsy specimens from OSCC patients and 5 from regular patients. Demographic patient details were recorded. Microscopically confirmed OSCC cases were selected, and immunohistochemical staining was performed using a GLUT1 antibody.

Results: Significant expression and increased staining intensity and percentage of GLUT1 were observed in OSCC cases across different histological grades of OSCC. No significant expression was found in typical cases.

Conclusion: This study concludes that GLUT1 expression can be a biomarker for the early stages of OSCC. Elevated expression of this marker signifies the heightened energy demand of cancer cells for increased proliferation and division under hypoxic conditions. Further studies with larger sample sizes are essential to validate the clinical potential of GLUT1 as a prognostic marker for assessing the risk and prognosis of OSCC.

Keywords: GLUT1, Immunohistochemistry, Squamous cell carcinoma of head and neck, Prognosis

♦Corresponding Author:
Sivakumar Gopalakrishnan,
MDS
Department of Oral Pathology,
Madha Dental College,
Chennai, India
E-mail: gsivaden@yahoo.com



Introduction

Globally, oral cancer is ranked eighth in terms of cancer incidence, although its ranking varies across different geographic regions. In India, it holds the third position, accounting for over 30% of all malignancies.¹ This rapid increase in oral cancer cases has become a concerning health issue in the country. The northeastern part of India is particularly affected, primarily due to the prevalent habit of chewing paan, which typically contains lime, catechu, cinnamon, betel leaves, and areca nuts. In addition to tobacco,² other contributing factors to oral cancer include various forms of tobacco consumption such as smokeless tobacco and smoking, betel quid chewing, alcohol consumption (which acts synergistically), poor oral hygiene, a diet lacking proper nutrition, and viral infections such as Epstein-Barr virus and human papillomavirus.³ The low-income group is at a higher risk as they are more exposed to multiple risk factors and often experience malnourishment, which further exacerbates the risk.⁴

GLUTs comprise 12 membrane-spanning regions located intracellularly with amino and carboxyl terminals. Based on the multiple sequence alignment studies, subclasses of facilitative transporters have been recognized. Facilitative glucose transporters (GLUTs) are the ones that transverse glucose through the plasma membrane by facilitated diffusion. The three

Table 1. Age representation in OSCC cases

OSCC		
Age (Years)	N	20
	Mean	54
	Standard deviation	10
	Median	58
	Confidence interval	58.3

OSCC: Oral squamous cell carcinoma

subclasses are Class I - GLUT-, 2, 3 and 4, Class II - GLUT-5, 7, 9 and 11, Class III - GLUT-6, 8, 10, 12 and 13.⁴ SLC2A1 encodes for GLUT1 facilitating the basal-level cellular uptake of glucose in several tissues.⁵ It is expressed in the endometrium, trophoctodermal cells, and the inner cell cluster, thus helping in embryo implantation under the control of estrogen and progesterone. GLUT1 plays a crucial role in maternal-placental and placenta-fetal glucose diffusion in syncytiotrophoblastic cells and the trophoblastic layer. In adults, energy is provided to red blood cells and the brain via GLUT1; glucose transport appears at the basal state in muscle and fat tissue.^{2,5} GLUT1 is seen in the plasma membrane and intercellular in the endoplasmic reticulum, vacuolar pathway, peroxisome, cytoplasm, and nucleus.⁶ Various mechanisms and several transcription factors mediate the expression of GLUT1. In hypoxic conditions, hypoxia-inducible factors promote the expression of GLUT1 and c-Myc, and the uncontrolled Ras pathway regulates GLUT1 expression in many cancers.

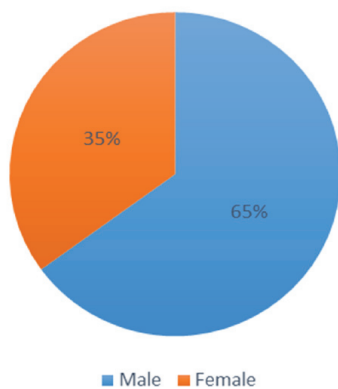


Figure 1. This figure represents the gender distribution of OSCC, with 65% of males and 35% of females affected by OSCC.

OSCC: Oral squamous cell carcinoma

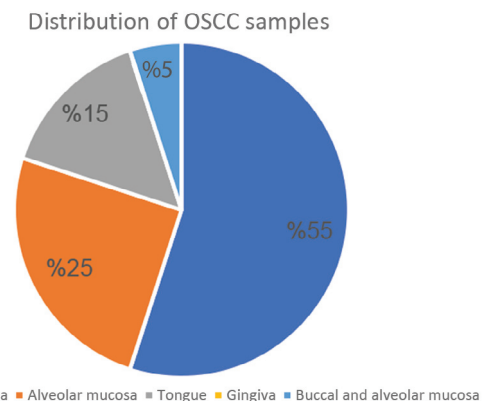


Figure 2. This graph depicts the distribution of OSCC sites, with 55% involving buccal mucosa, while other areas have a lower percentage of involvement.

OSCC: Oral squamous cell carcinoma

Table 2. Gender distribution frequency in OSCC

Gender	N	N%
Male	13	65%
Female	7	35%
Total	20	100%

OSCC: Oral squamous cell carcinoma

PI3K/Akt pathway is initiated by growth factors aggravating the functions of GLUT1 by boosting membrane diffusion. This mechanism is renowned for playing a significant role in regulating the proliferation and growth of normal cells, but in cancers, it is highly mutated.⁷

Expression of GLUT1 prior treatment in oral squamous cell carcinoma (OSCC) patients acts as a potential biomarker of radio-resistance. When an expression is higher, it correlates with poor response to radiation and a decreased survival rate. The reason for the resistance to radio and chemotherapy is the presence of hypoxia in tumours. The tumours associated with the hypoxic activity are highly capable of metastasis. Therefore, analysis of hypoxia prior to treatment may be beneficial for foreseeing the disease outcome and may guide the creation of a proper treatment plan.⁸

This study aimed to assess the expression of the GLUT1 marker in OSCC and normal oral mucous membranes.

Table 3. Sample distribution site frequency in OSCC

Site	N	N%
Buccal mucosa	11	55%
Alveolar ridge	5	25%
Tongue	3	15%
Buccal and alveolar mucosa	1	5%
Total	20	100%

OSCC: Oral squamous cell carcinoma

Materials and Methods

The case-control study examined 20 biopsies of patient tissues affected by OSCC and five healthy mucosal tissues. The study received due approval from the Institutional Ethical Board at Madha Dental College (No.: MDCH/IEC/2019/12, dated 25.7.2019), and the samples were collected with informed consent in both English and Tamil languages from patients reporting to the department of Oral and Maxillofacial Pathology at Madha Dental College. The samples were processed and histopathologically confirmed using routine eosin and hematoxylin stains (Figure 1).

Immunohistochemistry (IHC) analysis was conducted on OSCC samples and positive controls to evaluate GLUT1 expression. The primary antibody utilized was the rabbit monoclonal antibody GLUT1-EP141. The Polyexcel HRP/DAB system served as the secondary antibody for the IHC staining.

A brown stain in the respective areas determined positive reactivity for the target antigen. The evaluation of staining involved assessing stain localization, the percentage of

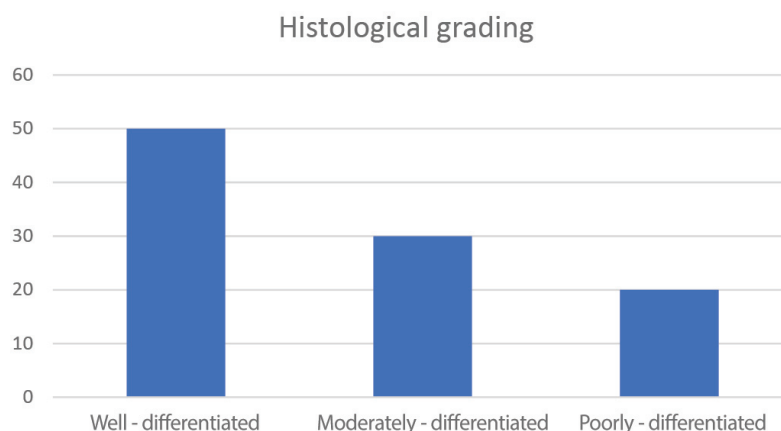


Figure 3. This figure shows the histological grading frequency in the OSCC group, where 50% of OSCC cases were well-differentiated, 30% were moderately-differentiated, and 20% were poorly-differentiated.

OSCC: Oral squamous cell carcinoma

Table 4. Histological grading frequency in OSCC and control groups

Histology grading	Groups						
	OSCC		Control		Total		P-value
	N	%	N	%	N	%	
Well-differentiated OSCC	10	50	0	0	10	40	<0.001
Moderately-differentiated OSCC	6	30	0	0	6	24	
Poorly-differentiated OSCC	4	20	0	0	4	16	

OSCC: Oral squamous cell carcinoma

staining, and the intensity of GLUT1 expression. Based on the percentage of GLUT1 expression, scores were assigned as follows: "-" indicating the absence of staining, "1" for less than 25% staining, "2" for 25%-60% staining, and "3" for more than 60% of GLUT1 immuno expression. Regarding the intensity of expression, scores were given as follows: "-" indicating the absence of staining, "+" for weak intensity, "++" for intermediate intensity, and "+++" for solid intensity.

Results

The chi-square test was employed to compare proportions between groups, while Fisher's exact test was used in cases where any cell frequency fell below 5. Data analysis was done using SPSS (IBM SPSS Statistics for Windows, Version 26.0, Armonk, NY: IBM Corp. Released 2019), with a fixed % significance level set at 5% ($P = 0.05$).

Table 1 presents the mean and median ages in years and the standard deviation for patients with OSCC. The mean age for OSCC patients is 54

years, with a median of 58 years. Table 2 indicates that 65% of OSCC cases are male, while 35% are female.

Figure 1 illustrates the gender distribution among OSCC cases, with 65% male and 35% female. Table 3 displays the frequency of sample sites within the OSCC groups, showing that buccal mucosa, alveolar ridge, tongue, gingiva, and vestibule account for 55%, 25%, 15%, 0%, and 5%, respectively. Figure 2 graphically depicts the site distribution in OSCC, with 55% primarily involving the buccal mucosa, while other areas have lower percentages.

Table 4 reveals the frequency of histological grading in OSCC, with 50% categorized as well-differentiated, 30% as moderately-differentiated, and 20% as poorly-differentiated. Figure 3 presents a similar breakdown of histological grading in the OSCC group, indicating that 50% are well-differentiated, 30% are moderately-differentiated, and 20% are poorly-differentiated.

Table 5 demonstrates that 88% of cases are GLUT1 positive, with 100% positivity in OSCC

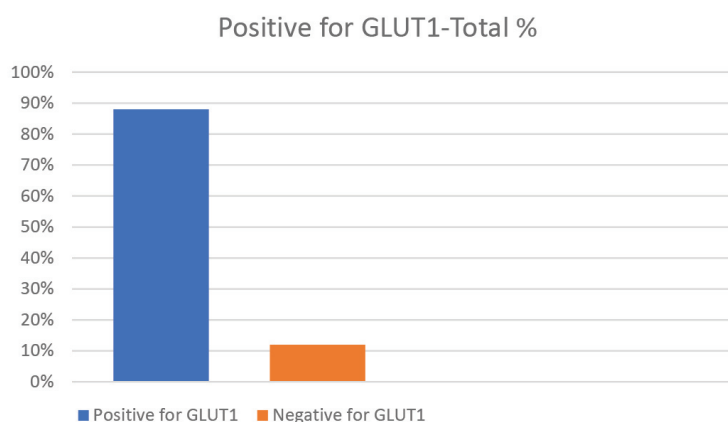


Figure 4. This figure displays the percentage of positive cases for GLUT1, with 88% showing positivity in both OSCC and control groups, while 12% in the control group exhibit negative frequency. OSCC: Oral squamous cell carcinoma

Table 5. GLUT1 positive percentage frequency

Positive for GLUT1	Groups						P-value
	OSCC		Control		Total		
	N	%	N	%	N	%	
Positive for GLUT1	20	100	2	40%	22	88%	<0.001
Negative for GLUT1	0	0	3	60%	3	12%	
Total	20	100	5	100	25	100	

OSCC: Oral squamous cell carcinoma

cases and 40% in the standard group. Conversely, 12% are negative, with 60% showing negativity in the control cases. Figure 4 depicts the frequency of positive GLUT1 cases among the 88% positivity, encompassing both OSCC and control groups, while 12% in the control group exhibit negative staining.

Table 6 outlines the percentage of staining, with less than 25% seen in 20% of control cases, 25%-60% staining in 24% of cases, and more than 60% staining in 56% of overall cases and 70% in OSCC cases. The frequency of staining percentage demonstrates significance in OSCC cases. Figure 5 represents the percentage of staining in OSCC and control groups. In the control group, 100% show less than 25% staining, whereas in OSCC cases, 30% exhibit more than 25%-60% staining, and 70% display more than 60% staining.

Table 7 reveals that 40% of well-differentiated OSCC cases exhibit 25%-60% staining, while 60% show more than 60%. In moderately-

differentiated OSCC, 33.30% show 25%-60% staining, and 66.70% display more than 60% staining. All poorly-differentiated OSCC cases (100%) show more than 60% staining.

Table 8 showcases the frequency of staining intensity in OSCC and control groups, with 20% having vigorous intensity, 32% intermediate, and 48% weak.

Table 9 indicates that 50% of well-differentiated OSCC cases exhibit weak intensity, while the remaining 50% show intermediate intensity. In moderately-differentiated OSCC, 16.7% exhibit weak intensity, 33.3% have intermediate intensity, and 50% have vigorous intensity. Poorly-differentiated OSCC shows 25% with weak intensity, 25% with intermediate intensity, and 50% with solid intensity. Figure 6 represents the frequency of staining intensity in OSCC and control groups, indicating that 35% of OSCC cases exhibit weak intensity, 40% exhibit intermediate intensity, and 25% exhibit vigorous intensity. Among the control group, 100% of

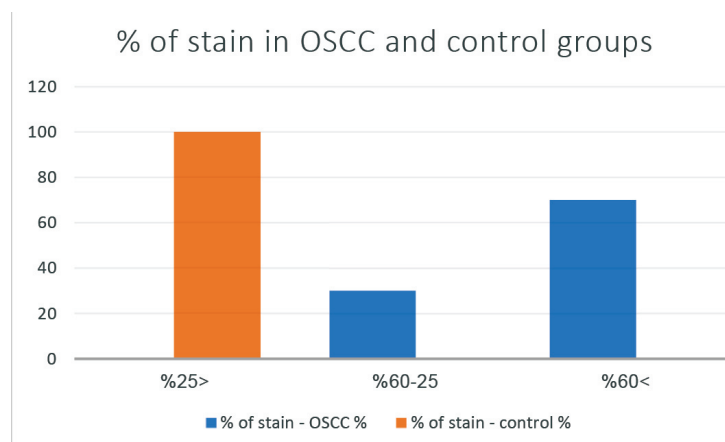


Figure 5. This figure represents the percentage of staining in OSCC and control groups. In the control group, 100% showed less than 25% staining, whereas, in the case of OSCC, 30% of cases showed more than 25%-60% staining and 70% of cases showed more than 60% staining.

OSCC: Oral squamous cell carcinoma

Table 6. Staining percentage frequency in OSCC and control groups

% of stain	Groups						
	OSCC		Control		Total		P-value
	N	%	N	%	N	%	
<25%	0	0	5	100	5	20	<0.001
25-60%	6	30	0	0	6	24	
>60%	14	70	0	0	14	56	
Total	20	100	5	100	25	100	

OSCC: Oral squamous cell carcinoma

cases exhibit weak staining intensity.

Table 10 details the frequency of stain localization in the cell, with 24% showing membrane staining, 56% displaying membrane and cytoplasm staining, 8% showing membrane, cytoplasmic, and nuclear staining, and 12% showing no staining. Figure 7 depicts the frequency of stain localization among OSCC and control groups, with 56% displaying membrane and cytoplasmic staining, 8% showing membrane staining, cytoplasmic, and nuclear staining, and 24% having positive membrane staining, while 12% show no staining.

Table 11 reports that 30% of cases exhibit membrane staining, and 70% display membrane and cytoplasmic staining in well-differentiated OSCC. In moderately-differentiated OSCC, 16.75% exhibit membrane staining, 66% have membrane and cytoplasmic staining, and 16.7% display membrane, cytoplasmic, and nuclear staining. In poorly-differentiated OSCC, 75% exhibit membrane and cytoplasmic staining, and

25% display membrane, cytoplasmic, and nuclear staining.

Discussion

Evaluation of GLUT1 expression in normal oral mucosa and OSCC in the study, encompassing various histopathological grades, shedding light on its prognostic role in OSCC cases. The study comprised 20 OSCC cases, 50% being well-differentiated, 30% moderately-differentiated, and 20% poorly-differentiated. Additionally, it included 5 control cases representing normal oral mucosa. In the OSCC group, the mean age was 54 years, comprising 13 male and 7 female patients among the 20 OSCC cases, possibly due to an increased prevalence of tobacco-related habits in males compared to females. The distribution of OSCC samples in this study was as follows: 55% in the buccal mucosa, 25% in the alveolar ridge, 15% in the tongue, and 5% in the vestibule, with none found in the gingiva.

In the study, 100% of OSCC cases exhibited

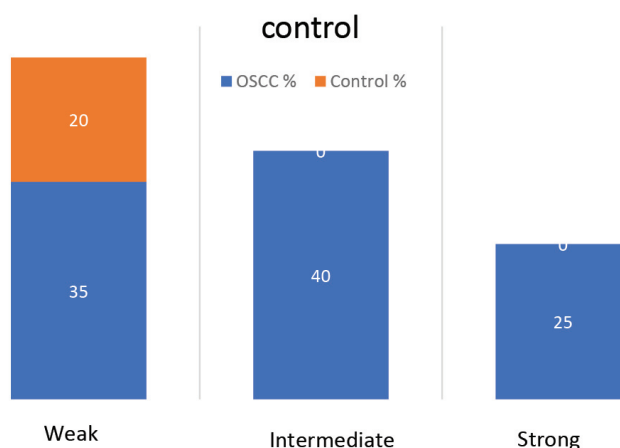


Figure 6. This figure presents the frequency of stain intensity in OSCC and control groups, indicating that 35% of OSCC cases exhibit weak intensity, 40% exhibit intermediate intensity, and 25% exhibit vigorous intensity of staining. Among the control group, 100% of cases exhibit weak staining intensity.

OSCC: Oral squamous cell carcinoma

Table 7. Stain percentage frequency in different OSCC grades and normal tissues

% of stain	Histological grading										P-value
	Control		Grade I		Grade II		Grade III		Total		
	N	%	N	%	N	%	N	%	N	%	
<25%	5	100	0	0	0	0	0	0	5	20%	<0.001
25-60%	0	0	4	40%	2	33.30%	0	0	6	24%	
>60%	0	0	6	60%	4	66.70%	4	100	14	56%	
Total	5	100%	10	100%	6	100%	4	100%	25	100%	

OSCC: Oral squamous cell carcinoma

positive GLUT1 expression in the membrane, cytoplasm, and nucleus. Contrarily, only 40% of control group cases displayed positive staining solely in the basal layer with membranous characteristics. This observation aligns well with studies by Angadi et al. and Tian et al.^{9,10} Tian et al. reported that 18 out of 19 cases exhibited GLUT1 positivity, indicative of cells with heightened energy requirements, aggressive behaviour, and proliferative tendencies.¹⁰ Harshani JM et al. noticed membranous GLUT1 localization in the basal layers of normal mucosa, with reduced or absent staining in superficial layers.¹¹ This suggests that cells in the basement membrane undergo mitosis and division, necessitating more energy than normal cells. Thus, GLUT1 is linked to cells with elevated energy needs.

Stain intensity and percentage were evaluated, revealing <25% in 20% of control group cases, 25%-60% staining in 24% of cases, and >60% in 56% of overall cases and 70% of OSCC cases. Stain intensity in OSCC and the control group demonstrated vigorous intensity in 20%, intermediate intensity in 32%, weak intensity in

32%, and absence in 16%. Evaluation according to OSCC histological grading showed that 50% of well-differentiated cases exhibited weak intensity and 50% intermediate intensity staining. In moderately-differentiated OSCC, 16.7% displayed weak intensity, 33.3% intermediate, and 50% vigorous staining intensity. For poorly-differentiated OSCC, 25% exhibited weak intensity, 25% intermediate, and 50% intense intensity staining. These findings correlate with Harshani JM et al.'s observations of staining intensity scores.¹¹

In the study, 24% of cases exhibited membrane staining, 56% displayed membrane and cytoplasm staining, 8% exhibited membrane cytoplasmic and nuclear staining, and 12% showed none.

Correspondingly, the findings matched those of Jyotsna M Harshani et al., Panda A et al., and Ayala FR et al.¹¹⁻¹³ Ayala FR et al. reported 68 out of 135 cases demonstrating membrane localization and 67 of 135 cases displaying nuclear localization. Nuclear localization indicates a poor prognosis. Importantly, GLUT1 plays a vital role not only in glucose transport but also in various

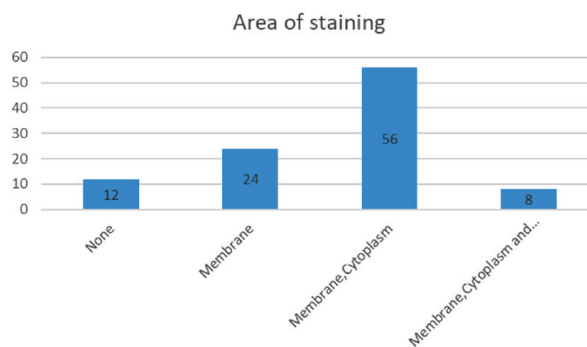


Figure 7. Frequency of stain localization in OSCC and control groups: 56% of cases exhibit membrane and cytoplasmic staining, 8% exhibit staining in the membrane, cytoplasm, and nucleus, and 24% exhibit membrane staining, while 12% show no staining. OSCC: Oral squamous cell carcinoma

Table 8. Stain intensity frequency in OSCC and control groups

Intensity of stain	Group						P-value
	OSCC		Control		Total		
	N	%	N	%	N	%	
Weak	7	35	5	100	12	48	<0.001
Intermediate	8	40	0	0	8	32	
Strong	5	25	0	0	5	20	
Total	20	100	5	100	25	100	

OSCC: Oral squamous cell carcinoma

cellular processes.¹³

The study included 20 cases of OSCC, among which 10 were well-differentiated, 6 moderately-differentiated, and 4 poorly-differentiated, showing a correlation between increased grading and staining intensity. This contradicts the study of Qamar S et al., which concluded that GLUT1 expression increases in lower tumour grades.¹⁴ Interestingly, the study revealed GLUT1 overexpression in OSCC, linked to histopathological grade but not smoking. Among 60 confirmed cases graded by the 2010 WHO system, 52 tested positive for GLUT1: 32 were well-differentiated, 18 moderately-differentiated, and 2 poorly-differentiated cases. Only 1 out of 8 negative cases had a positive correlation with smoking.^{15,16}

The study underscores that the mean age of OSCC cases is 54 years, skewed towards males. Buccal mucosa emerged as the most common site for OSCC occurrences.

All OSCC cases (100%) demonstrated GLUT1 positivity, attributed to increased proliferative activity and energy demand, whereas 40% of control cases showed positive staining in the basal layer. Staining intensity and immune localization exhibited a progressive increase with grading. In well-differentiated OSCC, 50% displayed weak intensity and 50% intermediate, with localization being membranous in 30% and membrane-

cytoplasmic in 70%. In moderately-differentiated OSCC, 16.7% exhibited weak intensity, 33.3% intermediate, 50% vigorous intensity, and corresponding localization patterns. In poorly-differentiated OSCC, 25% exhibited weak, 25% intermediate, and 50% vigorous intensity, with staining localization patterns mirroring intensity. These results are statistically significant, implying increased intensity and immune reactivity correlating with tumour aggressiveness and poor patient prognosis. Findings suggest that GLUT1 expression could be a biomarker for early-stage OSCC. Elevated GLUT1 expression underscores the heightened energy needs of cancer cells, especially under hypoxic conditions.¹⁷

The tumour cells' significant intensity and increased immune reactivity may reveal the tumour's aggressiveness and poor prognosis. Recent studies on GLUT1-targeting drugs have shown promise in enhancing prognosis and survival rates.¹⁸ However, further research with larger sample sizes is required to establish GLUT1's clinical potential as a prognostic marker for assessing OSCC risk and prognosis

Conclusion

The study concludes by stating that the expression of GLUT1 can serve as a biomarker for the early detection of OSCC. The higher expression of this marker signifies increased

Table 9. Stain intensity frequency in different histological OSCC grades

Intensity of stain	Histology grading										P-value
	Control		Grade I		Grade II		Grade III		Total		
	N	%	N	%	N	%	N	%	N	%	
Weak	5	100.0	5	50.0	1	16.7	1	25.0	9	48.0	0.007
Intermediate	0	0	5	50.0	2	33.3	1	25.0	8	32.0	
Strong	0	0	0	0	3	50.0	2	50.0	5	20.0	
Total	5	100.0	10	100.0	6	100.0	4	100.0	25	100.0	

OSCC: Oral squamous cell carcinoma

Table 10. Staining localization frequency in cells

Area of staining	Group						P-value
	OSCC		Control		Total		
	N	%	N	%	N	%	
None	0	0	3	100	3	12	<0.001
Membranous	6	27.3	2	0	6	24	
Membrane, cytoplasmic	14	63.6	0	0	14	56	
Membrane, cytoplasmic, nuclear	2	9.1	0	0	2	8	
Total	22	100	3	100	25	100	

OSCC: Oral squamous cell carcinoma

proliferation and division under hypoxic conditions.

Conflict of Interest

None declared.

References

- Marur S, Forastiere AA. Head and neck squamous cell carcinoma: Update on epidemiology, diagnosis, and treatment. *Mayo Clin Proc.* 2016;91(3):386-96. doi: 10.1016/j.mayocp.2015.12.017.
- Singh M, Prasad CP, Singh TD, Kumar L. Cancer research in India: Challenges & opportunities. *Indian J Med Res.* 2018;148(4):362-5. doi: 10.4103/ijmr.IJMR_1711_18.
- Rivera C, González-Arriagada WA, Loyola-Brambilla M, de Almeida OP, Coletta RD, Venegas B. Clinicopathological and immunohistochemical evaluation of oral and oropharyngeal squamous cell carcinoma in Chilean population. *Int J Clin Exp Pathol.* 2014;7(9):5968-77.
- Deng D, Xu C, Sun P, Wu J, Yan C, Hu M, et al. Crystal structure of the human glucose transporter GLUT1. *Nature.* 2014;510(7503):121-5. doi: 10.1038/nature13306.
- Botha H, Farah CS, Koo K, Cirillo N, McCullough M, Paolini R, et al. The role of glucose transporters in oral squamous cell carcinoma. *Biomolecules.* 2021;11(8):1070. doi: 10.3390/biom11081070.
- Johnson DE, Burtness B, Leemans CR, Lui VWY, Bauman JE, Grandis JR. Head and neck squamous cell carcinoma. *Nat Rev Dis Primers.* 2020;6(1):92. doi: 10.1038/s41572-020-00224-3. Erratum in: *Nat Rev Dis Primers.* 2023;9(1):4.
- Riaz N, Morris LG, Lee W, Chan TA. Unraveling the molecular genetics of head and neck cancer through genome-wide approaches. *Genes Dis.* 2014;1(1):75-86. doi: 10.1016/j.gendis.2014.07.002.
- Mohan M, Jagannathan N. Oral field cancerization: an update on current concepts. *Oncol Rev.* 2014;8(1):244. doi: 10.4081/oncol.2014.244.
- Angadi VC, Angadi PV. GLUT-1 immunoeexpression in oral epithelial dysplasia, oral squamous cell carcinoma, and verrucous carcinoma. *J Oral Sci.* 2015;57(2):115-22. doi: 10.2334/josnusd.57.115.
- Tian M, Zhang H, Nakasone Y, Mogi K, Endo K. Expression of Glut-1 and Glut-3 in untreated oral squamous cell carcinoma compared with FDG accumulation in a PET study. *Eur J Nucl Med Mol Imaging.* 2004;31(1):5-12. doi: 10.1007/s00259-003-1316-9.
- Harshani JM, Yeluri S, Guttikonda VR. Glut-1 as a prognostic biomarker in oral squamous cell carcinoma. *J Oral Maxillofac Pathol.* 2014;18(3):372-8. doi: 10.4103/0973-029X.151318.
- Panda A, Bandyopadhyay A, Mohiddin G, Raghuvanshi M, Sahoo SK, Bhuyan L. Can increased metabolic status be a grading tool for oral squamous cell carcinoma? A glucose transporter 1 immunoeexpression study. *Niger J Surg.* 2019;25(2):203-7. doi: 10.4103/njs.NJS_17_18.
- Ayala FR, Rocha RM, Carvalho KC, Carvalho AL, Cunha IW, LourenÁo SV, et al. GLUT1 and GLUT3 as potential prognostic markers for oral squamous cell carcinoma. *Molecules.* 2010;15(4):2374-87.

Table 11. Staining localization frequency in different histological OSCC grades

Area of staining	Histology grading										P-value
	Control		Grade I		Grade II		Grade III		Total		
	N	%	N	%	N	%	N	%	N	%	
None	3	60	0	0	0	0	0	0	3	12	0.009
Membrane	2	40	3	30	1	16.7	0	0	6	24	
Membrane, cytoplasm	0	0	7	70	4	66.7	3	75	14	56	
Membrane, cytoplasm, nucleus	0	0	0	0	1	16.7	1	25	2	8	
Total	5	100	10	100	6	100	4	100	25	100	

OSCC: Oral squamous cell carcinoma

14. Qamar S, Fatima S, Rehman A, Khokhar MA, Mustafa Z, Awan N. Glucose transporter 1 overexpression in oral squamous cell carcinoma. *J Coll Physicians Surg Pak.* 2019;29(8):724-7. doi: 10.29271/jcpsp.2019.08.724.
15. Azad N, Kumari Maurya M, Kar M, Goel MM, Singh AK, Sagar M, et al. Expression of GLUT-1 in oral squamous cell carcinoma in tobacco and non-tobacco users. *J Oral Biol Craniofac Res.* 2016;6(1):24-30. doi: 10.1016/j.jobcr.2015.12.006.
16. Lizák B, Szarka A, Kim Y, Choi KS, Németh CE, Marcolongo P, et al. Glucose transport and transporters in the endomembranes. *Int J Mol Sci.* 2019;20(23):5898. doi: 10.3390/ijms20235898.
17. Burstein DE, Nagi C, Kohtz DS, Lumerman H, Wang BY. Immunohistochemical detection of GLUT1, p63 and phosphorylated histone H1 in head and neck squamous intraepithelial neoplasia: evidence for aberrations in hypoxia-related, cell cycle-and stem-cell-regulatory pathways. *Histopathology.* 2006;48(6):708-16.
18. Pliszka M, Szablewski L. Glucose transporters as a target for anticancer therapy. *Cancers (Basel).* 2021;13(16):4184. doi: 10.3390/cancers13164184.