

## Case report

Middle East Journal of Cancer; October 2017; 8(4): 233-239

# Congenital Giant Melanocytic Nevus with Malignant Melanoma of the Pleura: Do Primary Pleural Melanomas Exist?

Brijesh Sharma\*\*, Desh Deepak\*, Mohammed Ali\*, Mahender Singh Rajput\*, Rajni Parmar\*\*, Rajesh Taneja\*

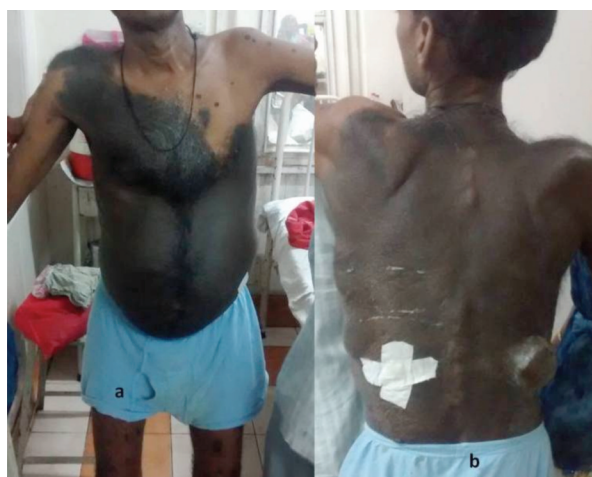\*Dr. Ram Manohar Lohia Hospital, Post-graduate Institute of Medical Education and Research, New Delhi, India

\*\*Division of Histopathology, Oncquest Laboratories, New Delhi, India

## Abstract

Cases of primary pleural and bronchial melanoma have been described in the literature in the absence of melanocytic cells in the pleura and bronchi. We described a case of congenital giant melanocytic nevus that had a presentation suggestive of primary pleural melanoma. However, biopsy of a chest wall lesion confirmed the presence of another melanoma deposit in a subcutaneous swelling concealed within the congenital giant melanocytic nevus. Histopathology with immunohistochemistry results showed that the pleural and chest wall swelling were similar. The difficult clinical detection of the primary tumor contributes to the fact that 24% of cases of congenital giant melanocytic nevus receive a diagnosis of metastatic melanoma without identification of the primary site. We propose that it is probable that the entity “primary pleural melanoma” may, in fact, not exist. Instead, all such reported tumors in the pleura may actually be metastatic from an unknown, regressed, or missed primary site.

**Keywords:** Giant congenital pigmented nevus, Melanoma, Pleural neoplasms, Neoplasm metastasis, Immunohistochemistry



**Figure 1.** (a) Congenital giant melanocytic nevus (CGMN) over the trunk. (b) Subcutaneous swelling within CGMN on the chest wall (right side).

### Corresponding Author:

Brijesh Sharma, MD  
H-314 Ajnara Pride Apartments  
Sector 4B Vasundhara  
Ghaziabad -201012, UP, India  
Tel: 91-9013262275  
Email: brijsushma@gmail.com

## Introduction

Congenital giant melanocytic nevus (CGMN) is a rare disorder present in 1 in 20000 live births.<sup>1</sup> The lifetime risk of developing malignant melanoma in patients with CGMN is 5% to 10%. Melanoma has been reported at the cutaneous as well as extracutaneous sites. Other tumors such as lipomas, schwannomas, sarcomas, and undifferentiated spindle cell neoplasms may also occur. Cases of primary pleural and bronchial melanoma have been described in the literature though there are no melanocytic cells present in the pleura and bronchi.<sup>2</sup> We have described a case of CGMN who developed pleural effusion. The patient was initially treated as a tubercular pleural effusion, however he had ascites and a nodular mass that arose from the mediastinal pleura. There was a swelling in the chest wall diagnosed as metastatic melanoma, and similar to the pleural mass according to histopathology and immunohistochemistry (IHC) results. The patient received a diagnosis of pleural and chest wall metastatic malignant melanoma with an unknown primary.

## Case report

A 40-year-old man presented with slowly worsening chest pain, breathlessness, and back pain for 4 months. Pleural effusion presented two weeks into the illness. Pleural fluid analysis was done and the patient received anti-tubercular drugs and corticosteroids. However, his symptoms worsened. In addition to the pleural effusion, he also developed progressive abdominal distension and swelling of the feet. A few weeks later, he presented to our office.

The most remarkable feature on examination was a large plaque-like lesion with uniform black pigmentation over the chest and anterior abdominal wall that extended to the back, genital area, and upper thighs. The margins of this lesion were well-defined. The surface was slightly irregular with sparse hair growth over the area. Multiple satellite lesions of a similar morphology of variable sizes were scattered throughout his body (Figure 1a). The pigmented lesion had been present from birth. The patient denied any history

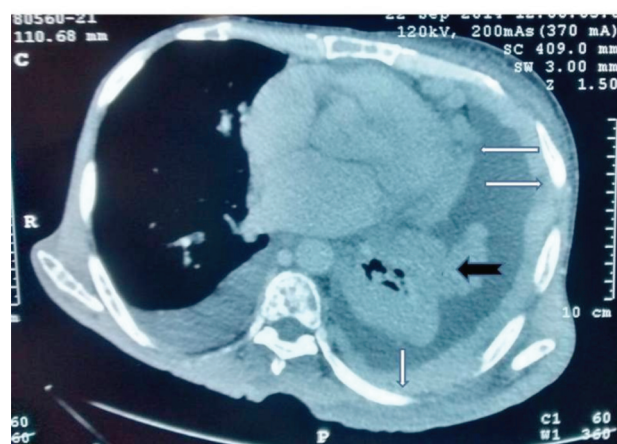
of increase in size, pain or ulceration of the lesion.

On the lateral aspect of the right lower chest wall, in the midst of this pigmented area, was a firm, non-tender swollen area (5×5 cm) with an irregular surface (Figure 1b), fixed to the underlying tissue. According to the patient, the swelling in the right lower chest wall had been present for a long period of time with no recent change.

The patient had ill-localized tenderness in the lumbar spine. On examination of the respiratory system, breath sounds were absent in the left hemithorax and stony-dull on percussion. Breath sounds were also absent in the right infrascapular and infra-axillary areas with stony dull note on percussion. There was a shifting dullness in the abdomen. There was no organomegaly, nor any cervical, axillary, or inguinal lymphadenopathy. Cardiovascular and central nervous systems were normal. Digital rectal examination was unremarkable.

He had a hemoglobin level of 6.2 g/dl and peripheral smear showed a normocytic normochromic picture. The iron profile suggested anemia from chronic disease and an ESR of 2 mm. Renal functions, liver functions, and urinary analysis were normal.

Pleural and ascitic fluids were hemorrhagic. The pleural fluid had 40-45 white cells, of which 60% were mononuclear cells and the rest polymorphs. The protein level was 3.1 g/dl. In the



**Figure 2.** Chest contrast-enhanced computed tomography (CT) shows bilateral pleural effusion and circumferential pleural thickening (thin white arrows) in addition to a lobulated pleural mass with partial collapsed lung (black notched arrow).

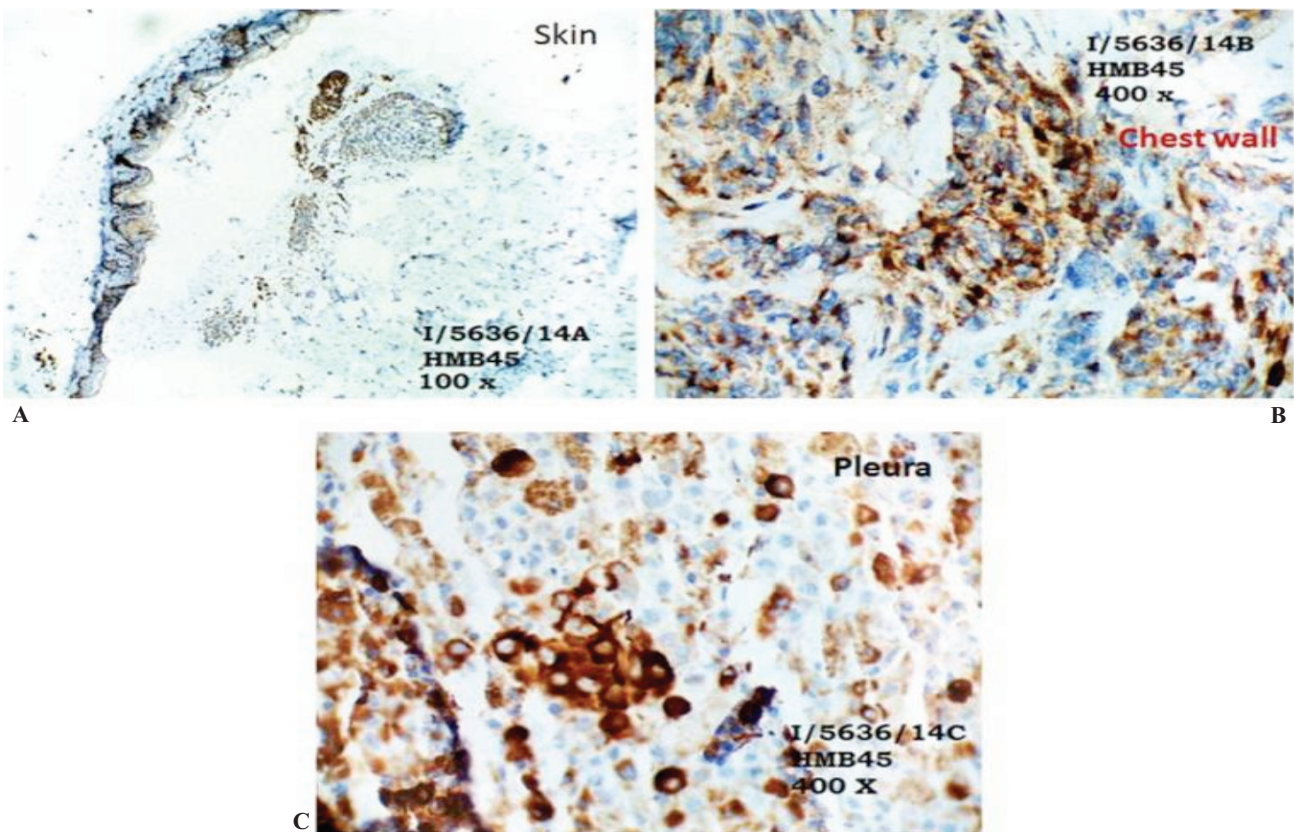
ascitic fluid, there were 300 cells, from which 60% were mononuclear cells. Ascitic fluid protein was 4.2 g/dl. The ascitic and pleural fluids tested negative for malignant cells.

He underwent an ultrasound of the abdomen and chest, which showed a thick multiseptate collection with pleural thickening on the left side of the chest. A contrast-enhanced computed tomography (CT) of the chest, abdomen, and pelvis showed evidence of a circumferential nodular enhanced thickening of the pleura on the left side with extension as a lobulated mass (74×69 mm) that arose from the mediastinal pleura. There was bilateral moderate-to-gross pleural effusion (left>right) with underlying partial collapse of his left lung (Figure 2). The abdomen had evidence of nodular peritoneal thickening with enhancement, mainly in the pelvis. The left adrenal gland was bulky (12.5×22.8 mm) and suggestive of possible metastasis. Gross, free fluid was present in the peritoneal cavity. On the posterolateral aspect of the right side of the chest,

there was a soft tissue subcutaneous lesion (68×40 mm) that showed homogenous enhancement. Diffuse lytic lesions were seen in both humeri, all vertebrae, scapulae, pelvic bones, and both femoral heads.

At this stage, the patient had a diagnosis of CGMN and a mass that arose from the mediastinal pleura with circumferential thickening of the pleura. The patient underwent a pleural biopsy and a biopsy from the edge and center of the CGMN. The pleural biopsy tissue was jet black in color. We reassessed the patient and reviewed the CT findings. Therefore, we thought that the swelling in the right lower chest wall might be important despite its lengthy history and no change. He underwent a punch biopsy of this swelling. A naked eye examination of the tissue from the right lower chest wall swelling showed that it was also jet black in color.

Sections of skin lesion (center and edge) showed nodules and masses of spindle cells that contained melanin pigment in their cytoplasm



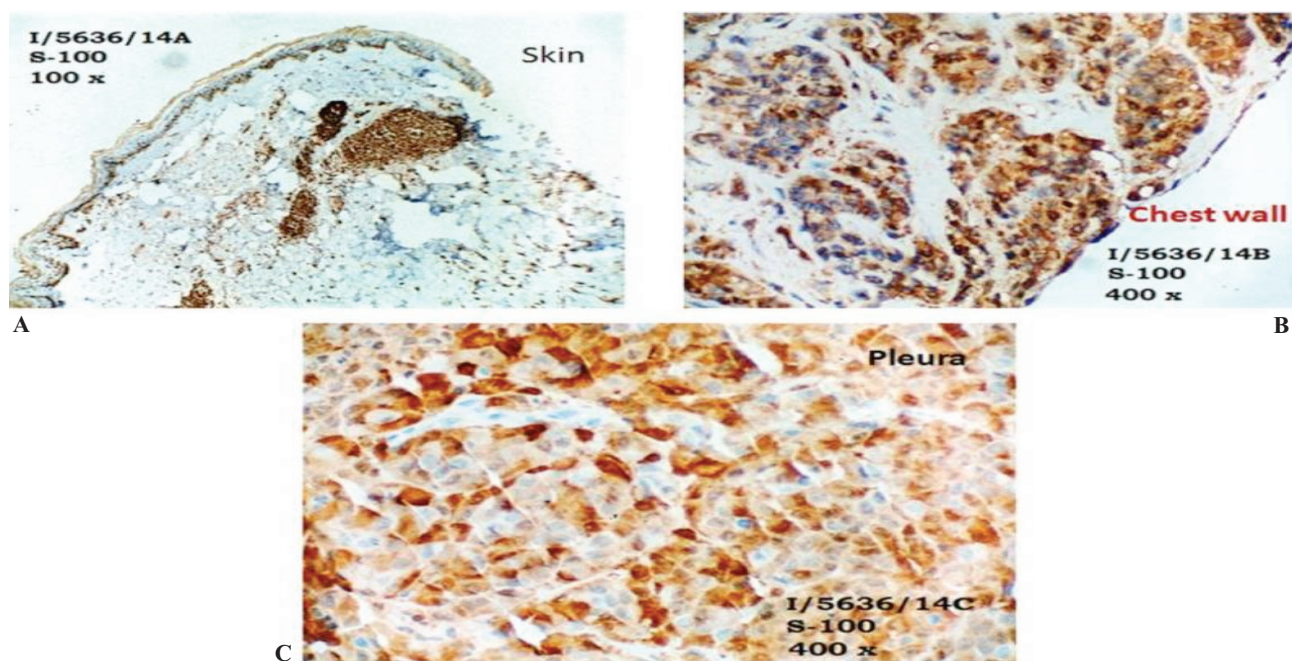
**Figure 3.** Immunohistochemistry (IHC) analysis: HMB-45 negative in the skin biopsy (A, 100×) and positive in the chest wall swelling (B, 400×) and pleural biopsy (C, 400×).

located in the mid and deep dermis areas with extension close to the dermal adnexae as well as between collagen fibers in the deep areas. Sections of the pleural biopsy and chest wall swelling punch biopsy showed masses and clusters of pleomorphic polygonal cells surrounded by hyalinized collagenous tissue. There were oval to irregular large dark nuclei and ill-defined scanty cytoplasm. The nucleoli were not visible. Immunohistochemistry analysis of the biopsies from the pleural and chest wall swelling were positive for HMB-45 (Figure 3), S100 (Figure 4), and Ki-67 (Figure 5) antigens. However, the skin biopsy was positive for HMB-45 (Figure 3) and S100 (Figure 4) in a few cells. The diagnosis of malignant melanoma for the chest wall swelling and pleural mass with systemic metastases was made along with CGMN in the skin.

The patient was managed symptomatically. However, his general condition deteriorated during the hospital stay and he developed sepsis. He received broad spectrum antibiotics, fluids, and supportive care. Once the diagnosis was established, a referral to an oncology center was planned. However, the patient succumbed to the disease shortly after his diagnosis.

## Discussion

As per the American National Institute of Health (NIH) consensus definition, a giant nevus is defined as having a diameter of 20 cm or more.<sup>1</sup> The common site is the lower back and thigh area. Large numbers of smaller nevi may be present elsewhere on the skin (satellite nevi) in up to 74% of cases.<sup>3</sup> Malignant melanoma is a cancer of the melanocyte-melanin-containing cells in the basal layer of the epidermis. In CGMN, the risk of melanoma is increased if the nevus is over the trunk and associated with many satellite nevi.<sup>3</sup> Krengel et al. performed a review of 6571 patients with CGMN who were followed for a mean period of 3.4-23.7 years. They noted that 46 (0.7%) patients developed 49 melanomas. The mean age at diagnosis of the melanoma was 15.5 years (median: 7 years). Primary melanomas arose inside the nevi in 33 of 49 cases (67%). In 7 (14%), there was metastatic melanoma with an unknown primary. In 4 (8%) cases, the melanoma developed at an extracutaneous site.<sup>4</sup> Of note, in CGMN patients, the melanoma might not only arise from the skin, but also from other sites such as the eyes, mucosa, gastrointestinal tract, genitourinary tract, and leptomeninges.



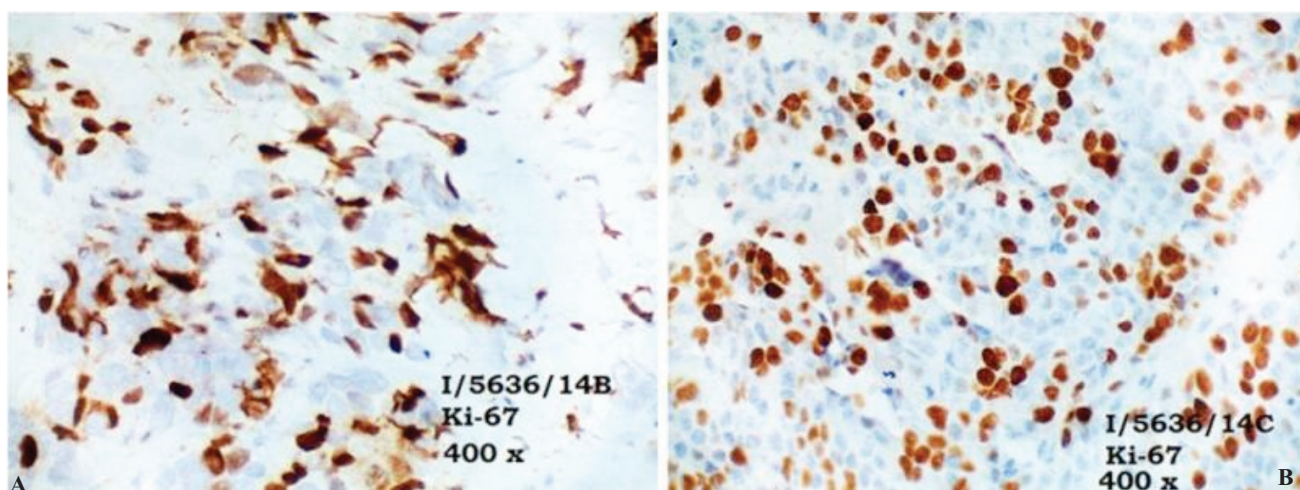
**Figure 4.** Immunohistochemistry (IHC) analysis: S100 negative in the skin biopsy (A, 100 $\times$ ), and positive in the chest wall swelling (B, 400 $\times$ ) and pleural biopsy (C, 400 $\times$ ).

Although pleura and bronchi do not contain melanocytes, a few cases of primary pleural and bronchial melanoma have been reported.<sup>2,5-8</sup> In our patient, in view of the diagnosis of CGMN with pleural effusion and circumferentially thickened pleura, as well as a large mass that arose from the mediastinal pleura, the possibility of malignant pleural effusion with a possible primary in the pleura associated with secondary spread to the bones, adrenal, and peritoneum existed. Criteria have been propounded to diagnose primary bronchial and pleural melanoma with the essential factor that no other primary site should be discernible. Hence, some authors call these “apparently primary” pleural or bronchial melanoma.<sup>6</sup> Consequently, we have attempted to discern other possible sites for the melanoma. Along with a biopsy from the pleura, we also biopsied the center and edge of the CGMN. We found a swollen area within the giant nevus located in right lower chest wall. According to the patient, this swelling had been present for a long time without any change. We performed a punch biopsy from this swollen area. Naked eye examination of the punch biopsy from the chest wall swelling and pleura showed they were black in color and had a similar appearance.

The IHC markers used to identify melanoma cells include HMB-45, Melan-A, and S100. However, Ki-67 is a sensitive IHC marker of proliferation which differentiates between

malignant melanoma and benign nevus. In benign nevus, less than 5% of cells stain positive for Ki-67, while in malignant melanomas more than 30% of the cells are positive.<sup>9</sup> Studies have shown a correlation of Ki-67 with poor patient survival and metastatic potential.<sup>10</sup> In our case, more than 60% of the cells from the pleura and chest wall swelling tested positive for Ki-67, whereas less than 1% of cells from the skin lesion expressed Ki-67. HMB-45 and S-100 were also equally positive in pleura and chest wall swelling. Both histopathology and IHC findings confirmed the suspicion that both were malignant melanoma. Although studies indicate that Bcl2, Ki-67, and Melan-A have greater expression at the metastatic site, no IHC markers can conclusively differentiate between primary and metastatic melanoma.<sup>12</sup>

Proposed criteria for primary occurrence of melanoma in the lung are as follows: no previously resected pigmented skin lesion, no removed or otherwise ocular tumor, and no evidence of a current or previous primary melanoma in any other organ. The tumor in the surgical specimen from the lung should be solitary; tumor morphology should be consistent with malignant melanoma that involves the respiratory epithelium along with junctional change and invasion of intact bronchial mucosa by malignant melanoma cells. Full necropsy should demonstrate the absence of a primary malignant melanoma at any other location.<sup>13</sup> While there are no histological



**Figure 5.** Immunohistochemistry (IHC) analysis: Ki-67 positive in the chest wall swelling (A, 400×) and pleural biopsy (B, 400×).

characteristics for diagnostic separation of primary melanoma of the skin and cutaneous melanomatous metastasis, IHC markers such as Ki-67 express more in metastatic lesions.<sup>14</sup> In the current case, more than 60% of cells in both the subcutaneous swelling and pleura were Ki-67 positive. Thus, based on histopathology and IHC, it was clear that both lesions were malignant melanoma. As we found a skin lesion which was malignant melanoma, the large pleural mass was a metastatic deposit and not a primary lesion as per the criteria proposed earlier. Had we not biopsied the chest wall lesion and compared both histopathologic and IHC analyses with the pleural mass, we might have presumed the pleural mass to be the primary lesion.

We propose that since:

(a) There are no melanocytic cells in the lungs and pleura.

(b) The literature does not mention any clear-cut differentiating features between a primary lung/pleural melanoma and a metastatic deposit.

(c) The pathogenesis of primary pleural/bronchial melanomas, as in the aforementioned case-reports,<sup>2,5-8</sup> were largely speculative - squamous metaplasia, originated from melanoblasts, and involvement of pleura by cutaneous nevus cells via the lymphatics.

(d) The possibility that a malignant bronchial lung/pleural melanoma is a metastasis of a regressed skin melanoma. Malignant melanomas are known to regress spontaneously and yet metastasize.<sup>15</sup>

(e) A premalignant dissemination of a melanocyte can occur from a cutaneous melanoma. Secondaries in such cases may pre-date the development of a primary tumor.<sup>16</sup>

(f) In contrast to the normal development pattern of melanomas, those that occur within congenital nevi might arise from below the dermoepidermal junction (as was true in our case) in approximately two-thirds of cases. They usually occur in the dermis or deeper layers, which might delay the diagnosis.<sup>17,18</sup>

(g) A skin primary may be missed on clinical examination as the overlying CGMN lesion is

thick, nodular, rough, and full of rugosities.

It is probable that a “primary pleural melanoma” may, in fact, not exist at all. Instead, all such reported tumors in the pleura may actually have metastasized from an unknown, regressed, or missed primary site. We propose that before diagnosing any pleural mass as a primary melanoma, IHC should be performed to differentiate between a metastatic and a primary site. The finding should be compared with other metastatic deposits and if both are similar, then both lesions should be diagnosed as metastases from an unknown primary.

In the current case, although the swollen area right lateral chest wall was present for an extended period of time, we did not initially suspect it to be malignant as there was no increase in size or ulceration. However, because of its large size, this swelling could not remain concealed within CGMN. Had it not been biopsied, the patient might have been diagnosed with primary pleural melanoma.

When melanoma arises in CGMN, the prognosis is especially dismal. The factor that may contribute to the severity of the disease is the great extent of the lesions, which causes lymphatic drainage by multiple channels. Early metastases occurs when the tumor is present in deeper layers of the nevus.<sup>1</sup>

The difficult clinical detection of the primary tumor contributes to the fact that in 24% of cases, melanoma will already be metastatic at the time of diagnosis without identification of the primary site.<sup>18</sup>

## Conclusion

In the setting of CGMN any pleural involvement should be investigated for metastatic disease from a primary melanoma. In all patients with CGMN, the skin lesion should be repeatedly examined for early diagnosis of a primary cutaneous melanoma and subcutaneous metastatic deposits as they may be missed on superficial examination. Accessible metastatic deposits should be submitted for histopathology with IHC and compared with the pleural mass to demonstrate

similarities and differences before declaring the pleural lesion to be a primary melanoma. Finally, the reported cases of apparent primary pleural melanoma may all be metastatic with unknown primary sites. Primary sites should be assiduously searched for in all cases.

### Conflict of Interest

No conflict of interest is declared.

### References

- Viana AC, Gontijo B, Bittencourt FV. Giant congenital melanocytic nevus. *An Bras Dermatol*. 2013;88(6):863-78.
- Cheng L, Nie J, Li J, Wang J, Jiang K. Primary pleural malignant melanoma with rapid progression. *Ann Thorac Surg*. 2014;98(1):334-6.
- Ruiz-Maldonado R, Tamayo L, Laterza AM, Durán C. Giant pigmented nevi: clinical, histopathologic, and therapeutic considerations. *J Pediatr*. 1992;120(6):906-11.
- Krengel S, Hauschild A, Schäfer T. Melanoma risk in congenital melanocytic naevi: a systematic review. *Br J Dermatol*. 2006;155(1):1-8.
- Filosso PL, Donati G, Ruffini E, Croce S, Papotti M, Oliaro A, et al. Primary malignant melanoma of the bronchus intermedius. *J Thorac Cardiovasc Surg*. 2003;126(4):1215-7.
- Um SW, Yoo CG, Lee CT, Han SK, Shim YS, Kim YW. Apparent primary pleural melanoma: case report and literature review. *Respir Med*. 2003;97(5):586-7.
- Shameem M, Akhtar J, Baneen U, Khan NA, Bhargava R, Ahmed Z, et al. Malignant melanoma presenting as an isolated pleural effusion. *Monaldi Arch Chest Dis*. 2011;75(2):138-40.
- Wang Q, Chen J, Dassarith M, Yin Z, Yang X, Yang K, et al. Primary malignant melanoma of the pleura with rapid progression: A case report and literature review. *Oncol Lett*. 2015;9(6):2713-5.
- Compton LA, Murphy GF, Lian CG. Diagnostic Immunohistochemistry in Cutaneous Neoplasia: An Update. *Dermatopathology (Basel)*. 2015;2(1):15-42.
- Nasr MR, El-Zammar O. Comparison of pHH3, Ki-67, and survivin immunoreactivity in benign and malignant melanocytic lesions. *Am J Dermatopathol*. 2008;30(2):117-22.
- Witold Kyrcer, Sylwia Grodecka-Gazdecka. Prognostic factors in melanoma. *Rep Pract Oncol Radiother*. 2006;11(1):39-48.
- Plaza JA, Suster D, Perez-Montiel D. Expression of immunohistochemical markers in primary and metastatic malignant melanoma: a comparative study in 70 patients using a tissue microarray technique. *Appl Immunohistochem Mol Morphol*. 2007;15(4):421-5.
- Allen MS Jr, Drash EC. Primary melanoma of the lung. *Cancer*. 1968;21(1):154-9.
- Guerriere-Kovach PM, Hunt EL, Patterson JW, Glembocki DJ, English JC 3rd, Wick MR. Primary melanoma of the skin and cutaneous melanomatous metastases: comparative histologic features and immunophenotypes. *Am J Clin Pathol*. 2004;122(1):70-7.
- Littman CD. Metastatic melanoma mimicking primary bronchial melanoma. *Histopathology*. 1991;18(6):561-3.
- Damsky WE, Rosenbaum LE, Bosenberg M. Decoding melanoma metastasis. *Cancers (Basel)*. 2010;3(1):126-63.
- Ribeiro CS, Serpa SS, Sousa MA, Jeunon T. Melanoma associated with congenital intermediate common blue nevus of the scalp - Case report. *An Bras Dermatol*. 2016;91(4):514-6.
- Marghoob AA, Schoenbach SP, Kopf AW, Orlov SJ, Nossa R, Bart RS. Large congenital melanocytic nevi and the risk for the development of malignant melanoma. A prospective study. *Arch Dermatol*. 1996;132(2):170-5.