

A Case of Unilateral Proptosis: What is Your Diagnosis?

Mahdi Shahriari*, Fazl Saleh

Amir Oncology Hospital, Shiraz University of Medical Sciences, Shiraz, Iran

Case Question

A five-year-old boy developed proptosis of the left eye (Figure 1) for which he was referred to an ophthalmologist. An orbital CT scan was performed (Figures 2 and 3). What is your differential diagnosis?

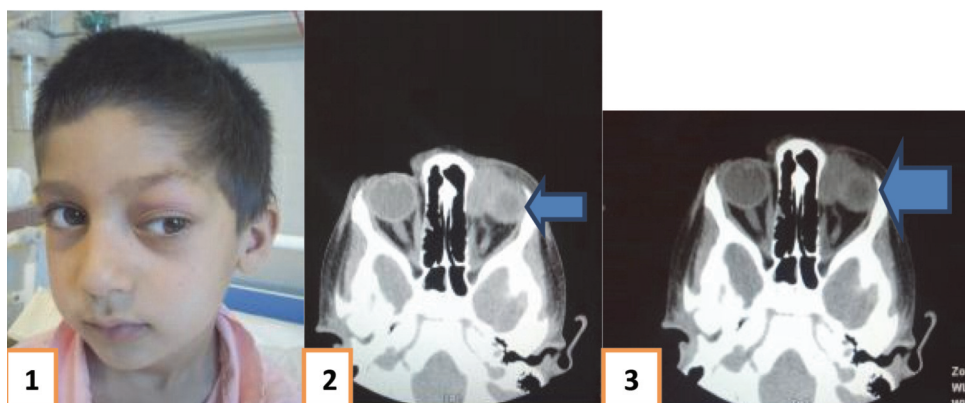


Figure 1. The patient at presentation with unilateral proptosis.

Figure 2. Orbital CT scan of the patient, arrow shows the position of the mass in the orbital cavity.

Figure 3. Another cut of orbital CT scan, arrow illustrates the position of the mass.

♦Corresponding Author:

Mahdi Shahriari, MD
Amir Oncology Hospital,
Shiraz University of Medical
Sciences, Shiraz, Iran
Tel: +989177104358
Email: shahryar@sums.ac.ir

Answer

A Case of Acute Myeloid Leukemia (AML-M4) with Chloroma; Presenting as Unilateral Proptosis.

Case Presentation

A five-year-old boy was referred to an ophthalmologist due to unilateral proptosis. With the impression of rhabdomyosarcoma, an orbital CT-scan was performed. A large mass with central necrosis or hemorrhage was seen in the parietal aspect of the left orbit plus soft tissue swelling. He was sent for a hematology-oncology consultation and referred to Amir Oncology Hospital. The physical exam was unremarkable with the exception of pallor, fever and proptosis of the left eye. Laboratory workups were as follows: Hb: 9 g/dl; WBC: 5600/mm³; platelets: 125,000/mm³; ESR: 120; and LDH: 1020 mg/dl. Bilateral bone marrow (BM) aspiration and biopsy was performed to investigate for BM involvement (Figure 4). Acute myelomonocytic leukemia (AML M4) was diagnosed and confirmed by flow cytometry. Chemotherapy with the BFM-98 protocol was started with improvement in chloroma of the left eye (Figure 5).

Discussion

Chloroma is defined as infiltration of myeloblasts or monoblasts in soft tissue of the

orbit or skin. The condition, currently known as chloroma, was first described by the British physician A. Burns in 1811,¹ although the term chloroma did not appear until 1853.² This name was derived from the Greek word chloros (green), as these tumors often have a green tint due to the presence of myeloperoxidase. The link between chloroma and acute leukemia was first recognized in 1902 by Dock and Warthin.³ However, because up to 30% of these tumors could be white, gray, or brown rather than green, the more correct term granulocytic sarcoma was proposed by Rappaport in 1967 and became synonymous with the term chloroma.^{4,5}

Exact estimates of the prevalence of chloroma are lacking, but it may be somewhat more common in patients with the following disease features: French-American-British (FAB) classification class M2; specific cytogenetic abnormalities [i.e., t (8;21) or inv (16)]; myeloblasts that express T-cell surface markers, CD13 or CD14; and high peripheral WBC counts. However, even in patients with the above risk factors, chloroma remains an uncommon complication of acute myeloid leukemia.^{6,7}

Rarely, a chloroma can develop as the sole manifestation of relapse after apparently successful treatment of acute myeloid leukemia. Considering the behavior of chloroma, such an event must be regarded as an early sign of a systemic relapse

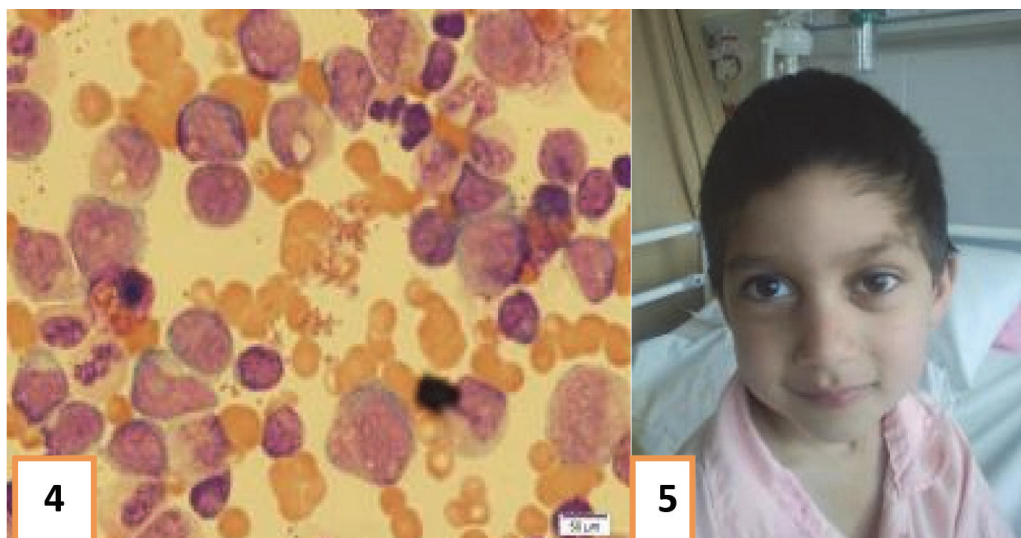


Figure 4. Wright stained bone marrow slide of the patient with many myeloblasts and monoblasts ($\times 1000$).
Figure 5. The patient after induction chemotherapy.

instead of a localized process.

This patient with AML M4 had a large infiltration of the orbital soft tissue which displaced the left orbit due to unilateral proptosis. Although he was investigated for rhabdomyosarcoma, the presence of severe necrosis or hemorrhage in the center of the mass is very uncommon in rhabdomyosarcoma. After the CT scan, hematoma was the first differential diagnosis followed by rhabdomyosarcoma and lymphoma. For rhabdomyosarcoma and lymphoma, a bilateral BM aspiration and biopsy was indicated. Although chloroma is rare,^{8,9} it should be kept in mind for soft tissue infiltrations, such as the current case.

Conflict of Interest

No conflict of interest is declared.

References

1. Patigaroo A, Banday S, Rashid W, Malik F, Patigaroo F, Patigaroo S. Isolated Granulocytic Sarcoma Of Head And Neck Region Without Any Marrow Involvement. *The Internet Journal of Otorhinolaryngology*. 2010;13(2).
2. Ferri E, Minotto C, Ianniello F, Cavaleri S, Armato E, Capuzzo P. Maxillo-ethmoidal chloroma in acute myeloid leukaemia: case report. *Acta Otorhinolaryngol Ital*. 2005;25(3):195-9.
3. Akbaadeh-Pasha A, Siadati S, Shafaei S. Recurrence of primary granulocytic sarcoma as an untreatable Scrotal Ulcer. *Iranian J path*. 2014;9(2):152-5.
4. Bakst RL1, Tallman MS, Douer D, Yahalom J. How I treat extramedullary acute myeloid leukemia. *Blood*. 2011;118(14):3785-93.
5. Byrd JC, Edenfield WJ, Shields DJ, Dawson NA. Extramedullary myeloid cell tumors in acute nonlymphocytic leukemia: a clinical review. *J Clin Oncol*. 1995;13(7):1800-16.
6. Byrd JC, Weiss RB. Recurrent granulocytic sarcoma. An unusual variation of acute myelogenous leukemia associated with 8;21 chromosomal translocation and blast expression of the neural cell adhesion molecule. *Cancer*. 1994;73(8):2107-12.
7. Yamauchi K, Yasuda M. Comparison in treatments of nonleukemic granulocytic sarcoma: report of two cases and a review of 72 cases in the literature. *Cancer*. 2002;94(6):1739-46.
8. Creutzig U, van den Heuvel-Eibrink MM, Gibson B, Dworzak MN, Adachi S, de Bont E, et al. Diagnosis and management of acute myeloid leukemia in children and adolescents: recommendations from an international expert panel. *Blood*. 2012;120(16):3187-205.
9. Campidelli C, Agostinelli C, Stitson R, Pileri SA. Myeloid sarcoma: extramedullary manifestation of myeloid disorders. *Am J Clin Pathol*. 2009;132(3):426-37.