

Case Report

Middle East Journal of Cancer; January 2018; 9(1): 71-75

Vulvar Villoglandular Adenocarcinoma of Colonic Type: A Rare Finding

Heidarali Esmaeili*, Mahzad Azimpouran**, Elaheh Olad-Saheb-Madarek**

*Department of General Pathology, Tabriz University of Medical Sciences, Tabriz, Iran

**Department of Obstetrics and Gynecology, Tabriz University of Medical Sciences, Tabriz, Iran

Abstract

Colonic type villoglandular adenocarcinoma of the lower genital tract is an extremely rare condition. Its origin is not clearly understood; however, the cloacal remnants are the more accepted source for this carcinoma. We report the case of a 67-year-old female patient who presented with a 1.2 cm polypoidal nodule at the right side of the fourchette. Morphologic studies revealed a colonic type mucinous adenocarcinoma that arose from within a villous adenoma. Immunohistochemical staining showed positive cytokeratin 7, cytokeratin 20, carcinoembryonic antigen, P53, and progesterone receptor, but negative for estrogen receptor and caudal type homeobox transcription factor 2. Extensive work-up failed to reveal other primary cancers in this patient. Ultimately, she underwent a radical vulvectomy. No recurrence was seen in eight months follow up of this patient after surgery. Careful, thorough histological evaluation and clinical clues enable correct diagnosis of the rare colonic type vulvar villoglandular adenocarcinoma. Due to rarity of this tumor, its management is questionable. Therefore, additional investigation is necessary for its management.

Keywords: Villoglandular, Adenocarcinoma, Genital, Fourchette, Immunohistochemical

Introduction

Primary vulvar cancer is a rare finding that represents approximately 3%-5% of all gynecological malignancies.¹ Most reported cases occur in individuals over the age of 50 years.¹⁻⁴ While the majority of these vulvar carcinomas are squamous cell carcinoma, other less common types include basal cell carcinoma, melanoma, adenocarcinoma, and

sarcomas.^{1,2} Vulvar adenocarcinoma originates from Bartholin's glands (most common), sweat glands, Skene's glands, minor vestibular glands, aberrant mammary tissue, or endometriotic implants.⁴⁻⁷ Colonic type vulvar villoglandular adenocarcinoma is a rare variant of vulvar adenocarcinoma. Its origin is not clearly understood; however, cloacal remnants are more

Corresponding Author:

Mahzad Azimpouran, MD
Department of General Pathology,
Al-Zahra Gynecology Hospital, Tabriz
University of Medical Sciences,
South Artesh St., Tabriz, Iran
Tel: +989143170513
Fax: +9841 35541221
Email: mahzad.a.ma@gmail.com,
azimpouranm@tbzmed.ac.ir



Received: April 12, 2017; Accepted: July 2, 2017

acceptable.¹⁻³ The presence of an intestinal-type morphology, proven by immunohistochemistry, has resulted in this hypothesis.¹⁻⁴ Its prognosis is worse compared with other vulvar carcinomas, particularly vulvar squamous cell carcinoma.¹⁻⁵ The behavior of this carcinoma is unclear due to its rarity. A follow up of the few previously reported cases has revealed no recurrence after surgical excision.⁷ To the best of our knowledge, very few cases with this diagnosis have been reported.¹⁻⁷ Herein, we discuss a case with this rare presentation.

Case report

A 67-year-old gravida 3 para 3 postmenopausal woman came to our department with complaints of vaginal discharge. She described a vulvar lump with mild discomfort from 9 months prior. Physical examination revealed a 15×15 mm fragile ulcerative exophytic nodule at the right side of the fourchette. Pelvic examination was otherwise unremarkable. She underwent a complete laboratory and clinical workup. Serum carcinoembryonic antigen (CEA), CA19-9 and beta-hCG levels, complete blood count, liver function tests,

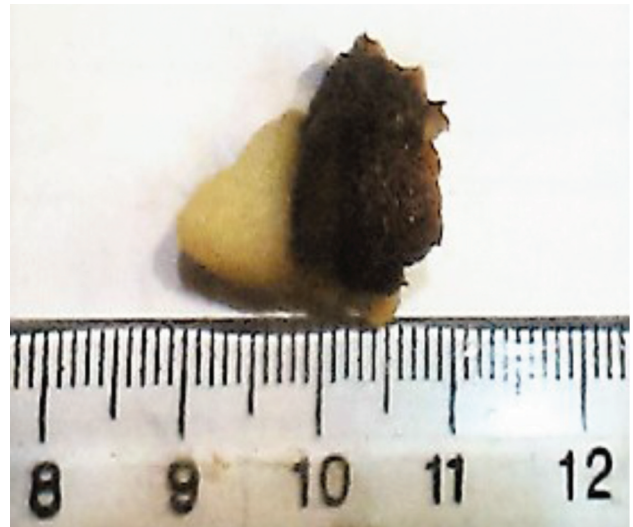


Figure 1. Gross appearance. Anterior view of a 13×11×10 mm brownish, exophytic nodular lesion.

and HIV antibody (p24) were within normal limits. Chest X-ray, mammogram, and abdominal ultrasonography were unremarkable. Pelvic ultrasonography disclosed an echogenic area in the cervical canal that measured 10×5.2 mm. An excisional biopsy was performed. Gross findings of formalin-fixed tissue revealed a 13×11×10 mm brownish exophytic nodular lesion (Figure 1). Microscopic histologic findings showed intra-

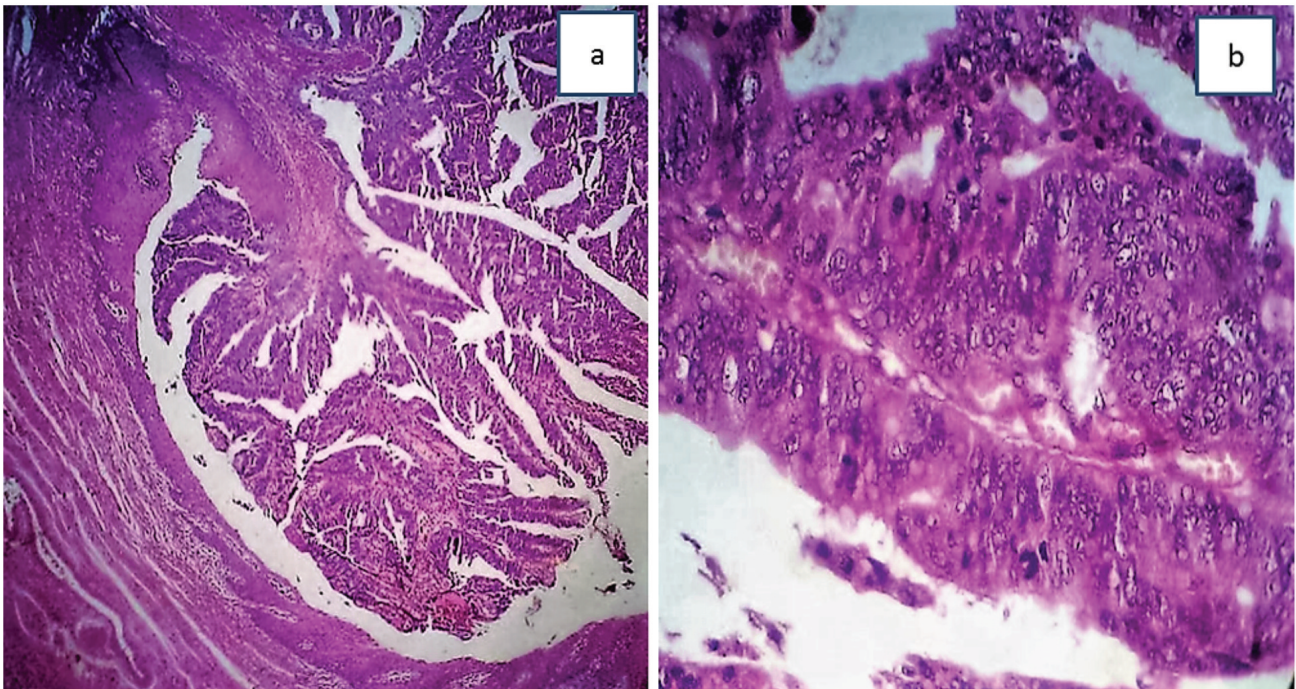


Figure 2. Hematoxylin-eosin staining shows: (a) continuity with the surface epithelium (10×) and (b) well-differentiated adenocarcinoma (40×).

epithelial, neoplastic proliferation of a well-differentiated, villoglandular structure contiguous with the surface epidermis (Figure 2a). Examination of the surface epithelium revealed a colonic type villoglandular adenocarcinoma composed of mucin secreting columnar cells with mild nuclear atypia (Figure 2b). There was no lymphatic or vascular invasion. All surgical margins were free of tumor. On immunohistochemical staining, the neoplastic cells showed diffuse immunoreactivity for cytokeratin (CK)7, CK20, CEA, P53, and progesterone receptor (PR; Figure

3), but negative for estrogen receptor (ER) and caudal type homeobox transcription factor 2 (CDX2; Figure 4). Normal squamous epithelium was positive for ER. The underlying stroma was positive for ER and PR. These results favored colonic type adenocarcinoma. The patient underwent a radical hemivulvectomy, followed by an ipsilateral inguinal lymph node dissection.

Discussion

Villoglandular adenocarcinoma of the vulva is

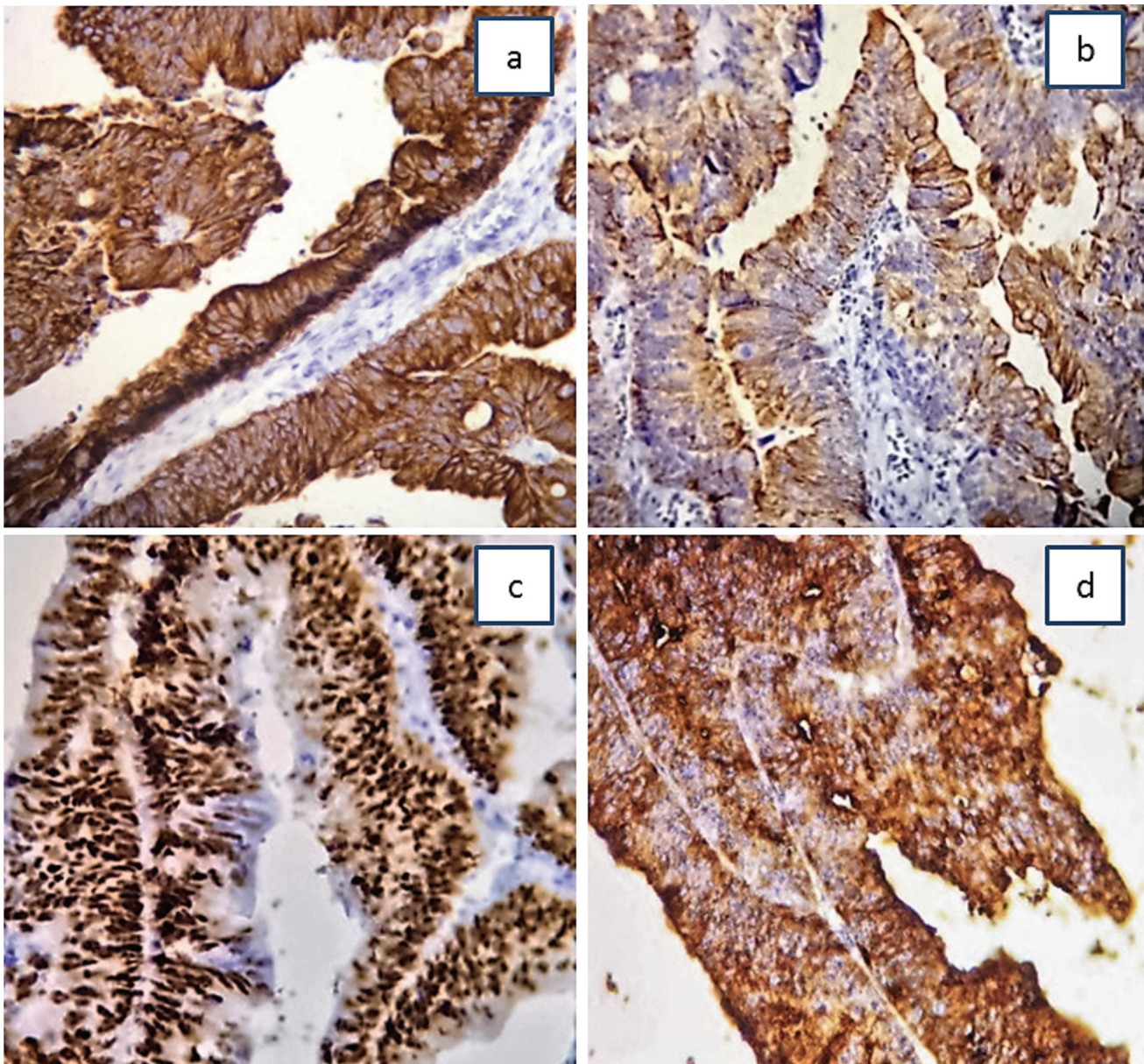


Figure 3. (A) Immunohistochemical strong membrane and cytoplasmic expressions of cytokeratin CK7 in the neoplastic glands. (B) Immunohistochemical cytoplasmic expression of CK20 in the neoplastic glands. (C) Strong, diffuse positive nuclear immunohistochemistry staining for P53. (D) Positive strong cytoplasmic immunohistochemistry staining for carcinoembryogenic antigen (CEA) (Magnification: 40 \times).

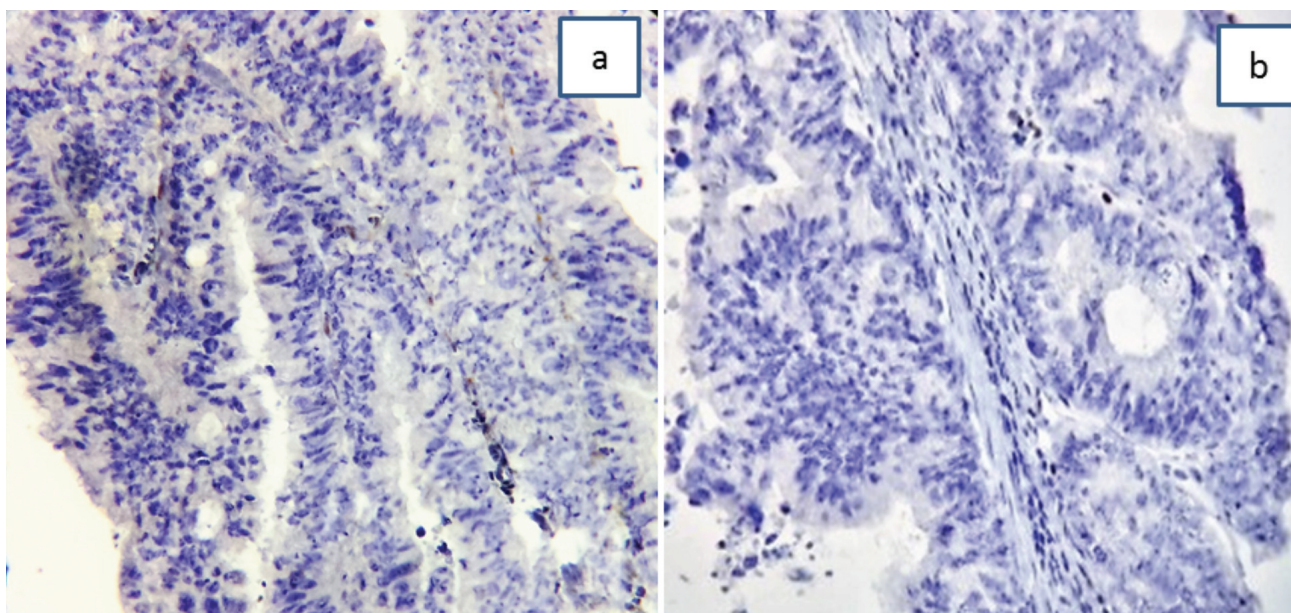


Figure 4. (A) Negative immunohistochemical staining for estrogen receptor (ER) at 40× magnification. (B) Negative immunohistochemical staining for Caudal type homeobox transcription factor 2 (CDX2).

a very uncommon condition.¹ The colonic type of this neoplasm is extremely rare.¹⁻⁸ Although a complete gastrointestinal examination and positive immunohistochemical staining for CK7 have ruled out the tumor's metastatic probability in the current case, its origin was not well understood. To date, very few similar cases have been reported. Assessment of the morphologic characteristics of these cases revealed a primary villoglandular adenocarcinoma of the mucinous type, with direct continuity of surface epithelium.¹⁻⁴ The majority of these cases showed a polypoid macroscopic appearance and villoglandular microscopic features with occasional goblet cells. Similar to described cases of vulvar intestinal-type adenocarcinomas, our case had a tumor with direct continuity of the epidermis, yet unrelated to the underlying mucous glands.

Although positive staining for CK20 and CEA are seen in colonic cancers, strong positivity for CK7 is characteristic for female genital tract neoplasms.⁸⁻¹⁰ Generally, patients affected by this neoplasm underwent either a radical vulvectomy with unilateral, bilateral inguinofemoral lymphadenectomy,¹¹ unilateral hemivulvectomy with radical groin lymph node dissection, or wide excision of the lesion in case of very small tumors

(<2 cm).¹¹⁻¹³ Considering our limited knowledge of this tumor, we recommend either an ipsilateral or bilateral inguinal lymph node dissection for these patients.

Funding

This research received no specific grant from any funding agency in the public, commercial, or not-for-profit sectors.

Consent

Written informed consent was obtained from the patient for publication of this case report and accompanying images. A copy of the written consent is available for review by the Editor-in-Chief of this journal on request.

Conflicts of interest

No conflict of interest is declared.

References

1. Cormio G, Carriero C, Loizzi V, Gissi F, Leone L, Putignano G, et al. "Intestinal-type" mucinous adenocarcinoma of the vulva: a report of two cases. *Eur J Gynaecol Oncol.* 2012;33(4):433-5.
2. de Hullu JA, van der Avoort IA, Oonk MH, van der Zee AG. Management of vulvar cancers. *Eur J Surg Oncol.* 2006;32(8):825-31.

3. Dube V, Veilleux C, Plante M, Têtu B. Primary villoglandular adenocarcinoma of cloacogenic origin of the vulva. *Hum Pathol.* 2004;35(3):377-9.
4. Kennedy JC, Majmudar B. Primary adenocarcinoma of the vulva, possibly cloacogenic. A report of two cases. *J Reprod Med.* 1993;38(2):113-6.
5. Liu SH, Ho CM, Huang SH, Shih BY, Lee FK. Cloacogenic adenocarcinoma of the vulva presenting as recurrent Bartholin's gland infection. *J Formos Med Assoc.* 2003;102(1):49-51.
6. Loy TS, Calaluce RD, Keeney GL. Cytokeratin immunostaining in differentiating primary ovarian carcinoma from metastatic colonic adenocarcinoma. *Mod Pathol.* 1996;9(11):1040-4.
7. McCluggage WG, Shah R, Connolly LE, McBride HA. Intestinal-type cervical adenocarcinoma *in situ* and adenocarcinoma exhibit a partial enteric immunophenotype with consistent expression of CDX2. *Int J Gynecol Pathol.* 2008;27(1):92-100.
8. Musella A, Marchetti C, Salerno L, Vertechy L, Iadarola R, Pecorella I, et al. An unexpected complete remission of advanced intestinal-type vulvar adenocarcinoma after neoadjuvant chemotherapy: a case report and a literature review. *Case Rep Obstet Gynecol.* 2013;2013:427141.
9. Haidarali E, Vahedi A, Mohajeri Sh, Mostafidi E, Azimpouran M, Naghavi Behzad M. Evaluation of the pathogenesis of tumor development from endometriosis by estrogen receptor, P53 and Bcl-2 immunohistochemical staining. *Asian Pac J Cancer Prev.* 2016;17(12):5247-50.
10. Azimpouran M, Vazifekhah S, Moslemi F, Piri R, Naghavi-Behzad M. Immunohistochemical profile of uterine leiomyomas; a comparison between different subtypes. *Niger Med J.* 2016;57(1):54-8.
11. Rodriguez A, Isaac MA, Hidalgo E, Márquez B, Nogales FF. Villoglandular adenocarcinoma of the vulva. *Gynecol Oncol.* 2001;83(2):409-11.
12. Stehman FB, Bundy BN, Dvoretzky PM, Creasman WT. Early stage I carcinoma of the vulva treated with ipsilateral superficial inguinal lymphadenectomy and modified radical hemivulvectomy: a prospective study of the Gynecologic Oncology Group. *Obstet Gynecol.* 1992;79(4):490-7.
13. Zaidi SN, Conner MG. Primary vulvar adenocarcinoma of cloacogenic origin. *South Med J.* 2001;94(7):744-6.