

Case Report

Middle East Journal of Cancer; October 2018; 9(4): 334-338

Neoadjuvant Chemotherapy of Cervical Squamous Cell Carcinoma during Pregnancy: A Case Report

Malihe Hasanzadeh*, Zohreh Yousefi*, Amir Hosein Jafarian**,
Shohreh Saeed***, Laya Shirinzadeh*, Behrouz Davachi****,
Marjaneh Farazestanian*†

*Department of Obstetrics and Gynecology, Faculty of Medicine, Mashhad University of Medical Sciences, Mashhad, Iran

**Department of Pathology, Faculty of Medicine, Mashhad University of Medical Sciences, Mashhad, Iran

***Gynecologist Oncologist, Fellowship of Gynecology Oncology, Mashhad, Iran

****Department of Radiology, Faculty of Medicine, Mashhad University of Medical Sciences, Mashhad, Iran

Abstract

Squamous cell carcinoma is one of the common malignancies among women, especially in the third and fourth decades of life. Human papillomavirus is the most important cause of squamous cell carcinoma among women worldwide. Early diagnosis and treatment of this carcinoma can prevent disease progression. Herein, we present the case of a pregnant woman with squamous cell carcinoma.

A 35-year-old pregnant woman referred to our clinic for cervical cerclage. During the procedure, the gynecological surgeon observed a suspicious lesion. Accordingly, cervical conization was performed and a squamous cell carcinoma lesion was confirmed by the pathology reports. Neoadjuvant chemotherapy was initiated for the patient during pregnancy. Radical hysterectomy and bilateral lymphadenectomy were conducted toward caesarean section. As the patient was a young fertile woman, the ovaries were saved.

Although chemotherapy is not a standard treatment for cervical cancer in pregnancy, but neoadjuvant chemotherapy followed by radical hysterectomy and bilateral pelvic lymphadenectomy during cesarean section was a successful treatment in our patient.

Keywords: Cervix, Neoadjuvant chemotherapy, Pregnancy, Squamous cell carcinoma

Corresponding Author:

Marjaneh Farazestanian, MD
Department of Obstetrics and
Gynecology, Faculty of
Medicine, Mashhad University
of Medical Sciences, Mashhad,
Iran
Email: farazestanianm@mums.ac.ir

Introduction

Cervical malignancy is one of the three most prevalent cancers during pregnancy with an incidence rate of 4 in every 105 pregnant woman.¹

Squamous cell carcinoma (SCC) is one of the common primary malignancies of the genital system.^{2,3} This malignancy comprises 80%-90% of vaginal cancers,^{3,4} and its

incidence rate is increasing rapidly among the female population worldwide.^{5,6} The related literature suggest factors that may cause SCC, which include human papillomavirus (HPV) viral infection (especially in young women),^{2,3,5} smoking, and certain infections such as Chlamydia trachomatis and Neisseria gonorrhoea.²

Cancer management in pregnant women is challenging and treatment can differ depending on the case.⁷ The occurrence of genital cancers during pregnancy is rare and clinically challenging.⁸⁻¹⁰ The incidence rate of this type of malignancy is a growing trend in women of child-bearing age.⁸ Primary diagnosis during the early stages of disease may prevent surgical intervention,⁵ while delayed diagnosis may lead to tumor progression.

The type of treatment depends on gestational age, histology report, lymph node involvement, and disease stage.^{1,8} There is a scarcity of studies as to clinical management of cervical cancer in pregnant patients,¹ and the effects of SCC on pregnancy sequelae have not been studied.¹⁰ Here, we present the case of a pregnant women with SCC and the performed medical procedures.

Case Report

A 35-year-old female (gravida: 2, abortion: 1) referred to the oncology center of an academic hospital of Mashhad University of Medical Sciences in 2015. She was a candidate for cerclage surgery based on an ultrasound report in the 12th week of pregnancy, which determined the cervical canal length to be 30 mm. During the cerclage procedure, the gynecological surgeon observed a suspicious lesion. Accordingly, cervical biopsy was performed for the patient in the 16th week of pregnancy. The diagnostic pathology of the first biopsy was SCC *in situ*, keratinizing type based on World Health Organization classification without vascular invasion but clinical diagnosis was more than *in situ*.

Cervical examination revealed a small ulcer in the anterior side of the cervix (labeled at 12-2 o'clock). Due to presence of this lesion in the cervical canal, another conization was conducted within the following two weeks. The macroscopic

report revealed an irregular, brownish surface of ectocervix and conization of the uterine cervix that measured 3.5×1.2 cm from the 3 o'clock position of the mucosal canal. The diagnostic pathology report of conization indicated invasive SCC of a large cell non-keratinizing type, with undetermined margins, along with stromal and angiolymphatic invasion. The cells were moderately differentiated and involved all quadrants. There was exo- and endocervical canal involvement. Figure 1 shows the pathology of the tissue obtained by conization.

Further assessments revealed that uterine size was compatible with pregnancy age; blood pressure and laboratory analyses were normal. There were no special diseases or drug use by the patient, and she did not have family history of cancer.

Neoadjuvant chemotherapy with taxol (infusion of 135 mg/m² in 24 h) and cisplatin (75 mg/m² in 24 h) as the T-C regimen was initially administered to the patient in the 25th week of pregnancy. The second cycle was administered 21 days later and the third cycle was given 42 days later. All injections were performed by the rapid intravenous injection method.

Finally, the patient underwent a caesarean section, type II radical hysterectomy, and bilateral pelvic lymphadenectomy in the 36th week of pregnancy. The neonatal Apgar score was 10-10 (for 1 and 5 min). The ovaries were saved during surgery. Frozen section diagnosis of the uterus showed severe dysplasia in the cervix (CIN3) with free vaginal margins and other pathologic pregnancy related changes. The same reports for the right and left pelvic lymph nodes showed reactive and ectopic decidual reactive changes, respectively. Pathology reports of the left ovarian cyst and placenta exhibited simple serous cyst and congestion, respectively. The permanent pathology for all of the tissues was negative after surgery. Due to a negative pathology report, chemotherapy was discontinued post-surgery. The patient is currently free of tumor and she is following in 3 months interval.

Discussion

As mentioned, cervical cancers are rarely diagnosed during pregnancy;⁹ unfortunately, most current treatments lead to pregnancy fail and loss of fertility.¹¹ Treatment is difficult during pregnancy and all side effects should be considered.¹ Obstetricians suggest a new management approach for young fertile women with cervical cancer. Abdominal radical trachelectomy instead of radical hysterectomy is suggested for preservation of pregnancy.¹² Neoadjuvant chemotherapy is not an approved method for SCC treatment during pregnancy.¹⁰ In general, three approaches are recommended for cervical cancer management during pregnancy: 1) radical hysterectomy, which is associated with pregnancy termination; 2) planned postponing and observation; and 3) chemotherapy until fetal lung maturation.

Two recent strategies should be applied in radical hysterectomy.¹² Two important factors in

SCC treatment are tumor size and nodal staging. The diagnostic procedures for this purpose include magnetic resonance imaging and laparoscopic lymphadenectomy⁷ and relevant pregnancy pathologic changes should be considered while interpreting the results.¹³

Robova et al., in a study on squamous intraepithelial lesion of the cervix in 23 women suspicious for early invasion, have proposed that following pregnant patients with low and high grades of squamous intraepithelial lesions until delivery time is sufficient. The main therapeutic measure should be performed after delivery, and conization is a safe surgical procedure until the 24th week of pregnancy in carcinoma suspected cases.¹⁴

Van DeNieuwenhof et al. reported a case of cervical carcinoma in a pregnant woman diagnosed in the 16th week of pregnancy. She underwent radical hysterectomy after delivery in the 36th week of pregnancy by caesarian section

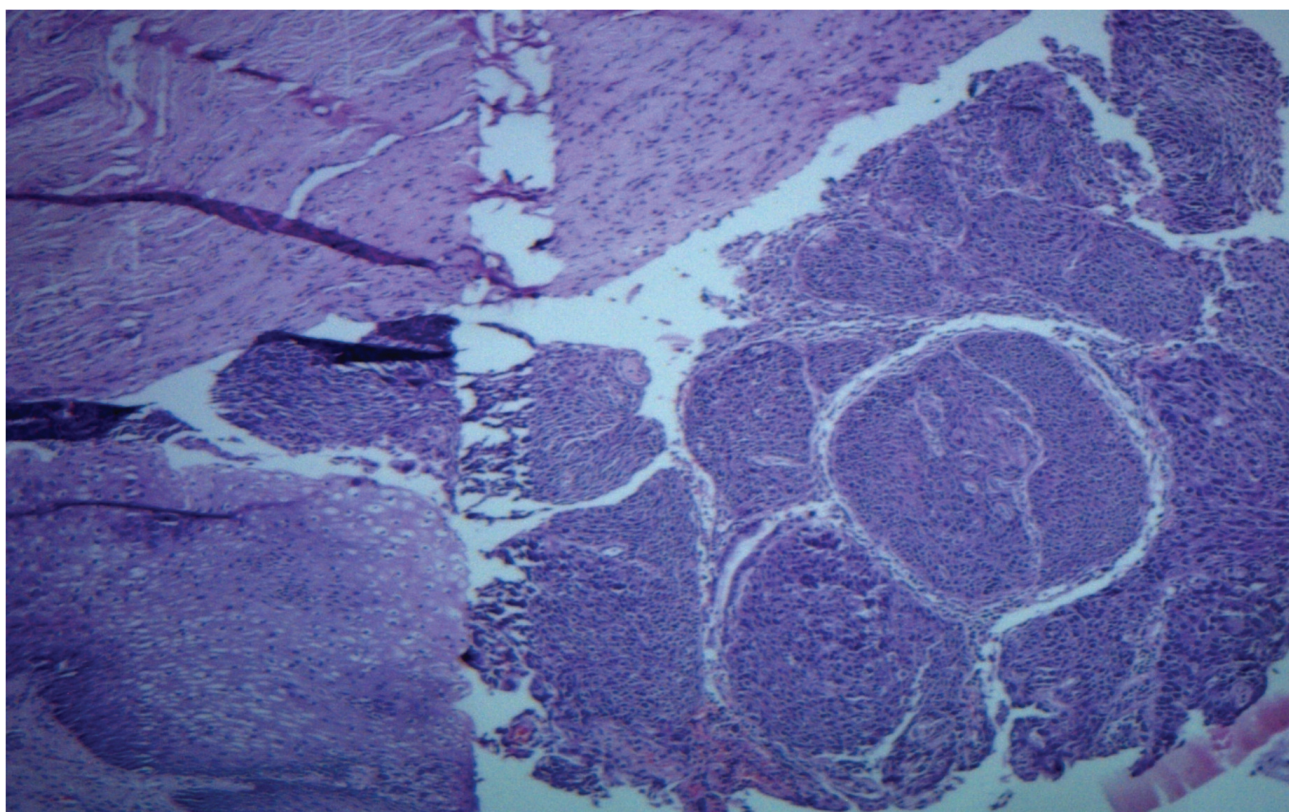


Figure 1. Prepared pathologic slide revealed invasive squamous cell carcinoma (SCC) of a large cell non-keratinizing type with undetermined margins. The cells were moderately differentiated and involved all quadrants (100× magnification; H&E staining).

and was followed for nine months after the surgery. The authors recommended vaginal trachelectomy as a reliable method for preservation of pregnancy.¹²

Hecking et al. studied 121 cases of cervical cancer during pregnancy, 5 of whom were SCC. They performed colposcopy and pap tests for all five cases. Pap test interpretation and tumor grading were performed according to Munich nomenclature II and the Federation of Gynecology and Obstetricians, respectively. They diagnosed SCC based on the conization reports in the postpartum period, which revealed the presence of malignant cells in the vaginal canal. There was metastasis in the lymph nodes in one case and lymphovascular invasion in two patients. Three patients had low cell differentiation. All medical findings were poor prognostic factors.¹ We observed the presence of stromal and lymphovascular invasions in our patient.

They applied four cycles of neoadjuvant chemotherapy with cisplatin for one of the cases who was diagnosed in the 20th week of pregnancy with a 3 cm diameter mass. The patient had no complications and the infant had no problems after birth. Caesarean section in association with radical hysterectomy and pelvic lymphadenectomy was performed in the 35th week of pregnancy with adjuvant chemotherapy during the postpartum period by the oncologist.¹ We planned and followed the same treatment program for our patient. Our chemotherapy regimen consisted of taxol and adjuvant chemotherapy after delivery.

Fruscio et al. reported the cases of 9 pregnant women who had cervical cancer with tumor diameters of 20-70 mm. These patients underwent platinum-based chemotherapy. Caesarean section was performed during the 30-36th weeks of gestational age, followed by radical hysterectomy and pelvic hysterectomy in all cases. Finally, four out of nine cases relapsed and two had tumor progression, which led to death.¹⁵ Although our case underwent a similar treatment path, except for the chemotherapy regimen, she had a completely different result.

In some reports, surgical intervention is

successful for a temporary period of time, but relapse will occur in the undetermined future. Rabaiotti et al. reported the case of a 27-year-old woman (gravida: 1, para: 0), diagnosed with SCC in the 15th week of pregnancy. She underwent the same surgical treatment as our case. Chemotherapy was performed four weeks after caesarean section. She had normal life during the first year; however, relapsed one year after childbirth and died two years after diagnosis.¹⁶ It seemed that neoadjuvant chemotherapy was unsuccessful in that case. However, it was successful for our case.

Conclusion

Although chemotherapy is not a standard treatment for cervical cancer in pregnancy, but neoadjuvant chemotherapy followed by radical hysterectomy and bilateral pelvic lymphadenectomy during cesarean section was a successful treatment in our patient.

Conflict of Interest

None declared.

References

1. Hecking T, Abramian A, Domröse C, Engeln T, Thiesler T, Leutner C, et al. Individual management of cervical cancer in pregnancy. *Arch Gynecol Obstet.* 2016;293(5):931-9.
2. Mocarska A, Starosławska E, Zelazowska-Cieślińska I, Łosicki M, Stasiewicz D, Kieszko D, et al. Epidemiology and risk factors of the cervical squamous cell carcinoma. [Article in Polish] *Pol Merkur Lekarski.* 2012;33(194):101-6.
3. Hiniker SM, Roux A, Murphy JD, Harris JP, Tran PT, Kapp DS, et al. Primary squamous cell carcinoma of the vagina: prognostic factors, treatment patterns, and outcomes. *Gynecol Oncol.* 2013;131(2):380-5.
4. Gadducci A, Fabrini MG, Lanfredini N, Sergiampietri C. Squamous cell carcinoma of the vagina: natural history, treatment modalities and prognostic factors. *Crit Rev Oncol Hematol.* 2015;93(3):211-24.
5. Madsen BS, Jensen HL, van den Brule AJ, Wohlfahrt J, Frisch M. Risk factors for invasive squamous cell carcinoma of the vulva and vagina--population-based case-control study in Denmark. *Int J Cancer.* 2008;122(12):2827-34.
6. Sadler L, Sykes P. How little is known about cervical cancer in pregnancy? *Ann Oncol.* 2005;16(3):341-3.

7. Morice P, Uzan C, Gouy S, Verschraegen C, Haie-Meder C. Gynaecological cancers in pregnancy. *Lancet*. 2012;379(9815):558-69.
8. Han SN, Gziri MM, Van Calsteren K, Amant F. Cervical cancer in pregnant women: treat, wait or interrupt? Assessment of current clinical guidelines, innovations and controversies. *Ther Adv Med Oncol*. 2013;5(4):211-9.
9. Eitan R, Abu-Rustum NR. Management of cervical carcinoma diagnosed during pregnancy. *Primary Care Update for OB/GYNS*. 2003;10(4):196-200.
10. Ribeiro F, Correia L, Paula T, Santana I, Pinto LV, Borrego J, et al. Cervical cancer in pregnancy: 3 cases, 3 different approaches. *J Low Genit Tract Dis*. 2013;17(1):66-70.
11. Ungár L, Smith JR, Pálfalvi L, Del Priore G. Abdominal radical trachelectomy during pregnancy to preserve pregnancy and fertility. *Obstet Gynecol*. 2006;108(3 Pt 2):811-4.
12. van de Nieuwenhof HP, van Ham MA, Lotgering F, Massuger L. First case of vaginal radical trachelectomy in a pregnant patient. *Int J Gynecol Cancer*. 200c;18(6):1381-5.
13. de Haan J, Vandecaveye V, Han S, Van de Vijver K, Amant F. Difficulties with diagnosis of malignancies in pregnancy. *Best Pract Res Clin Obstet Gynaecol*. 2016;33:19-32.
14. Robova H, Rob L, Pluta M, Kacirek J, Halaska Jr M, Strnad P, et al. Squamous intraepithelial lesion-microinvasive carcinoma of the cervix during pregnancy. *Eur J Gynaecol Oncol*. 2005;26(6):611-4.
15. Fruscio R, Villa A, Chiari S, Vergani P, Ceppi L, Dell'Orto F, et al. Delivery delay with neoadjuvant chemotherapy for cervical cancer patients during pregnancy: a series of nine cases and literature review. *Gynecol Oncol*. 2012;126(2):192-7.
16. Rabaiotti E, Sigismondi C, Montoli S, Mangili G, Candiani M, Viganò R. Management of locally advanced cervical cancer in pregnancy: a case report. *Tumori*. 2010;96(4):623-6.