

Wilms' Tumor: Histopathological Variants and the Outcomes of 31 Cases at a Tertiary Care Center in Northern India

Pradeep Kajal**, Kamal Nain Rattan*, Namita Bhutani**, Nisha Marwah**

*Department of Pediatric Surgery, PGIMS Rohtak, Haryana, India

**Department of Pathology, PGIMS Rohtak, Haryana, India

Abstract

Background: Wilms' tumor is the most common malignant renal tumor in the pediatric age group. This tumor is classically managed by multimodal treatment which involves surgery, radiotherapy and chemotherapy. While there is plenty of data in world literature on the outcome of Wilms' tumor, there is a paucity of data from India.

Methods: All patients with proven diagnosis of Wilms' tumor between 2008 to 2012 were noted from the hospital's cancer registry. We performed detailed analyses of all patients' clinical case records for demographic profiles, clinical features, imaging studies, treatment, and outcome. Histopathological classification of the tumor determined the patient's post-operative management. All patients were followed for a period of 3 years and we analyzed the eventual outcome in the form of disease-free survival, complications, tumor recurrence, and mortality.

Results: There were 31 cases of Wilms' tumor included in this study. The median age of presentation was 3-4 years (range: 5 months-6 years) with a female: male ratio of 1.2:1. Abdominal mass was the chief presenting feature in 20 (64.5%) patients followed by abdominal pain in 6 (19.3%). All children had unilateral disease, 25 (80.6%) had right-sided and 6 (19.3%) had left-sided disease. Bilateral disease was seen in only one case. Of the 31 cases of Wilms' tumor, 36% cases presented with stages I and II disease, 55% had stage III, and 9% of the cases were stage IV. Most cases of Wilms' tumor were stage III. The majority had classical Wilms' tumor with a favourable histology. The estimated 5-year event free survival was 87.3%

Conclusion: A multidisciplinary approach can approach similar survival rates compared to the National Wilms' Tumor Study Group, even in the Indian scenario. Further improvement in survival of these children can only be achieved by increasing awareness, early recognition, appropriate referral, and a multidisciplinary approach.

Keywords: Chemotherapy, Pediatric, Survival, Wilms' tumor

♦Corresponding Author:

Pradeep Kajal, M.Ch.
2318FM, Medical Campus,
PGIMS, Rohtak, Haryana, India
124001
Tel: +91-8221000060
Fax: +91-1262-211308
E-mail: drpradeepkajal@gmail.com

Introduction

Wilms' tumor (nephroblastoma), an embryonal type of renal cancer, is one of the most common solid malignant neoplasms in children that accounts for 6% of all childhood tumors and more than 95% of all pediatric tumors of the kidney.^{1,2} It is seen primarily in infants, with 50% of the cases that occur below the age of 3 years.³ There is no sex predilection. Wilms' tumor is usually sporadic, although 1%-2% of the patients have a positive family history. Grossly, most tumors are large, solitary, grey-white and fleshy, well-circumscribed, rounded, and soft in consistency. Cut-sections show predominantly solid pale areas with cystic change, necrosis, and hemorrhage.⁴ Microscopically, the tumor comprises three major components - undifferentiated blastema, mesenchymal (stromal) tissue, and epithelial tissue. When all the three components present together, it is called triphasic or classic Wilms' tumor, however it may also be bi- or monophasic.⁵

Wilms' tumor is a paradigm for multimodal treatment of pediatric solid malignancies. The usual treatment approach in most patients is a combination of surgery and chemotherapy, with the addition of radiotherapy in high risk patients. Surgery maintains an important role in the treatment of Wilms' tumor despite the fact that the improved outcome for this malignancy during the last century is assigned mainly to advances in chemotherapy. Among the different prognostic factors, stage and histologic type play important roles in assessing the prognosis and survival of patients with Wilms' tumor. Clinicopathological staging of Wilms' tumor is the single most important prognostic determinant. Favourable and unfavourable histologic types have a great impact on prognosis. Remarkable progress has been achieved in the management and outcome of Wilms' tumor during the last two decades.^{6,7} This has largely been the result of a multidisciplinary approach by the large collaborative groups, namely the National Wilms' Tumor Study Group (NWTSG) and International Society of Pediatric Oncology (SIOP). However the outcome remains poor in most developing countries.⁸ A paucity of data exists for the epidemiology, pathology, treatment, and

prognosis of this disease from India. The aim of this article is to review the current thoughts on histology, diagnosis, and management of Wilms' tumor in the pediatric age group.

Materials and Methods

All patients with proven diagnosis of Wilms' tumor from 2008 to 2012 were noted from the hospital's cancer registry. We analyzed patients' clinical case records in detail for demographic profile, clinical features, imaging studies, treatment, and outcome. The hospital protocol for workup of these patients included: a) laboratory studies for renal function (serum creatinine, GFR, urinalysis), liver function, and a complete blood count and b) imaging studies [abdominal ultrasonography/Doppler ultrasonography/contrast-enhanced computed tomography (CECT)]. Doppler ultrasonography was performed to detect tumor infiltration of the renal vein and inferior vena cava, and to assess patency of the blood flow. Contrast-enhanced CT was used to further evaluate the nature and extent of the mass. Imaging of the chest (CT or chest radiography) was used to rule out lung metastases. Patients at our institution received treatment based on the NWTSG IV protocol. This regime included surgery followed by postoperative histopathological confirmation of diagnosis, then radiotherapy and chemotherapy based on disease stage. Regardless of the protocol, all patients younger than 6 months did not receive any primary chemotherapy since congenital mesoblastic nephroma is the most common solid renal tumor of the newborn period. Nephrectomy is considered adequate treatment for infants aged less than 6 months. Classic Wilms' tumor was diagnosed based on varying proportions of the three cell types (blastemal, stromal, and epithelial). After completion of treatment, patients were seen for follow-up each 3 months for the initial 2 years and at 6-month intervals thereafter. Every follow-up visit consisted of clinical examination, abdominal ultrasound, and chest radiograph. Relapse and disease progression (labelled as appearance of new metastatic lesions/increase in size of the primary lesion) were considered as events. We correlated the outcome

with age (less than or more than 2 years), sex, stage at presentation and histology. The event-free survival and overall survival were evaluated for all patients using the Kaplan Meier curve (SPSS 17).

Results

We examined a total of 31 cases of Wilms' tumor. Patients had a median age at presentation of 3-4 years (range: 5 months-6 years). There were 14 (45.2%) male and 17 (54.8%) female cases with a female: male ratio of 1.2:1 (Table 1).

Abdominal mass was the chief presenting complaint in 20 (64.5%) patients followed by abdominal pain in 6 (19.3%), and gross hematuria in 5 (16.1%). One child with extra renal Wilms' tumor presented with acute renal failure secondary to urinary tract obstruction. A total of 13 (41.9%) cases had hypertension, while developmental delay and hypospadias were seen in one child each. There were 2 children who presented with thrombi in the inferior vena cava and renal vein with extension to the right atrium in one case.

All cases underwent CT scans of the abdomen and pelvis for diagnosis. Almost all children had unilateral disease, 25 (80.6%) had right-sided and 6 (19.3%) had left-sided disease. Only one case had bilateral disease (Figure 1).

Of the 31 cases of Wilms' tumor, 36% presented with stages I and II disease, 55% presented with stage III, 9% cases had stage IV disease and 1 case (4.5%) had stage V disease and he later succumbed to his illness (Table 2). Most cases of Wilms' tumor were stage III. One patient had metastatic deposits in the liver and another in the lungs, while two had involvement of both organs. The majority had classical Wilms' tumor with favourable histology (Figure 2). The lungs were the most common site of metastasis. Congenital anomalies were present in 4.5% patients.

We noted an equal distribution of epithelial and blastema predominance which did not show any correlation with staging. There was unfavourable histology in one (3.2%) out of 31 cases.

Patients received therapy according to NWTSG guidelines. A total of 16 children with Wilms' tumor received treatment, with a relapse-free survival of

Table 1. Age and sex distribution of cases.

Age (years)	No. of cases	Males	Females
1-2	1	1	0
2-3	9	5	
3-4	16	6	10
4-5	3	1	2
>5	2	1	1
Total	31	14	17

56%. The follow up period after treatment was 1-63 months (average: 16 months) with an estimated 5-year event-free survival of 87.3%.

All complications were associated with a tumor size over 5 cm or with patients who did not receive primary chemotherapy. A total of 46% of cases received neoadjuvant chemotherapy that included vincristine and actinomycin D whereas 95% received adjuvant therapy. Chemotherapy was performed in 40% of cases and included vincristine, actinomycin D plus cyclophosphamide, adriamycin, and ifosfamide. Radiochemotherapy was performed in 55.5% of patients. Patients with stages II, III or IV diffuse anaplasia received abdominal irradiation and a chemotherapy regimen that consisted of vincristine, doxorubicin, and cyclophosphamide alternating with cyclophosphamide and etoposide. Patients with stages II-IV focal anaplasia underwent abdominal irradiation and received vincristine, doxorubicin, and actinomycin D. Staging was performed according to the NWTSG system (Table 3).

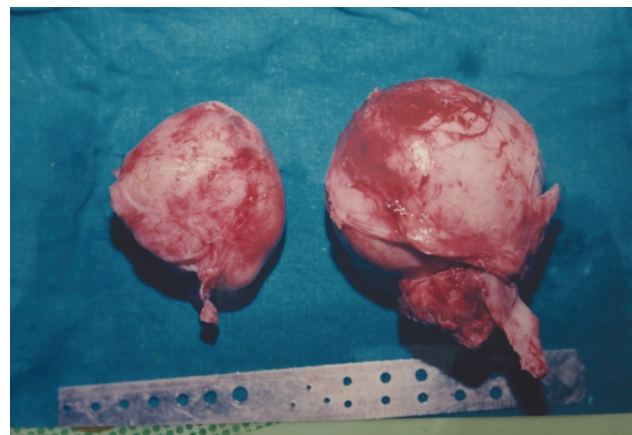


Figure 1. Specimen photograph of a case of bilateral Wilms' tumor with total nephrectomy on one side and sub-total nephrectomy on the other side.

Discussion

Wilms' tumor (nephroblastoma), an embryonal type of renal cancer, is one of the most common solid malignant neoplasms in children. Although initially described by Thomas F. Rance in 1814, the tumor was named for Max Wilms, a German surgeon and pathologist, who gave a detailed description in 1899.⁹ This tumor accounts for approximately 90% of all pediatric tumors of the kidney and 5% of all childhood cancers.² More than 80% of children diagnosed with Wilms' tumor are below the age of five years and the median age at diagnosis is 3.5 years. The tumor is one of the few childhood cancers with a slight female preponderance among Caucasian patients. It usually arises in a single kidney. Synchronous bilateral or multifocal tumors occur in approximately 10% of patients and tend to present at an earlier age.¹⁰ Wilms' tumor is primarily a disease of the kidneys, but occasionally extrarenal locations have been reported, especially in the retroperitoneum, the sacrococcygeal region, testis, uterus, inguinal canal, and mediastinum.¹¹

The definitive fetal kidney develops from the ureteric bud and the metanephric

Table 2. Distribution of cases according to stage and survival rate.

Stage	No. of cases (%)	Survival (%)
I and II	8 (36)	7 (87.5)
II	12 (55)	8 (66.67)
IV	2 (9)	1 (50)
V	1 (4.5)	-

mesenchyme/blastema. The blastema usually disappears by 36 weeks of gestation, however at birth approximately 1% of infants retain residual blastema within their kidneys. These cells are described as nephrogenic rests, defined by Beckwith as: "a focus of abnormally persistent nephrogenic cells that can be induced to form a Wilms' tumor."⁵ Wilms' tumor can develop within a proportion of nephrogenic rests. Nephrogenic rests can be identified in 40% of Wilms' tumor patients and are believed to be the putative precursor lesions of Wilms' tumors. Nephrogenic rests are present in 90% of bilateral cases, which is thought to reflect mutations/epimutations either in the germline or those which occur very early in the developing embryo. These rests are subdivided into two types: intralobar nephrogenic rests (ILNR) found anywhere

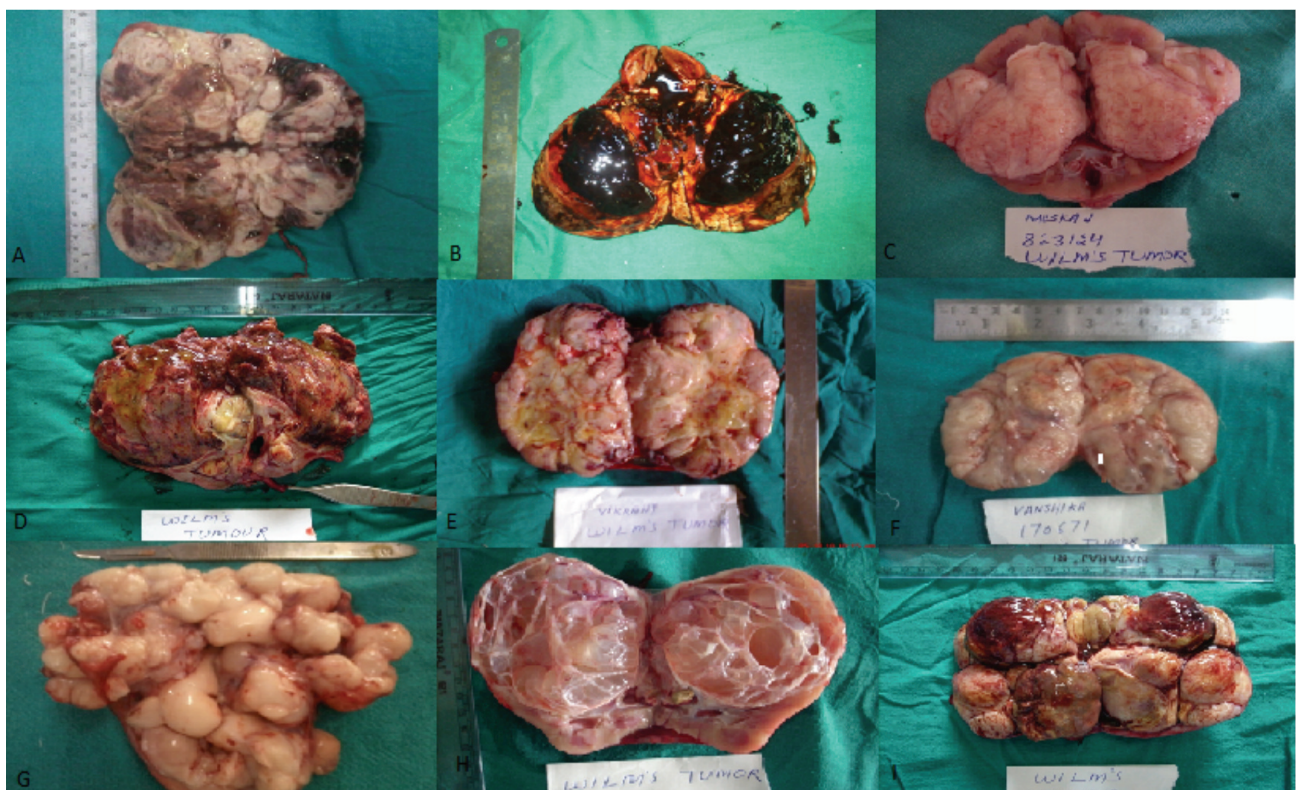


Figure 2. Different patterns of gross appearance of Wilms' tumor encountered on cut section.

within the renal lobe and perilobar nephrogenic rests (PLNR), which are confined to the periphery of the renal lobe and thought to develop later during embryogenesis. Nephroblastomatosis is defined as the “diffuse or multifocal presence of nephrogenic rests or their recognized derivatives”.¹²

There are three main types of Wilms' tumor cells: blastema that resemble undifferentiated embryonic metanephric mesenchyme together with epithelium and stroma, both believed to have differentiated from the blastema. These cell types are distinguished histologically; currently there are no good markers to specifically identify blastema.

Approximately 5% of patients with Wilms' tumor have an underlying predisposing genetic syndrome; over 50 such syndromes have been described. Several syndromes result from a disruption of the WT1 gene, which encodes the transcription factor WT1 that is crucial for renal and gonadal embryogenesis. Disruption of the WT1 gene typically results in genitourinary abnormalities and predisposition to early Wilms' tumors. Missense mutations of WT1 result in Denys-Drash syndrome characterized by a greater than 50% risk of developing Wilms' tumor, genitourinary abnormalities, and nephropathy. The WT2 locus at 11p15 is an area of imprinting, such that the gene expression is dependent upon whether it has been inherited from the mother or father. This is due to differential methylation of alleles that depend on their parent of origin. In Beckwith-Wiedemann syndrome this region can be disrupted in a number of ways, most commonly as a result of hypomethylation or uniparental disomy. Tumors in patients with Beckwith-Wiedemann syndrome may occur later, though usually before the age of 7 years, and are often found with associated PLNR. Other syndromes and genes implicated in the increased risk of Wilms' tumor include Simpson-Golabi-Behmel syndrome, an overgrowth syndrome that features coarse facial features, in addition to skeletal, cardiac, renal, and intellectual defects due to a mutation in the GPC3 gene, biallelic BRCA2 mutations/Fanconi anemia D1, Bloom syndrome and Li-Fraumeni syndrome. Children with genetic syndromes associated with an increased risk of Wilms' tumor

Table 3. Patients, disease, and treatment characteristics.

	No.	Percentage (%)
Gender		
Male	14	17
Female	45.2	54.8
Age at surgery (Years)		
Minimum	0.4	
Median	2.8	
Maximum	6	
Type of surgery		
Radical nephrectomy	27	87.0
Simple nephrectomy	4	12.9
Lymph node dissection		
Yes	27	87.0
No	4	12.9
Primary treatment		
Surgery	21	67.8
Chemotherapy	10	32.2
NWTSG stage		
I	5	16.1
II	3	9.7
III	12	38.7
IV	2	6.4
V	1	3.2
Clinical presentation		
Weight loss	15	48.3
Palpable mass	20	64.5
Hematuria	6	19.3
Fever	5	16.1
Anemia	1	3.2
Hepatomegaly	2	6.4
Hypertension	13	40.6
Other	3	9.6
Surgical complications		
Tumor rupture	2	6.4
Congestive heart failure	1	3.2
Intestinal perforation	4	12.9
Ileus	2	6.4
Pathological lymph node status		
Yes	6	19.3
No	25	93.5
Adjuvant therapy		
Chemotherapy	12	40
Radiochemotherapy	18	55.5
No postoperative therapy	1	3.22
Histological subtypes		
Well-differentiated	9	29
Moderately differentiated	15	48.3
Poorly differentiated	6	19.35
Anaplastic tumor	1	3.22
Tumor recurrence		
No	28	90.3
Yes	3	9.7

are screened with regular ultrasounds throughout the risk period. The genes implicated in these genetic syndromes have also been implicated in the pathogenesis of sporadic Wilms' tumors. The WT1 gene is inactivated, usually by inactivating a deletion or point mutation in 10%-20% of sporadic Wilms' tumors. The Igf2 locus is deregulated in 30%-69% of tumors through loss of imprinting which leads to Igf2 expression or somatic loss of the maternal allele and duplication of the paternal allele.¹³

The vast majority of Wilms' tumors present with an asymptomatic abdominal mass usually discovered by a family member during bathing the child. In approximately 20%-30% of cases the presenting signs and symptoms include abdominal pain, malaise, and hematuria which can be either microscopic or macroscopic. Associated hypertension, most likely due to increased renin activity, is found in about 25% of children with Wilms' tumor. Hypertension, which may occur as a direct effect of the presence of a renal mass, usually resolves after nephrectomy. Atypical presentations are found in less than 10% of cases and result from compression of surrounding organs or vascular infiltration. Tumor extension into the renal vein or inferior vena cava occurs in less than 4% of patients. Presenting symptoms of children with vascular extension include ascites, congestive cardiac failure, and hepatomegaly. Occasionally, a child may present with an acute abdomen (rapidly enlarging abdominal mass, anemia, hypertension, pain, and fever) due to tumor rupture or for investigation of a varicocele or other genitourinary abnormalities. Tumor production of hormonal substances may lead to paraneoplastic syndromes, including hypercalcemia, erythrocytosis and acquired von Willebrand disease.¹⁴

An abdominal ultrasound is the most useful initial investigation to confirm the presence of a primary intrarenal mass. Current standard practice includes a computed tomography (CT) or preferably magnetic resonance imaging (MRI) scan of the abdomen and pelvis in children with suspected renal tumors. The MRI scan is especially beneficial in children with suspected bilateral renal lesions and enables reduction of exposure to radiation.

Additional techniques such as apparent diffusion coefficient (ADC) mapping are also used to give further information about the biology of the tumor. The lungs are the most common site of metastatic spread that occurs in 10%-20% of children with Wilms' tumor at the time of diagnosis. In approximately 11% of children, the Wilms' tumor extends intravenously. Thrombus extension into the inferior vena cava occurs in around 4% of cases and echocardiography should be considered in the rare circumstances when intracardiac tumor infiltration is expected. Recently, urinary basic fibroblast growth factor (bFGF) is reportedly elevated preoperatively in patients with Wilms' tumor. McDonald et al. have described the tissue polypeptide specific antigen (TPS), a cytokeratin-18 derived marker, which might be of clinical value in monitoring nephroblastoma therapy.¹⁵

Wilms' tumor management requires multidisciplinary input by pediatric oncologists, specialist surgeons, radiologists, pathologists, and radiation oncologists. The role of surgery in Wilms' tumor therapy is critical as a meticulous, well-performed procedure reduces the risk of tumor rupture and need for radiotherapy, which can be minimized in more experienced hands. Careful removal of the tumor without rupture or spill is imperative because these patients have a six-fold increased risk of local abdominal relapse. Therefore, a precise, well-performed procedure avoids the need for postoperative irradiation. Transperitoneal radical nephrectomy ensures thorough exploration of the abdominal cavity and is the preferred operative procedure for unilateral Wilms' tumor. Pre-operative chemotherapy is included in the treatment of children with Wilms' tumor. It consists of double-agent chemotherapy (vincristine and dactinomycin) in children with localized tumors, and additional doxorubicin in those who present with metastases. Pre-operative chemotherapy is recommended and is a logical strategy for patients with large tumors in a setting where supportive care is restricted and radiotherapy may not be available.^{16,17}

Management of a child with bilateral Wilms' tumor is challenging and requires planning according to individualized patient needs, careful monitoring

of response to chemotherapy, together with an understanding of the underlying histology and biology. For example, chemotherapy is not beneficial for stromal-predominant Wilms' tumor with rhabdomyoblastic features, whereas other histological subtypes may benefit from additional chemotherapy. Therefore, the surgical approach for each kidney has to be considered individually. In case of discordant histology, chemotherapy is given as appropriate to the higher risk lesion.¹⁶

Fortunately, Wilms' tumor is a curable malignancy in most patients, hence limiting iatrogenic sequelae is essential wherever possible. In addition to morbidity from chemotherapeutic agents, potential adverse effects of radiotherapy include intestinal strictures, ulceration, perforation, hematochezia, growth arrest, and osteonecrosis must be considered.¹⁷ Over the last few decades the treatment of Wilms' tumor has undergone incremental improvement in survival rates despite a general trend to reduced therapy for the majority. Long-term survivors of Wilms' tumor are at increased risk of treatment related morbidity and mortality. The most common complications are cardiotoxicity (4.4%), musculoskeletal problems (3%), and the development of secondary malignant neoplasms (1%). Patients treated with anthracyclines, such as doxorubicin, may present with congestive heart failure that occurs many years after treatment. The most important risk factor for cardiac dysfunction is the total cumulative dose of doxorubicin, female sex, and left flank irradiation. However, any amount of anthracycline exposure may lead to myocardial injury. There are potential long-term hazards of radiotherapy to the lungs such as pulmonary fibrosis. Long-term survivors of Wilms' tumor have also been noted to have an increased risk of developing subsequent secondary malignant neoplasms (6.7% at 40 years from diagnosis). Secondary malignancies include bone and soft-tissue sarcomas, breast cancer, lymphoma, leukemia, and melanoma.^{18,19}

Nevertheless, one of the aims of long-term follow up is monitoring renal function. Recommended follow-up guidelines state that Wilms' tumor survivors should have both blood pressure and an

early morning urine test for protein/creatinine ratios measured annually, and serum creatinine measurements every five years for life.²⁰

Over the past five decades, the multidisciplinary approach to Wilms' tumor management has become an example of the success of pediatric oncology. Successful management of this malignancy requires meticulous attention to the correct staging of the tumor and good communication between members of a multidisciplinary team.

Conflict of Interest

No conflict of interest is declared.

References

1. Pastore G, Znaor A, Spreafico F, Graf N, Pritchard-Jones K, Steliarova-Foucher E. Malignant renal tumours incidence and survival in European children (1978-1997): report from the Automated Childhood Cancer Information System project. *Eur J Cancer*. 2006;42(13):2103-14.
2. Breslow N, Olshan A, Beckwith JB, Green DM. Epidemiology of Wilms tumor. *Med Pediatr Oncol*. 1993;21(3):172-81.
3. Jaffe, N; Huff, V. Neoplasm of the kidney. In: Behrman, RE; Kliegmen, RM; Jenson, HB, editors. Nelson's text book of pediatrics. 17th ed. Philadelphia: Saunders Elsevier; 2004.p.1711-4.
4. Ordonez, NG; Rosai, J. Urinary tract. In: Rosai, J, editor. Rosai and Ackerman's surgical pathology. 9th ed. St. Louis: Mosby, Elsevier; 2004.p.1240-5.
5. Beckwith JB. Wilms' tumor and other renal tumors of childhood: a selective review from the National Wilms' Tumor Study Pathology Center. *Hum Pathol*. 1983;14(6):481-92.
6. Arndt V, Lacour B, Steliarova-Foucher E, Spix C, Znaor A, Pastore G, et al. Up-to-date monitoring of childhood cancer long-term survival in Europe: tumours of the sympathetic nervous system, retinoblastoma, renal and bone tumours, and soft tissue sarcomas. *Ann Oncol*. 2007;18(10):1722-33.
7. D'Angio GJ. The National Wilms Tumor Study: a 40 year perspective. *Lifetime Data Anal*. 2007;13(4):463-70.
8. Ekenze SO, Agugua-Obianyo NE, Odetunde OA. The challenge of nephroblastoma in a developing country. *Ann Oncol*. 2006;17(10):1598-600.
9. Wilms, M. Die Mischgeschwülste der Niere. Leipzig: Verlag von Arthur Georgi; 1899.
10. Buckley KS. Pediatric genitourinary tumors. *Curr Opin Oncol*. 2011;23(3):297-302.
11. Roberts DJ, Haber D, Sklar J, Crum CP. Extrarenal

- Wilms' tumors. A study of their relationship with classical renal Wilms' tumor using expression of WT1 as a molecular marker. *Lab Invest.* 1993;68(5):528-36.
12. Breslow NE, Beckwith JB, Perlman EJ, Reeve AE. Age distributions, birth weights, nephrogenic rests, and heterogeneity in the pathogenesis of Wilms tumor. *Pediatr Blood Cancer.* 2006;47(3):260-7.
 13. Scott RH, Stiller CA, Walker L, Rahman N. Syndromes and constitutional chromosomal abnormalities associated with Wilms tumour. *J Med Genet.* 2006;43(9):705-15.
 14. Baxter PA, Nuchtern JG, Guillerman RP, Mahoney DH, Teruya J, Chintagumpala M, et al. Acquired von Willebrand syndrome and Wilms tumor: not always benign. *Pediatr Blood Cancer.* 2009;52(3):392-4.
 15. McDonald K, Sebire NJ, Anderson J, Olsen OE. Patterns of shift in ADC distributions in abdominal tumours during chemotherapy-feasibility study. *Pediatr Radiol.* 2011;41(1):99-106.
 16. Ko EY, Ritchey ML. Current management of Wilms' tumor in children. *J Pediatr Urol.* 2009;5(1):56-65.
 17. Israels T, Moreira C, Scanlan T, Molyneux L, Kampondeni S, Hesselting P, et al. SIOP PODC: clinical guidelines for the management of children with Wilms tumour in a low income setting. *Pediatr Blood Cancer.* 2013;60(1):5-11.
 18. Termuhlen AM, Tersak JM, Liu Q, Yasui Y, Stovall M, Weathers R, et al. Twenty-five year follow-up of childhood Wilms tumor: a report from the Childhood Cancer Survivor Study. *Pediatr Blood Cancer.* 2011;57(7):1210-6.
 19. Breslow NE, Lange JM, Friedman DL, Green DM, Hawkins MM, Murphy MF, et al. Secondary malignant neoplasms after Wilms tumor: an international collaborative study. *Int J Cancer.* 2010;127(3):657-66.
 20. Skinner R, Wallace WH, Levitt GA; UK Children's Cancer Study Group Late Effects Group. Long-term follow-up of people who have survived cancer during childhood. *Lancet Oncol.* 2006 Jun;7(6):489-98.