Case Report
Middle East Journal of Cancer; January 2020 11(1): 109-113

Metastasis of Breast Cancer to the Mandibular Gingiva: Report of a Rare Case

Farnoosh Razmara*, Reza Sharifi*, Ghazal Shabankareh, Samira Derakhshan***♦**

**Craniomaxillofacial Research Center, Oral and Maxillofacial Surgery Department, School of Dentistry, Tehran University of Medical Sciences, Tehran, Iran*
***Dental Student, School of Dentistry, Tehran University of Medical Sciences, Tehran, Iran*
****Oral and Maxillofacial Pathology Department, School of Dentistry, Tehran University of Medical Sciences, Tehran, Iran*

Abstract

Metastatic tumors to the oral cavity are rare and account for only 1% of all oral cavity malignancies, and if occurs, it involves the jaws rather than the soft tissue. Diagnosis of a metastatic lesion in gingiva can be challenging owing to its rarity and atypical appearance. In this paper, we describe a rare case of breast cancer metastasis to the gingival soft tissue of mandible. A 68-year-old female referred to the department of oral and maxillofacial surgery with the chief complaint of a painful mass in the right buccal and lingual anterior region of the mandible with the mobility of the involved teeth. The patient also reported the history of a breast cancer dating back to eight years ago. Histopathologic findings and immunohistochemistry results supported a metatatic lesion. As a result, it is important to have a great clinical suspicion to diagnose such lesions in order to receive the most proper treatment to patients as soon as possible.

Keywords: Breast cancer, Gingiva, Metastasis, Oral cavity

Introduction

Metastasis in the oral cavity is rare and accounts for only 1% of all oral malignancies.[1] They involve the bony structures of the oral cavity rather than the soft tissue. In fact, soft tissue involvement of the oral cavity in metastasis occurs in only 0.1% of cases.[2] The mandible is more frequently affected than the maxilla, particularly in distal areas of the molars and the ramus, due to hematopeitic bone marrow, slowing of blood flow and branching of blood vessels, making these sites vulnerable to deposition of neoplastic cells.[3]

Metastatic tumors of oral cavity can present themselves with various clinical signs and symptoms such as pain, swelling, gum irritation, halitosis, tooth mobility, exophytic

♦**Corresponding Author:**
Samira Derakhshan, DDS, MSc
North Kargar St., Dental School of Tehran University of Medical Sciences, Tehran, Iran
Postal code: 1439955991
Tel: +982188351163
Fax: +982142794142
Email: sderakhshan@tums.ac.ir

Received: January 26, 2019; Accepted: August 25, 2019

masses of soft tissue, and trismus. Between all signs and symptoms, numbness of chin should be considered an important sign, since it is considered to be a harbinger of cancer relapse or progression.[4]

The purpose of this paper is to describe a rare case of breast cancer metastasis to the gingival soft tissue of the anterior region of the mandible.

Case Report

A 68-year-old female with the complaint of a painful mass in her mouth referred to the Department of Oral and Maxillofacial Department of Dentistry Faculty of Tehran University of Medical Sciences (TUMS) in August 2017. Her medical history revealed mastectomy due to an invasive ductal carcinoma of breast eight years ago. The adjuvant chemotherapy was finished five years ago. There was not any recurrence or distant metastasis of her neoplasm in recent years after surgical treatment of the primary tumor.

An intraoral examination revealed swelling of buccul and lingual gingiva surrounding right incisors and canine of mandible (Figure 1). The exophytic mass was ulcerated, tender on palpation and led to distinct mobility of the involved teeth, making serious problems in eating for her. The differential diagnoses were pyogenic granuloma, squamous cell carcinoma, and distant metastasis of previous breast carcinoma.

Figure 1. Clinical view: Note extension of the lesion to lingual aspect and displacement of the tooth.

In the radiographic evaluation by panoramic, there was not any intraosseous lesion, but the soft tissue mass produced mild saucerization in

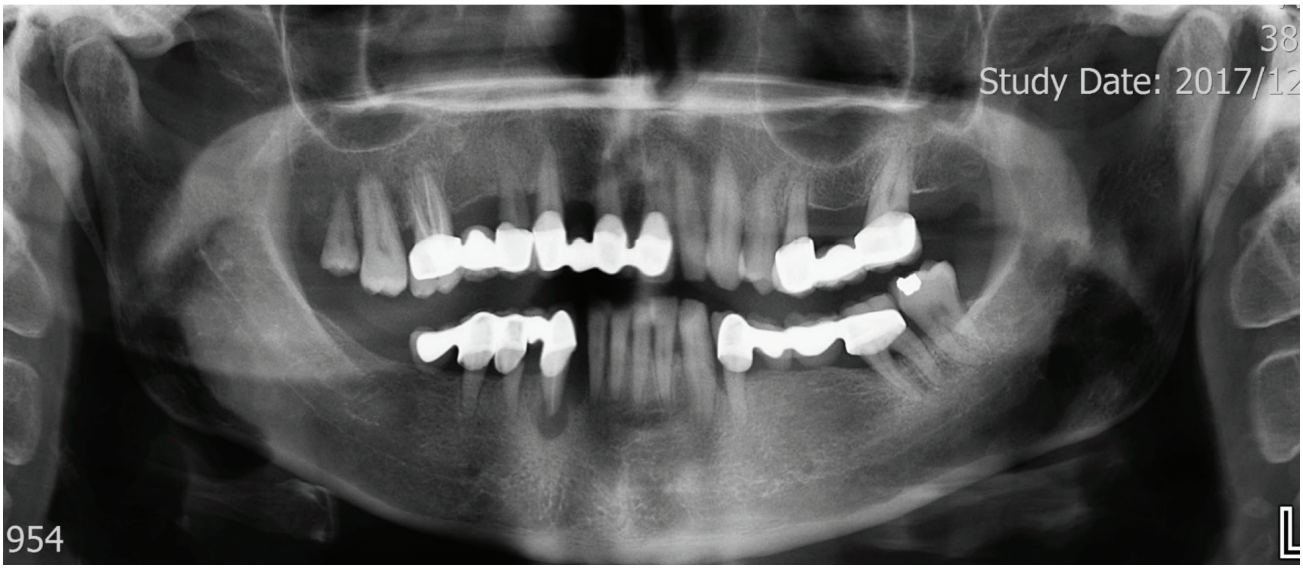

Figure 2. Radiographic view: Panoramic view shows scalloped depression in underlying mandibular crest between right lateral incisor and canine teeth.

the mandibular crest in the same region (Figure 2).

Incisional bioipsy was carried out. The microscopic examinations of the specimen showed malignant neoplasm composed of proliferation of large epithelioid cells with eosinophilic and clear cytoplasm arranged in small sheets, islands, and nests with occasionally comedo type necrosis (Figure 3). The tumoral cells showed severe pleomorphism and numerous atypical mitotic figures. Numerous gland-like structures were evident in the tumoral tissue (Figure 3). Small nests and single cells of tumoral tisuue occupied deep connective tissue between the regional muscular fibers and adipose tissue. Perivascular and neural invasion were also evident.

These findings are consistent by adenocarcinoma, more probably, with the breast origin according to the patient's history. Therefore, immunohistochemistry examination was performed to confirm the diagnosis. The tumoral cells showed positive immunoreaction with GATA and Her2 and negative for ER and PR (Figure 4). These findings confirmed the diagnosis of metastatic carcinoma with the origin of previous breast cancer.

Whole lesion excision, due to the large size of the lesion and functional overlapping, was performed for the patient and chemotherapy began again. Unfortunately, the patient was succumbed to die after six months during the chemotherapy period, while another distant metastasis to brain was detected.

Discussion

Regarding the rarity and lack of pathognomonic signs and symptoms of metastatic lesions to the oral cavity, accurate and decisive diagnosis is challenging for clinicians.[5]

Cases of distant metastasis to the soft tissue of the oral cavity without involving the underlying bony structure are extremely rare. The most common primary sites are lung, kidney, liver, and gastrointestinal tract and breast cancer is not among the common primary sites, which can metastasize to the oral cavity soft tissue.[6] If breast cancer metastasis to oral cavity occurs, it is highly probable that it involves the bone primarily and then the soft tissue and metastasis with only involving the oral mucosa is extremely rare.[7] However, the majority of metastatic tumors to oral and maxillofacial region are adenocarcinomas, half of which approximately originate from breast.[8]

To the best of our knowledge, this case is the first case of breast metastasis to the oral soft tissue without the bone involvement primarily. Kechagias et al. reported a case of breast cancer metastasis to the mandibular gingiva but with mandibular and tooth invasion.[9] In the present case, mandibular involvement was in the manner of saucerization of the crest due to scalloping resorption of the alveolar bone.

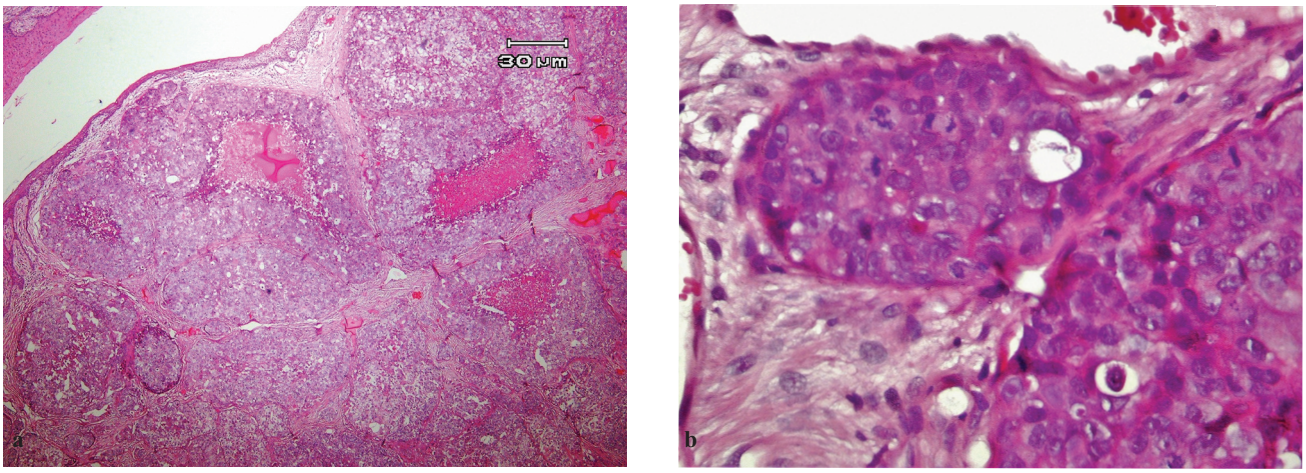

Figure 3. Histopathology features of the lesion: a: Islands and nests of tumoral cells with comedo type necrosis. Note encroachment to superficial epithelium of oral mucosa (H & E staining, 100× magnification). b: Numerous atypical mitosis features and duct structures in tumoral nests (H & E staining, 400× magnification).

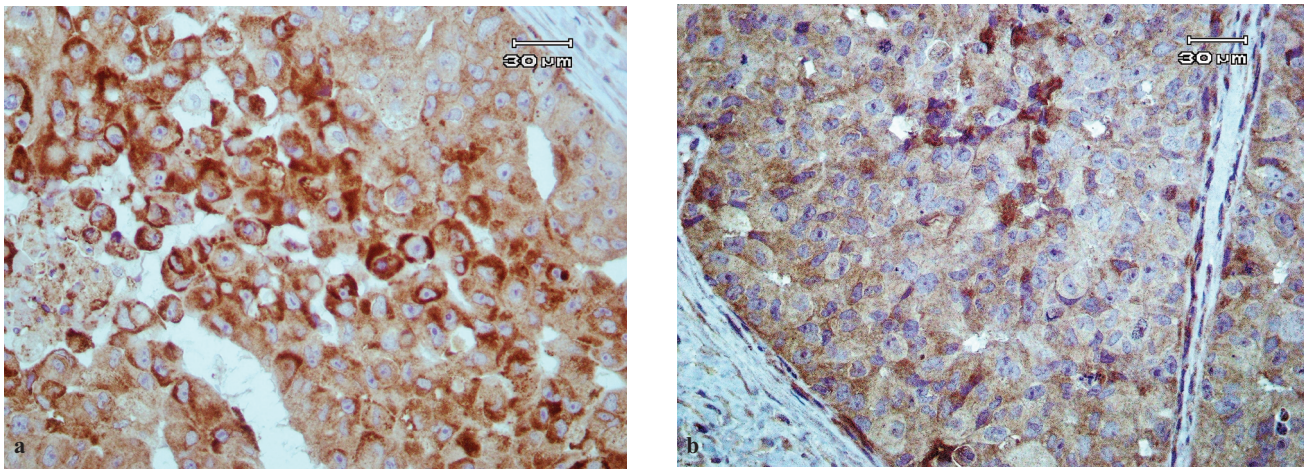

Figure 4. Immunohistochemistry views of the lesion: a) positive immunoreactivity for Her2 antibody in the cytoplasm of tumoral cells. b) positive immunoreactivity for GATA antibody in the cytoplasm of tumoral cells. (400× magnification).

It is common that patients with metastasis to oral cavity have metastasis to other sites.[10] Unfortunately, our patient also encountered brain metastasis.

In most cases of oral metastasis, the primary tumor has already been treated or diagnosed. However, sometimes, the presence of a lesion in oral cavity can lead to diagnosis of a distant tumor.[11] Our patient was diagnosed with a breast cancer eight years prior to the involvement of oral cavity and underwent treatment.[12]

The prognosis of oral metastatic lesions is poor, and an average survival period of several months is expected.[12]

Treatment of metastatic lesions is mainly palliative to improve the quality of life. Local excision is another treatment that can be performed, helping the patients to improve pain control and mastication and decreasing the bleeding and infection. Some patients may also benefit from radiotherapy or chemotherapy that may help them to control local symptoms for a few months.[13]

Conclusions

Metastasis to the oral cavity from distant primary sites is rare and the atypical signs and symptoms of the oral lesion lead to a delayed diagnosis and consequently, make the treatment ineffective. In treating patients with a history of malignancy, a multidisciplinary approach, a careful and precise examination, and a high degree of clinical suspicion are required.

Written Informed Consent

An informed signed consent based on only scientific use of the figures (without name) was obtained from the patient when she was alive.

Conflict of Interest

None declared.

References

1. Dib LL, Soares AL, Sandoval RL, Nannmark U. Breast metastasis around dental implants: a case report. *Clin Implant Dent Relat Res.* 2007;9(2):112-5.
2. Nandakumar A, Gupta PC, Gangadharan P, Visweswara RN, Parkin DM. Geographic pathology revisited: development of an atlas of cancer in India. *Int J Cancer.* 2005 20;116(5):740-54.
3. Akinbami BO. Metastatic carcinoma of the jaws: a review of literature. *Niger J Med.* 2009;18(2):139-42.
4. Benito-León J, Simón R, Miera C. Numb chin syndrome as the initial manifestation of HIV infection. *Neurology*. 1998;50(2):511-2.
5. Raja Lakshmi C, Sudhakara Rao M, Bhavana SM, Sathish S. Primary squamous cell carcinoma of lung leading to metastatic jaw tumor. *Case Rep Pulmonol.* 2014;2014:392616. doi: 10.1155/2014/392616.
6. Perlmutter S, Buchner A, Smukler H. Metastasis to the gingiva. Report of a case of metastasis from the breast and review of the literature. *Oral Surg Oral Med Oral Pathol.* 1974;38(5):749-54.
7. Meyer I, Shklar G. Malignant tumors metastatic to mouth and jaws. *Oral Surg Oral Med Oral Pathol.* 1965;20:350-62.
8. Derakhshan S, Rahrotaban S, Mahdavi N, Mirjalili

F. Metastatic renal cell carcinoma presenting as maxillary lesion: Report of two rare cases. *J Oral Maxillofac Pathol.* 2018;22(Suppl 1):S39-S43.

9. Kechagias N, Ntomouchtsis A, Patrikidou A, Christoforidou B, Andreadis C, Vahtsevanos K. Metastasis of a ductal breast carcinoma to the buccal mucosa of the mandible with tooth involvement. *Oral Maxillofac Surg.* 2012;16(4):377-81. doi: 10.1007/s10006-011-0300-y. Epub 2011 Nov 15.
10. van der Waal RI, Buter J, van der Waal I. Oral metastases: report of 24 cases. *Br J Oral Maxillofac Surg.* 2003;41(1):3-6.
11. Hirshberg A, Shnaiderman-Shapiro A, Kaplan I, Berger R. Metastatic tumours to the oral cavity - pathogenesis and analysis of 673 cases. *Oral Oncol.* 2008;44(8):743-52.
12. Sasaki H, Ohara N, Minamikawa T, Umeda M, Komori T, Kojima N, et al. Gingival metastasis from ovarian mucinous cystadenocarcinoma as an initial manifestation (a rare case report). *Kobe J Med Sci.* 2008 12;54(3):E174-82.
13. Hirshberg A, Berger R, Allon I, Kaplan I. Metastatic tumors to the jaws and mouth. *Head Neck Pathol.* 2014;8(4):463-74. doi: 10.1007/s12105-014-0591-z.