

## Association of Human Parvovirus B19 with Papillary Thyroid Carcinoma and its Relationship with Tumor Staging and Pathologic Features

Pardisa Archin Dialameh\*, MD, Forough Saki\*, MD, Ahmad Monabbati\*\*, MD, Amirreza Dehghanian\*\*, MD, Behnaz Valibeigi\*\*, PhD, Mahmood Soveid\*\*, MD

\*Endocrinology and Metabolism Research Center, Shiraz University of Medical Sciences, Shiraz, Iran

\*\*Department of Pathology, Shiraz University of Medical Sciences, Shiraz, Iran

Please cite this article as: Archin Dialameh P, Saki F, Monabbati A, Dehghanian A, Valibeigi B, Soveid M. Association of human parvovirus B19 with papillary thyroid carcinoma and its relationship with tumor staging and pathologic features. Middle East J Cancer. 2021;12(1):20-7. doi: 10.30476/mejc.2020.82810.1108.

### Abstract

**Background:** Papillary thyroid carcinoma (PTC) is the most prevalent form of thyroid cancer. In some studies, parvovirus B19 (PVB19) infection was involved in the pathogenesis of thyroid diseases such as Graves' disease, Hashimoto thyroiditis, and thyroid cancer. PVB19 induces chronic inflammation in thyroid, which can lead to carcinogenesis through the effect of inflammatory mediators. The association of PVB19 with PTC tumorigenesis is still a matter of controversy. We evaluated the correlation of PVB19 with PTC and, for the first time, pathologic features.

**Method:** This cross-sectional retrospective study focused on the thyroid specimens of 82 patients with PTC and 77 patients with benign thyroid nodules. We conducted the present study from March 2014 to November 2017 in the hospitals affiliated with Shiraz University of Medical Sciences, Shiraz, Iran. We evaluated the presence of PVB19 DNA by nested polymerase chain reaction method in PTC, adjacent non-malignant tissues, and benign thyroid nodules. PVB19 positivity was also compared between PTC and two other groups. We further investigated the association of pathologic features and tumor staging with PVB19 positivity.

**Results:** Of the patients, 81% were female. We detected PVB19 positivity in 9.8% of PTC specimens and 0.01 of adjacent non-malignant tissues ( $P=0.016$ ). None of the benign thyroid nodule specimens had PVB19 DNA, and they were significantly different from PTC specimens ( $P=0.007$ ). There was no significant correlation between PVB19 positivity and tumor stages ( $P=0.988$ ) and histologic types ( $P=0.560$ ).

**Conclusion:** This research, similar to some other studies, showed a significant association between PTC and PVB19 positivity. For the first time, we showed that no significant relationship existed between PVB19 positivity and tumor stages and histologic types. Further investigations are needed to evaluate the relationship between this virus and PTC.

**Keywords:** Human parvovirus B19, Papillary thyroid carcinoma, Thyroid cancer

### \*Corresponding Author:

Mahmood Soveid, MD  
Endocrinology and Metabolism  
Research Center, Shiraz  
University of Medical Sciences,  
Shiraz, Iran  
Tel/Fax: +98-711-6473096  
Email: msoveid@sums.ac.ir

## Introduction

Thyroid cancer is the most common endocrine system cancer.<sup>1</sup> Papillary thyroid carcinoma (PTC) comprises the greatest portion of follicular cell type of thyroid cancer.<sup>1, 2</sup> Several studies have been done to assess the etiology of this thyroid malignancy. Some investigations revealed the effects of radiation exposure, autoimmune diseases, and genetic alterations.<sup>1, 3</sup> Recently, more attention has been paid to the role of viral infections. Stamatiou et al. reviewed the association between thyroid cancer and two oncogenic virus families, namely the herpes and polyoma family viruses.<sup>1</sup> They detected the viral gene and gene products of EBV virus, polyoma virus, and herpes simplex virus type 1 and 2 in PTC tissues.<sup>1</sup> Two studies focused on the role of parvovirus B19 (PVB19) in the pathogenesis of thyroid cancer.<sup>3, 4</sup>

PVB19 is a small non-enveloped icosahedral DNA virus of the parvoviridae family. It has a single stranded linear DNA genome. PVB19 was previously shown to be a cause of diseases in animals, but in 1975, it was revealed that this virus could also be a human pathogen.<sup>5, 6</sup> This virus is the common cause of fifth disease and slapped cheek syndrome.<sup>7, 8</sup> Etemadi et al. suggested the association of PVB19 with thyroid cancer and tumorigenesis via inflammatory mechanisms.<sup>4</sup> Wang et al. reported the probable effect of PVB19 on the activation of NFκB (nuclear factor kappa light chain enhancer of activated B cells) as a mechanism for PTC development.<sup>3</sup> PVB19 gene codes three major proteins. NS1 is one of these proteins which is similar to the tax protein of human T-cell leukemia virus-1 (HTLV-1) and tat protein of human immunodeficiency virus type 1 (HIV). Tax and tat proteins are able to activate NFκB; once activated, NFκB plays a major role in the induction of acute leukemia by HTLV-1 and tumorigenesis of Kaposi sarcoma by HIV. NFκB is also activated in PTC and may play a role in its pathogenesis.<sup>3</sup> PVB19 causes chronic infection and dysregulates cell growth pathways in thyroid cells.<sup>4</sup> Another study revealed the presence of PVB19 in the

thyroid tissues of patients with autoimmune thyroid disorders and also proposed the role of hepatitis C virus in the pathogenesis of PTC.<sup>9</sup> Adamson et al. observed no significant difference between normal and cancerous thyroid tissues regarding the presence of PVB19.<sup>10</sup> Another study suggested the possible role of PVB19 in the tumorigenesis of more aggressive anaplastic thyroid carcinoma.<sup>11</sup>

We carried out this study due to the controversies as to the role of PVB19 infection in PTC and the lack of sufficient data concerning the association of PVB19 infection with PTC pathologic features. This study, which is the largest study of its kind, compared the human PVB19 infection in PTC vs. adjacent non-malignant tissues and benign thyroid nodules. In addition, it evaluated the association between this infection and the PTC stages and pathologic features.

## Material and Methods

We conducted this case-control retrospective investigation on tissue samples from March 2014 to November 2017 in the hospitals affiliated with Shiraz University of Medical Sciences, Fars province, southern Iran. Among the 159 specimens included in this study, 82 were PTC and 77 were benign thyroid nodule. 129 samples belonged to female patients, and the rest belonged to males. The mean age of PTC patients was  $40.7 \pm 14.9$  (range: 21-62) years, and that of patients with benign thyroid nodules was  $42.9 \pm 13.3$  (range: 23-60) years. 16 patients (19.5%) in PTC group and 14 (18%) in benign thyroid nodule group were male.

### Tissue samples

We collected a total of 175 paraffin-embedded thyroid tissues from patients with PTC and non-malignant thyroid disease. Two thyroid pathologists (Dr. Monabbati and Dr. Dehghani) re-assessed the specimens to confirm the diagnosis. Patient charts were checked to ensure that patients had not undergone radiation or chemotherapy and were not immune-compromised. We excluded 16 samples with

Hashimotos thyroiditis and Graves' disease. Finally, 82 PTCa and 77 benign thyroid nodules were included.

### *Tumor staging and pathologic criteria*

Based on world health organization (WHO) criteria,<sup>12</sup> we categorized the PTC histological types into six groups, encapsulated follicular variant, infiltrative follicular type, classic type, tall cell variant, cribriform, and diffuse sclerosing type. Tumor staging classification was according to the eighth edition of American Joint Committee on Cancer (AJCC) TNM system,<sup>13</sup> and pathologic features were assessed by the criteria of the College of American Pathologists.<sup>14</sup> All of the PTC pathologic characteristics were assessed as below:

Mitosis was evaluated according to the number of mitosis in 10 high-power fields. Tumor necrosis and mitotic rate  $>2$  mitosis/10 high power fields demonstrates worse survival than tumors without necrosis and lower mitotic rate in papillary thyroid carcinoma.

Atypia was defined based on the presence of pleomorphism, hyperchromasia, and increased nuclear to cytoplasmic ratio.

Diameter referred to the greatest dimension of tumor in mm.

Tumor encapsulation was determined as a distinct fibrotic capsule surrounding the tumor in specimen.

Vascular invasion was defined as tumor's invasion of the adjacent blood vessels.

Lymphatic invasion referred to the tumor tissue's invasion of lymphatic vessels.

Capsular invasion was tumor's invasion of its capsule.

Extrathyroidal extension was defined when the thyroid tumor invades peri-thyroidal soft tissues.

Surgical margin: a positive surgical margins means that the tumor extended the surgical resection edge.

Tumor multicentricity was defined as multiple foci of tumor in the same thyroid tissue of specimen.

Lymph node involvement referred to lymph

node invasion by malignant thyroid cells.

### *Ethics*

The Ethics Committee and Vice-Chancellor for Research of Shiraz University of Medical Sciences (ethics code:1396 S 90) approved this study.

### *Statistical analysis*

Statistical analysis was performed using SPSS software (version 21.0, Chicago, IL, USA). Using chi-square test, we compared PVB19 positive tests in PTC and benign thyroid nodules and adjacent non-tumoral tissues. We employed chi-square test or Fisher's exact test to examine the association between the pathologic features of PTC and the presence of PVB19. To compare quantitative variables such as age and tumor diameter, we employed independent sample t-test and Mann-Whitney non-parametric test. *P*-values less than 0.05 were statistically significant.

### *DNA extraction*

Sections previously deparaffinised by adding xylene and rehydration by ethanol (70%to100%) were cut in 5 $\mu$ m thickness. Genomic DNA was extracted with a commercially available kit using the manufactures protocols (prime prep Genomic DNA isolation kit made in South Kora). After DNA extraction, we determined the quantity of DNA by use of a spectrophotometer (BioRad, USA). In PTC specimens, a sample was also taken from the adjacent non-tumoral tissue and prepared for DNA extraction.

### *nPCR amplification*

We amplified the DNA from all samples by polymerase chain reaction (PCR) using a set of Beta-actin gene primer to assess DNA integrity with forward primer 5'ATCATGTTGAGACCTC-CAA-3' and reverse primer 5'CATCTCTTGCTCGAAGTCCA-3'.<sup>15</sup> The PCR reaction was performed with a final volume of 25 $\mu$ l, which contained reaction buffer 1.5 mM MgCl<sub>2</sub>, 0.5 unit of Taq DNA polymerase (Genet Bio, Korea),

200 $\mu$ M dNTP mix, 0.2  $\mu$ M of each primer, and 250 ng DNA. The reaction produced 317 base pair fragments. The PCR condition was preheated to 94°C for 5min, followed by 40 cycles 94°C for 1 min, 48°C for 45, and 72°C for 30 seconds. Two sets of primers were used for nested PCR (Table 1).<sup>16</sup> PCR condition is shown in table 1.

The first round PCR was carried out with set 1 primer as follows: total volume of 25 $\mu$ l containing 1x PCR buffer 200  $\mu$ M dNTP mix, 1.5 mM Mgcl<sub>2</sub>, 1 unit of Taq DNA polymerase (Genet Bio, Korea), 0.4  $\mu$ M of each primer, and 250 ng purified DNA as template. The second round PCR was performed with set 2 primers as follows: 1x buffer, 1.5 mM Mgcl<sub>2</sub>, 1 unit Taq DNA polymerase, 400 $\mu$ M dNTP mix, 0.4  $\mu$ M each primers, and 3 $\mu$ l of amplicon of first round PCR and water was added up to total volume of 25  $\mu$ l. All PCRs were performed in thermal cyclers (applied Biosystem, Foster CA, USA).

Each amplification run included one positive control (peripheral blood of patients with pure red cell aplasia infected with PVB19 virus analysed earlier by nPCR), and two negative controls comprised of water and blood samples of adult patients with chronic myelogenous leukemia.

## Analysis

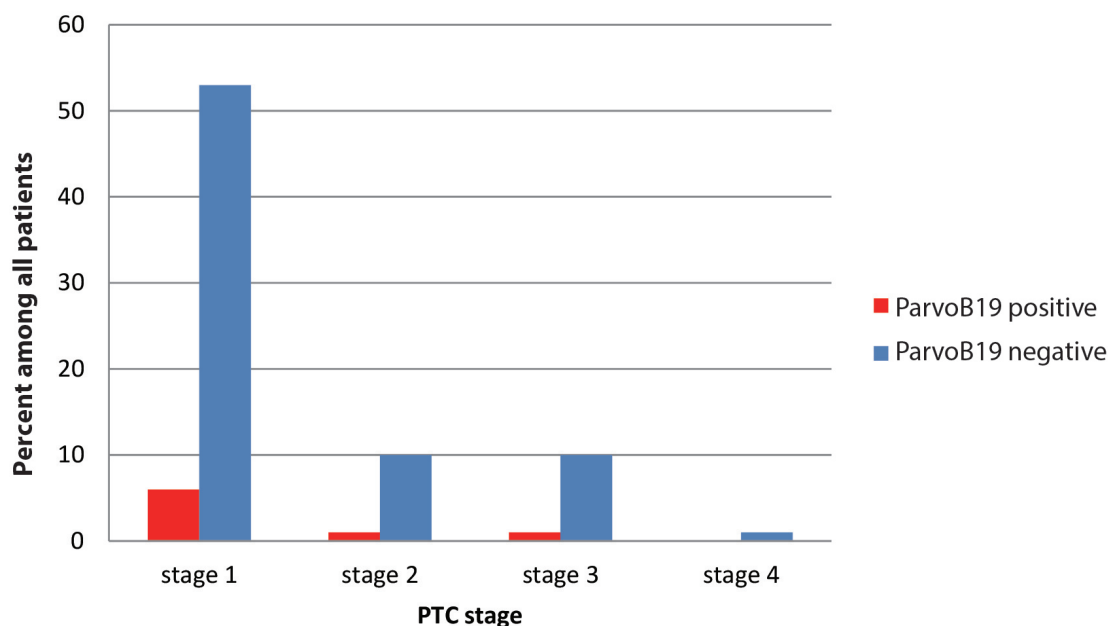
All amplified products (first and second reactions) were performed on 2.5% agarose gel in 1x TAE buffer stained with EcoDye nucleic Acid staining (Biofact, Korea) and visualized under UV illumination using gel doc (Uvtec made in EU).

## Results

Among the 159 specimens included in this study, 82 were PTC and 77 were benign thyroid nodules. 129 samples belonged to female patients, and 30 samples were obtained from male patients. The mean age of PTC patients was 40.7 $\pm$ 14.9 years, and that of patients with benign thyroid nodules was 42.9 $\pm$ 13.3 years ( $P=0.15$ ).

DNA of PVB19 was detected in eight cases of PTC with a prevalence of 9.8%. None of the benign thyroid nodule specimens was positive for PVB19, and the difference was significant ( $P=0.007$ ). PVB19 PCR was positive in one adjacent non-tumoral tissue (0.01%), and the prevalence of PVB19 PCR positivity was significantly lower than PTC group ( $P=0.016$ ).

Table 2 shows the association of PVB19 positivity and the pathologic features of patients with papillary thyroid carcinoma. As shown in



**Figure 1.** Prevalence of patients within 4 PTC tumor stage, considering the result of ParvoB19 PCR.  
PTC: papillary thyroid carcinoma, ParvoB19: parvovirus B19, PCR: polymerase chain reaction

**Table 1.** Primer sequences and PCR protocol

Primer	Sequence	Size of production	PCR condition
Beta-Actin	F:5'-ATCATGTTGAGACCTCCAA-3'	317 bp	94°C 5 min
	R:5'-CATCTCTTGCTCGAAGTCCA-3'		94°C 1 min 50°C 45 sec 40X 72°C 45 sec 72°C 5 min
SET 1	F:5'AGCATGTGGAGTGAGGGGGC-3'	290 bp	94°C 3 min
	R:5'AAAGCATGAGGAGCTATACTTCC-3'		94°C 1 min 53°C 45 sec 35X 72°C 45 sec 72°C 5 min
SET 2	F:5'GCTAACTCTGTAACCTGTAC-3' R:5'AAATATCTCCATGGGGTTGAG-3'	173 bp	

PCR: polymerase chain reaction, bp: base pair, X: cycles, F: forward primer, R: reverse primer, min: minute, sec: second, A: adenine, T: thymine, C: cytosine, G: guanine

table 2, the percentage of high mitosis rate, atypia, and blood vessel invasion in PVB19-positive PTC was higher than PVB19-negative PTC; also, the percentage of tumor encapsulation in the PVB 19 positive PTC was less than the PVB19 negative PTC but these differences were not statistically significant.

Among the 82 tissue samples of PTC, 72% were in stage I, 13.4% were in stage II, 13.4% were in stage III, and 1.2% was in stage IV (Figure 1). Statistical analysis indicated no significant association between PVB19 positivity and tumor stages ( $P=0.988$ ).

Histologically, 56% of the PTCs were of classical types, 32.2% were of follicular type, and 14.6% were micro PTCs. The prevalence of oncocytic type, Warthin type, tall cell, and sclerosing type were 2.4%, 1.2%, 1.2% and 1.2%, respectively. No significant association was observed between PTC types and PVB19 positivity ( $P=0.56$ ).

## Discussion

As the largest research in this field, our study included 82 PTC specimens and 77 benign thyroid nodules as the control group. We found PVB19 more frequently in tissues involved by PTC compared with adjacent non-tumoral and benign thyroid nodules. Although it is difficult to confirm a causative role for a viral infection in cancer development, we postulate that PVB19 infection

may be associated with certain cases of PTC.

This investigation, for the first time, examined the relationship between PVB19 infection and PTC considering staging criteria and pathologic features. Indicators of tumor aggressiveness such as high rates of mitosis, atypia, and blood vessel invasion tended to be related to PVB19 positivity in the present study. Our findings are in line with some other studies,<sup>3,4</sup> where a correlation was observed between PVB19 infection and PTC. In our study, the rates of PVB19 positivity in the control groups and PTC specimens were lower than other similar studies; this might be attributed to the differences in the methods of detecting PVB19 in tissue or lower rates of PVB19 infection in our study population.

Human PVB19 is a DNA virus and can incorporate into host genome, and is suspected to be involved in carcinogenesis. Some studies revealed the probable role of PVB19 in the development of non-thyroidal cancers, including acute lymphoblastic leukemia (ALL), colon carcinoma, and testicular germ cell tumours.<sup>17-20</sup> In two studies, no significant association existed between PVB19 and ALL development.<sup>21, 22</sup> Although PVB19 antibody is prevalent in adult population, viral DNA rarely persists in tissues.<sup>23</sup>

Several studies proposed a link between Human PVB19 and non-malignant thyroid diseases such as Hashimoto thyroiditis.<sup>9, 11, 24, 26</sup> Fallahi et al. proposed the role of PVB19 in the development

**Table 2.** Association between PVB19 PCR positive results and pathologic characteristics of patients with papillary thyroid carcinoma

Pathologic characteristic	PVB19 positive papillary thyroid carcinoma	PVB19 negative papillary thyroid carcinoma	P-value
Number	8	74	—
High mitosis: n(%)	1(12.5)	7(9.5)	0.78
Atypia: n(%)	1(12.5)	5(6.8)	0.47
Encapsulation: n(%)	4(50)	45(60.8)	0.40
Capsular invasion: n(%)	1(12.5)	28(37.8)	0.15
Lymph vessel invasion: n(%)	2(25)	20(27)	0.63
Blood vessel invasion: n(%)	2(25)	17(23)	0.59
Extra thyroid extension: n(%)	0(0)	12(16.2)	0.26
Surgical margin involvement: n(%)	0(0)	7(9.5)	0.47
Multicentric tumor: n(%)	1(12.5)	18(24.3)	0.40
Lymph node involvement: n(%)	0(0)	10(13.5)	0.33
Diameter of tumor(mm)	31.4mm	42.5mm	0.20

PVB19: parvovirus B19; PCR: polymerase chain reaction

of Graves' disease and multinodular goiter.<sup>9</sup>

Another group of studies evaluated the effect of PVB19 in the development and progression of thyroid cancers.<sup>3, 4, 9, 11, 26</sup> Laura et al. reported the probable role of PVB19 infection in the development of highly-aggressive anaplastic thyroid carcinoma.<sup>11</sup> Wang et al. reported a relationship between PVB19 infection and PTC. They studied 38 PTCs and 16 normal thyroid specimens, detected DNA fragments of PVB19 in 37 of PTCs and seven of normal thyroid tissues, and suggested the possible role of PVB19 in the pathogenesis of PTC.<sup>3</sup> Etemadi et al. detected the DNA particles of PVB19 in 86.1% of 36 PTC specimens and proposed that PVB19 infection might be involved in the pathogenesis of thyroid cancer via inflammatory factors.<sup>4</sup> Laura et al., on the other hand, observed no significant difference between benign and cancerous thyroid tissues concerning PVB19 DNA positivity.<sup>10</sup> In two other studies, no significant difference existed between normal and cancerous thyroid specimens regarding PVB19 capsid protein detection.<sup>11, 27</sup>

Multiple mechanisms were suggested for the involvement of PVB19 infection in thyroid tumorigenesis. PVB19 needs specific receptors to infect the cells. Thyroid follicular cells have globoside receptors, to which PVB19 particles can attach, thereby infecting the cells.<sup>28</sup> PVB19 infection in thyroid can be persistent and activate inflammatory cascade in thyroid cells, hence become a factor in cancer development.<sup>4</sup> The

NS1 protein of PVB19 is capable of activating NFkB, which is a mediator of viral tumorigenesis.<sup>3</sup> NFkB activates cellular promoters, such as HIV-long terminal repeat (HIV-LTR), interleukin 6, and tumor necrosis factor alpha. Interleukin 6 is a tumor promoter cytokine.<sup>4</sup> NFkB level is high in PTC cells and plays an important role in PTC pathogenesis as it affects the proliferative and apoptotic pathways in thyroid cells. Reactive oxygen nitrogen species (RONS) also increases in thyroid cells infected with PVB19.<sup>4</sup> RONS can cause DNA changes and mutations, thereby damaging tumor suppressor genes and activating proto-oncogenes.<sup>4</sup> Common mutations in PTC are BRAFV600E, RET/PTC rearrangement, and RAS mutations. P53 mutation is prevalent in anaplastic carcinoma, which usually originates from PTC. The interaction between PVB19 and oncogenes is yet another possible mechanism for PVB19 thyroid tumorigenesis. Detection of PVB19 is associated with P53 expression, which is a common mutation in anaplastic thyroid tumor.<sup>11, 29</sup> Ignatovich et al. showed that PVB19 infection down-regulated thyroid hormone receptor alpha (THR $\alpha$ ) and retinoid x receptor alpha (RXRA), which affected the expression of the genes regulated by THR/RXRA. These genes are involved in thyroid tumorigenesis.<sup>30</sup> Taken together, PVB19 may be involved in PTC pathogenesis through causing chronic inflammation and DNA damage and dysregulating the cell growth pathways.

The strength of the current study is that its sample size is larger than other similar studies. In addition, for the first time, we evaluated the association between PVB19 positivity and pathologic characteristics of PTC. On the other hand, due to the limitations in our laboratory, we were only able to perform PCR and no other methods, such as in situ hybridisation or immunohistochemistry for the detection of PVB19, which may account for lower rates of infection in our PTC and control samples.

## Conclusion

This study revealed an association between PVB19 and PTC. Although it is difficult to prove the role of a virus in cancer development, our results suggested that PVB19 might be involved in the pathogenesis of certain cases of PTC, which requires further studies.

## Acknowledgements

The authors would like to thank the staff of the Pathology Department of Shiraz University of Medical Sciences for their cooperation in the collection of our samples.

## Conflict of Interest

None declared.

## References

1. Stamatiou DP, Deras SP, Zoras OL, Spandidos DA. Herpes and polyoma family viruses in thyroid cancer. *Oncol Lett.* 2016 ;11(3): 1635-44. doi: 10.3892/ol.2016.4144.
2. Nikiforov YE. Molecular analysis of thyroid tumors. *Mod Pathol.* 2011; 24 (Suppl 2):S34-43. doi: 10.1038/modpathol.2010.167.
3. Wang JH, Zhang WP, Liu HX, Wang D, Li YF, Wang WQ, et al. Detection of human parvovirus B19 in papillary thyroid carcinoma. *Br J Cancer.* 2008;98(3): 611-8. doi: 10.1038/sj.bjc.6604196.
4. Etemadi A, Mostafaei S, Yari K, Ghasemi A, Minaei Chenar H, Moghoofei M. Detection and a possible link between parvovirus B19 and thyroid cancer. *Tumour Biol.* 2017; 39(6):1010428317703634. doi: 10.1177/1010428317703634.
5. Cossart YE, Field AM, Cant B, Widdows D. Parvovirus-like particles in human sera. *Lancet.* 1975;1(7898):72-3.
6. Young NS, Brown KE. Parvovirus B19. *N Engl J Med.* 2004; 350 (6):586-97. doi:10.1056/NEJMra030840.
7. Vafaie J , Schwartz RA. Parvovirus B19 infections. *Int J Dermatol.* 2004;43(10):747-9. doi:10.1111/j.1365-4632.2004.02413.x .
8. Sabella C, Goldfarb J. Parvovirus B19 infections. *Am Fam Physician.* 1999;60(5):1455-60.
9. Fallahi P, Ferrari SM, Vita R, Benvenga S, Antonelli A. The role of human parvovirus B19 and hepatitis C virus in the development of thyroid disorders. *Rev Endocr Metab Disord.* 2016;17(4):529-35. doi: 10.1007/s11154-016-9361-4.
10. Adamson LA, Fowler LJ, Ewald AS, Clare-Salzler MJ, Hobbs JA. Infection and persistence of erythrovirus B19 in benign and cancerous thyroid tissues. *J Med Virol.* 2014;86(9):1614-20. doi: 10.1002/jmv.23852.
11. Adamson LA, Fowler LJ, Clare-Salzler MJ, Hobbs JA. Parvovirus B19 infection in Hashimoto's thyroiditis, papillary thyroid carcinoma, and anaplastic thyroid carcinoma. *Thyroid.* 2011;21(4):411-7. doi: 10.1089/thy.2010.0307.
12. DeLellis RA, Lloyd RV, Heitz PU. Pathology and genetics of tumours of endocrine organs. WHO Classification of Tumours, 3<sup>rd</sup> ed. Volume 8. France, Lyon:IARC Press;2004.
13. Tuttle RM, Haugen B, Perrier ND. Updated American Joint Committee on cancer/tumor-node-metastasis staging system for differentiated and anaplastic thyroid cancer (Eighth edition): What changed and why? *Thyroid.* 2017;27(6):751-6. doi: 10.1089/thy.2017.0102.
14. Ghossein R . Update to the College of American Pathologists reporting on thyroid carcinomas. *Head Neck Pathol.* 2009;3(1):86-93.doi: 10.1007/s12105-009-0109-2.
15. Valibeigi B, Ashraf MJ, Kerdegari N, Safai A, Abedi E, Khademi B, et al. Prevalence of human papilloma virus in sinonasal papilloma in southern Iranian population. *J Dent (Shiraz).* 2017;18 (2):143-8.
16. Bültmann BD, Klingel K, Sotlar K, Bock CT, Baba HA, Sauter M, et al. Fatal parvovirus B19-associated myocarditis clinically mimicking ischemic heart disease: an endothelial cell-mediated disease. *Hum Pathol.* 2003;34(1):92-5. doi:10.1053/hupa.2003.48.
17. da Conceição Nunes J, de Araujo GV, Viana MT, Sarinho ES. Association of atopic diseases and parvovirus B19 with acute lymphoblastic leukemia in childhood and adolescence in the northeast of Brazil. *Int J Clin Oncol.* 2016;21(5):989-95.
18. Diss TC, Pan LX, Du MQ, Peng HZ, Kerr JR. Parvovirus B19 is associated with benign testes as well as testicular germ cell tumours. *Mol Pathol.* 1999;52 (6):349-52.
19. Li Y, Wang J, Zhu G, Zhang X, Zhai H, Zhang W, et al. Detection of parvovirus B19 nucleic acids and expression of viral VP1/VP2 antigen in human colon

- carcinoma. *Am J Gastroenterol.* 2007;102(7):1489-98. doi:10.1111/j.1572-0241.2007.01240.x.
20. Gray A, Guillou L, Zufferey J, Rey F, Kurt AM, Jichlinski P, et al. Persistence of parvovirus B19 DNA in testis of patients with testicular germ cell tumours. *J Gen Virol.* 1998;79(Pt 3):573-9. doi:10.1099/0022-1317-79-3-573.
  21. Bogdanovic G, Pou C, Barrientos-Somarribas M, Bjerckner A, Honkaniemi E, Allander T, et al. Virome characterisation from Guthrie cards in children who later developed acute lymphoblastic leukaemia. *Br J Cancer.* 2016;115(8):1008-14. doi: 10.1038/bjc.2016.261.
  22. Isa A, Priftakis P, Broliden K, Gustafsson B. Human parvovirus B19 DNA is not detected in Guthrie cards from children who have developed acute lymphoblastic leukemia. *Pediatr Blood Cancer.* 2004;42(4):357-60. doi:10.1002/pbc.20001.
  23. Heegaard ED, Brown KE. Human parvovirus B19. *Clin Microbiol Rev.* 2002;15(3):485-505.
  24. Mori K, Munakata Y, Saito T, Tani J, Nakagawa Y, Hoshikawa S, et al. Intrathyroidal persistence of human parvovirus B19 DNA in a patient with Hashimoto's thyroiditis. *J Infect.* 2007;55(2):e29-31. doi 10.1016/j.jinf.2007.05.173.
  25. Lehmann HW, Lutterbüse N, Plentz A, Akkurt I, Albers N, Hauffa BP, et al. Association of parvovirus B19 infection and Hashimoto's thyroiditis in children. *Viral Immunol.* 2008;21(3): 379-83. doi: 10.1089/vim.2008.0001.
  26. Page C, Duverlie G, Sevestre H, Desaillood R. Erythrovirus B19 and autoimmune thyroid diseases. Review of the literature and pathophysiological hypotheses. *J Med Virol.* 2015;87(1):162-9. doi: 10.1002/jmv.23963.
  27. Page C, Hoffmann TW, Benzerdjeb N, Duverlie G, Sevestre H, Desaillood R. Detection of erythrovirus B19 in thyroidectomy specimens from Graves' disease patients: a case-control study. *J Med Virol.* 2013;85(8):1414-9. doi: 10.1002/jmv.23595.
  28. Bouchon B, Portoukalian J, Bornet H. Alterations of the cerebroside fraction of human thyroid glycosphingolipids in Graves disease. *Biochem Int.* 1985;11:415-24.
  29. Sadahira Y, Sugihara T, Yawata Y. Expression of p53 and Ki-67 antigen in bone marrow giant proerythroblasts associated with human parvovirus B19 infection. *Int J Hematol.* 2001; 74(2):147-52.
  30. Ignatovich IV, Hobbs JA. Human parvovirus B19 infection leads to downregulation of thyroid, estrogen, and retinoid hormone receptor expression. *Virology.* 2013;446(1-2):173-9. doi: 10.1016/j.virol.2013.06.022.