

## Primary Diffuse Large Cell Lymphoma of the Bladder: Case Report and Literature Review

Mansour Ansari\*, Hamid Nasrollahi\*\*\*, Majdaddin Rajaei\*\*, Maral Mokhtari\*\*\*\*, Seyed Hasan Hamedii\*\*, Mohammad Mohammadianpanah\*\*\*\*, Shapour Omidvari\*, Ahmad Mosalaei\*\*\*\*\*, Niloofar Ahmadloo\*\*\*\*

\*Breast Diseases Research Center, Shiraz University of Medical Sciences, Shiraz, Iran

\*\*Department of Radiation Oncology, Shiraz University of Medical Sciences, Shiraz, Iran

\*\*\*Department of Pathology, Shiraz University of Medical Sciences, Shiraz, Iran

\*\*\*\*Colorectal Research Center, Shiraz University of Medical Sciences, Shiraz, Iran

\*\*\*\*\*Shiraz Institute for Cancer Research, Shiraz University of Medical Sciences, Shiraz, Iran

### Abstract

Most bladder tumors are epithelial in origin. Nonepithelial cancers are rarely located in the bladder. Sarcomas are the most common malignancies among nonepithelial cancers. Primary bladder lymphoma is rare and mostly low grade. Here, we have reported a case of diffuse large cell lymphoma of the bladder. The patient, a 64-year-old man, had urinary frequency for 18 months. Abdominal sonography indicated a thick bladder wall and transurethral biopsy showed diffuse large cell lymphoma. Immunohistochemistry (IHC) results showed that the tumor was positive for CD20, CD45, and Pax-5 and negative for BCL-2, cytokeratin, and S100. He had a normal bone marrow biopsy, abdominal, pelvic and chest CT scans. He had no B symptoms. The patient received 6 cycles of R-CHOP followed by radiotherapy (36 Gy) to the pelvis. Six months after treatment, the patient is well and has returned to work. We have searched PubMed for primary diffuse large cell lymphoma. Primary diffuse large cell lymphoma of the bladder is best treated according to treatment for diffuse large cell lymphoma of other sites, which includes chemotherapy and radiotherapy. As seen in our review, primary diffuse large cell lymphoma of the bladder has a similar clinical course to diffuse large cell lymphoma of other sites.

**Keywords:** Bladder, Lymphoma, Treatment

#### \*Corresponding Author:

Hamid Nasrollahi, MD  
Department of Radiation  
Oncology, Shiraz University of  
Medical Sciences, Shiraz, Iran  
Tel/Fax: +987136474320  
Email: nasrolahiamid@yahoo.com



### Introduction

Most bladder tumors are epithelial in origin. Nonepithelial cancers are rarely located in the bladder. Leiomyosarcoma and rhabdomyosar-

coma are the most common malignancies among nonepithelial tumors. Leiomyosarcoma is the most common nonepithelial tumor in adults whereas rhabdomyosarcoma is most common in children.<sup>1,2</sup> Other

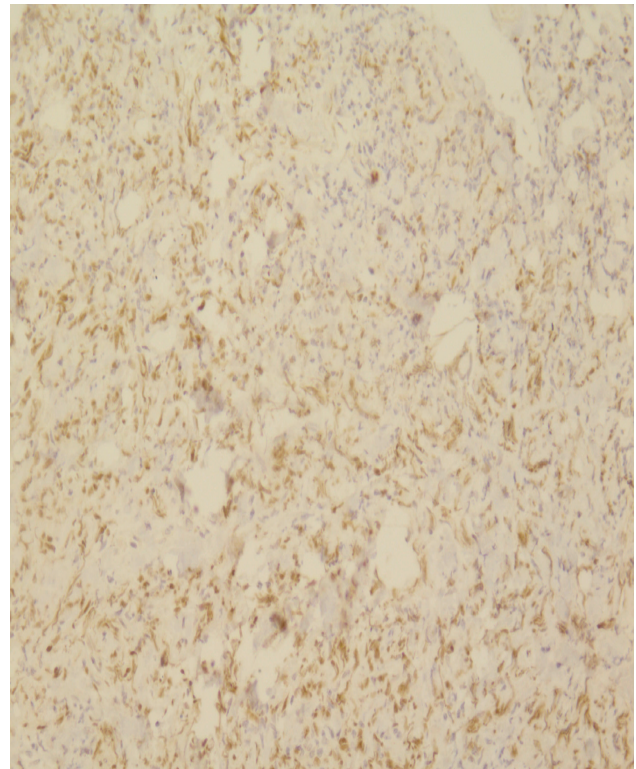
less common tumors include small cell carcinoma and lymphoepithelioma-like carcinoma. Treatment and outcome in these diseases differ.<sup>3</sup>

Lymphomas are common human cancers,<sup>4</sup> and treatment of NHL has changed in recent decades.<sup>5</sup> The most common subtype of lymphoma is diffuse large cell lymphoma (DLCL).<sup>6</sup> Diffuse large cell lymphomas are B cell lymphomas. Approximately one-third of NHL are DLCL.<sup>7</sup> Non-Hodgkin's lymphoma can originate from solid organs and are named extranodal lymphomas. Extranodal lymphomas account for one-third of lymphomas.<sup>6</sup> The skin, stomach, and connective tissue are the most common sites where extra nodal lymphomas can originate.<sup>4,5</sup>

We reported a rare case of primary DLCL of the bladder. In addition, we searched PubMed after 2000 because of recent changes and advances in diagnosis, treatment, and terminology.<sup>5</sup>

### Case Report

The patient, a 64-year-old-man, had urinary frequency for 18 months. He had no dysuria, nocturia or change in urine color. Serum PSA was 3.1 and he had normal renal function test, liver function test, and complete blood count. Urinalysis and urine cytology were normal. Abdominal and pelvic sonography showed bladder wall thickening. There were no significant findings in his history and physical examination. He had no smoking history and no history of exposure to toxins (industrial or chemical). He had no history of lymphoma in his family and no history of chronic disease. The patient underwent a transurethral biopsy and pathologic evaluations showed DLCL. Immunohistochemistry (IHC) study showed that the tumor was positive for CD20, CD45, and Pax-5,ki-67(60%) and negative for BCL-2, cytokeratin, and S100 (Figure 1-2). The abdominal and pelvic CT scan showed diffuse bladder wall involvement (Figure 3). There was no extra bladder involvement observed in the abdominal and pelvic CT scan and in the bone marrow biopsy. He had no B symptoms. The patient received 6 cycles of R-CHOP followed by 36 Gy radiotherapy to his pelvis. Six months after

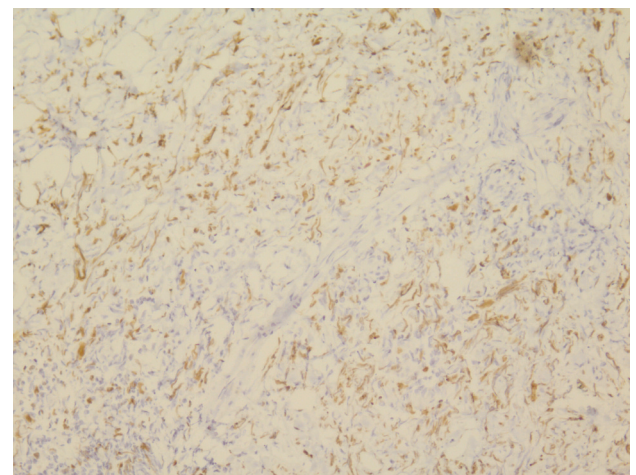


**Figure 1.** Immunoreactivity for PAX-5 shows nuclear staining of tumor cells (250×).

treatment, the patient has remained well. He had normal urinalysis and urine cytology results and has returned to work.

### Discussion

Urinary bladder lymphoma (UBL) is not common. In a study in Japan, only 1 case of UBL was found among 1767 cases of lymphoma.<sup>8</sup> The bladder may have either primary or secondary involvement by lymphoma<sup>9</sup> or widespread



**Figure 2.** Immunoreactivity for Ki-67 shows high proliferative index (250×).

lymphoma. Secondary bladder involvement occurs in 10%-20% of advanced lymphomas.<sup>6</sup> In advanced cases, prognosis is not good.<sup>9</sup> The bladder may also be involved by lymphoma at presentation in a non-localized lymphoma.<sup>9</sup> Most cases of secondary bladder involvement are detected during autopsy.<sup>10</sup> Bates et al. have reported 11 cases of UBL from 1929 to 1998. Among them, 5 patients had secondary UBL; in 4 cases diagnosis was made post mortem.<sup>10</sup>

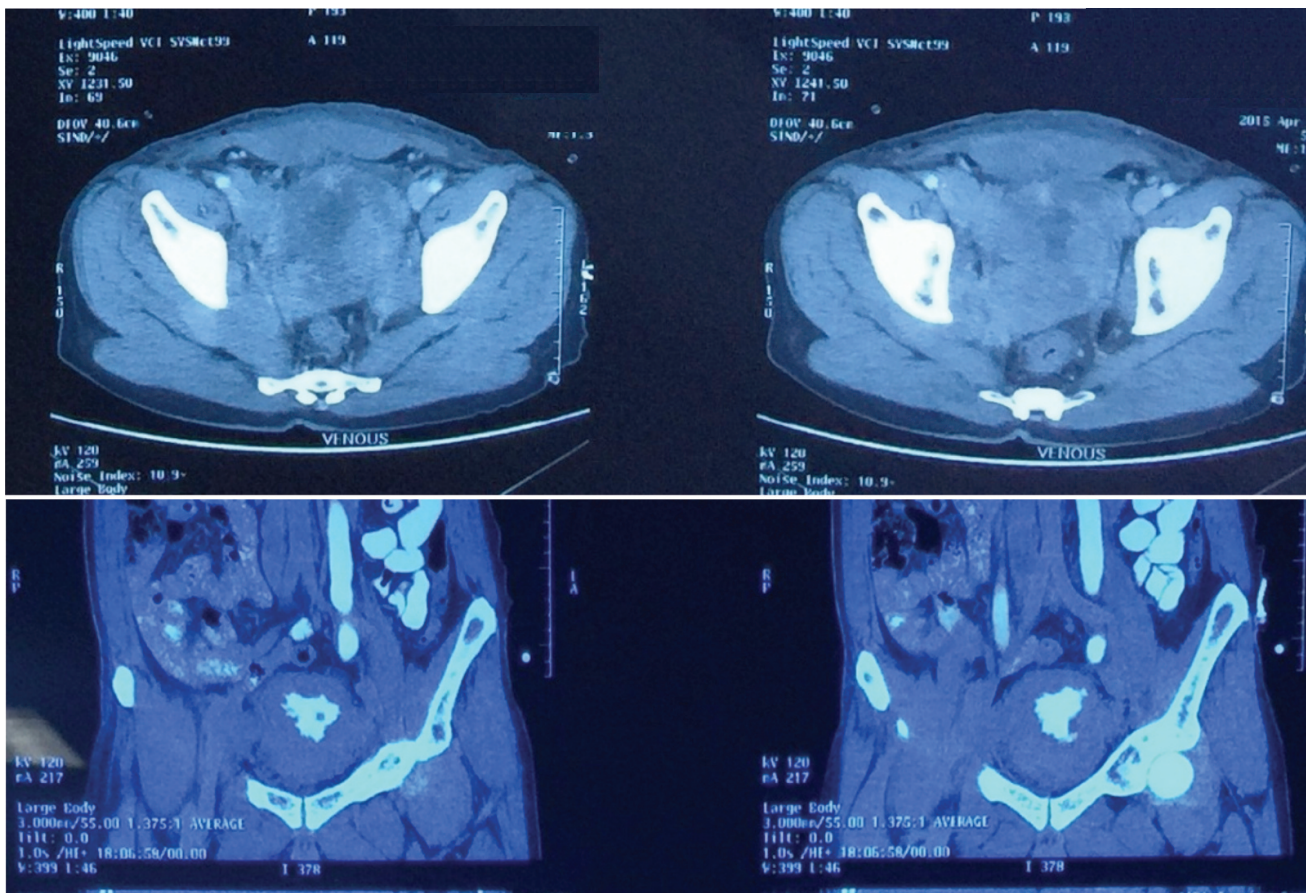
In primary lymphoma only the bladder is involved as the sole site.<sup>9</sup> Other organs in patients with primary UBL are tumor-free with no lymph node involvement. The bone marrow is also normal.<sup>11</sup> In our patient, all investigations, including chest, abdominal and pelvic CT scan and bone marrow biopsy were normal.

Most types of bladder lymphoma are low grade and have a favorable prognosis. High grade types are less common. Only one-fifth of primary UBL are DLCL.<sup>4</sup> Most primary bladder lymphomas

are mucosa-associated lymphoid tissue (MALT). While bladder is involved by a widespread lymphoma, most cases are DLCL.<sup>6</sup> Lymphoma in the bladder is usually a mass in the dome or lateral wall.<sup>4</sup> Most UBL are a single lesion. A total of 20% of cases had multiple lesions and only 10% had diffuse involvement of the bladder.<sup>12</sup> Our patient had an unusual involvement of the bladder wall. As seen in Figure 1, there was involvement in all of the bladder walls. A review of 30 cases by Oshawa et al. showed that only 2 cases had diffuse bladder involvement. Most (22 cases) had single lesions.<sup>8</sup>

The origin of primary UBL is not well known. Normal urinary bladder has no lymphoid follicle. Chronic cystitis may increase lymphoid tissue in the lamina propria after which a lymphoma might arise from these lesions.<sup>2,4</sup> Our patient had no history of urinary tract infection or any urinary problems.

In extranodal NHL men are affected more



**Figure 3.** Diffuse bladder wall thickening in abdominal CT scan.

frequently than women. However in primary thyroid and bladder lymphoma, women are affected more frequently than men. Women are affected twice more than men. Underlying inflammation or autoimmune conditions might have a role.<sup>4,8</sup> Our patient was a man, however in our review we have determined that most patients were women 13 and 7 were men (Table 1).

Age distribution of UBL is similar to extranodal lymphoma from other sites. In a review, the mean age was 65 years.<sup>8</sup> Our patient was 64 years old. We found 20 cases of primary DLCL of the bladder that were reported after year 2000 with a mean age of 69 years (Table 1). In some series, the high grade type affected younger patients compared to the low grades.<sup>4</sup>

The most common presenting symptom is hematuria.<sup>4,5</sup> In our review, 13 cases had hematuria (Table 1). Cystitis might be a predisposing factor for UBL.<sup>13</sup> In patients with primary UBL, history of cystitis is reported in 20% of them.<sup>10</sup> Our patient presented with urinary frequency which he attributed to prostate enlargement.

B symptoms (night sweats, 10% loss of body weight, fever) are seen in about 47% of high grade lymphomas and may be a poor prognostic factor. B symptoms correlate with stage and histology of lymphoma. In stage I, 22% of patients have evidence of B symptoms.<sup>14</sup> Coskun et al. reported the case of a 73-year-old woman with primary bladder lymphoma who had weight loss and night sweats.<sup>15</sup> Tasu et al. reported that a 70-year-old man had high grade lymphoma and weight loss.<sup>16</sup> We found no other cases with primary UBL and B symptoms. Our patient had no B symptoms.

Montironi et al. reported that an 81-year-old man had a 5 cm mass in his bladder. The lesion was diagnosed as DLCL with no other organ involvement. He received no treatment and was alive after 2 years.<sup>12</sup> Hughes et al. reported 4 cases with primary DLCL of the bladder. Notably, 1 of their patients responded to antibiotic therapy.<sup>5</sup> He was a 31-year-old man with a history of recurrent urinary tract infection (UTI) The patient received doxycycline and 1 month later he had a

normal cystoscopy. The patient remained well after 8 years. A review of the primary bladder pathology confirmed DLCL.<sup>5</sup> We found 2 cases that underwent surgery. One patient has undergone surgery due to poorly differentiated carcinoma.<sup>17</sup> Surgery can have a role in symptom relief but it is not curative.<sup>16</sup>

Regardless of these unusual cases, treatment of primary UBL is the same as nodal lymphoma.<sup>3</sup> Tasu et al. have reported the case of a 68-year-old man with bilateral hydronephrosis and acute renal failure. Their case had diffuse bladder involvement with obstruction and subsequent renal failure. He received chemotherapy and went into remission. After 5 months he developed local recurrence in the bladder. The patient has become disease-free following chemotherapy and radiotherapy.<sup>16</sup> Chemotherapy, radiotherapy, and combined treatment are the main therapeutic options. Surgery does not have a role in treatment.<sup>3</sup> Systemic chemotherapy is the first treatment for high grade lymphomas.<sup>18</sup> Standard treatment for stages I-II DLCL is R-CHOP and localized radiotherapy.<sup>7</sup> In our review, only 4 cases have received R-CHOP and none underwent radiotherapy (Table 1).

Hughes et al. reported 12 cases of primary UBL. None had B symptoms.<sup>5</sup> Among these 12 patients, 4 had DLCL. As mentioned above, 1 of their patients responded to antibiotic therapy.<sup>5</sup> Among these 4 patients, 1 case had a poor outcome. She was a 75-year-old woman who died from acute renal failure after chemotherapy with idarubicin, chlorambucil and prednisolone.<sup>5</sup> Although this report was published in 2005, the cases received treatment in the preceding years; 2 cases have received the cyclophosphamide, doxorubicin, vincristine and prednisolone (CHOP) regimen. Currently, anthracycline-containing chemotherapy (R-CHOP) is considered standard treatment for DLCL.<sup>7</sup>

## Conclusion

Primary DLCL of the bladder is best treated according to treatment for DLCL of other sites. Treatment includes chemotherapy and radiotherapy. The outcome is similar to other

**Table 1.** Reports on Primary UBL in PubMed in the English Language, from year 2000.

No.	Age years/sex	Presentation	Mass size of the tumor (cm)	Chemotherapy regimen	Radiotherapy	Survival months outcome
1 <sup>2</sup>	64/F	Hematuria	7	RCHOP	NM	NM
2 <sup>3</sup>	89/F	Obstruction	Diffuse involvement	CHOP	Not done	12 DOD
3 <sup>4</sup>	48/M	Gross hematuria	6.3	RCHOP	Not done	6 Alive
4 <sup>5</sup>	71/F	Hematuria	NM	CHOP	Not done	24 alive
5 <sup>5</sup>	31/M	Recurrent UTIs	NM	Doxycycline	Not done	96 alive
6 <sup>5</sup>	70/F	Hematuria	NM	CHOP	Not done	48 alive
7 <sup>5</sup>	75/F	Hematuria	NM	IchIP	Not done	NM, DOD
8 <sup>10</sup>	84/F	Hematuria	NM	Done,agent NM	Not done	6 DOD
9 <sup>10</sup>	67/M	Hematuria	NM	Done,agent NM	Done,dose NM	192 alive
10 <sup>10</sup>	80/F	Hematuria	NM	Not done	Done,dose NM	44 alive
11 <sup>12</sup>	81/M	Hematuria	5	Not done	Not done	24 alive
12 <sup>13</sup>	75/F	Oliguria	Diffuse involvement	RCHOP	Not done	NM, alive
13 <sup>15</sup>	73/F	Dysuria	NM	CHEP	Not done	10 DOD
14 <sup>16</sup>	68/M	Pain, Nocturia, Hematuria	NM	CHOP	Not done	17 alive
15 <sup>16</sup>	70/M	Wt. loss	NM	Mit, ifos	Not done	18 alive
16 <sup>17</sup>	55/M	Hematuria	NM	CHOP	Not done	18 DOD
17 <sup>18</sup>	65/F	Hematuria	4.5	CHOP	46 Gy	12 alive
18 <sup>19</sup>	60/F	Cystitis	NM	RCHOP	Not done	14 alive
19 <sup>20</sup>	75/F	Flank pain	6	NM	NM	NM
20 <sup>21</sup>	82/F	UTI Hematuria	NM	NM	NM	NM

F:Female, M: male, NM: not mentioned, R: rituximab, C: cyclophosphamide, H: doxorubicin, O: vincristine, P: prednisolone, mit: mitomycin, ifos: ifosfamide, I: idarubicin, chl: chlorambucil, E: epirubicin, Wt.: Weight, DOD: dead of disease

sites. As seen in our review, primary DLCL of bladder appears to have a similar clinical course.

## Acknowledgment

The authors would thank to Miss Valeh Mesbah for helping us to prepare this manuscript.

## Conflict of Interest

No conflict of interest is declared.

## References

- Nerli RB, Guntaka AK, Das S, Hiremath MB. Primary non-Hodgkin lymphoma of the bladder. *Indian J Cancer*. 2013;50(4):296.
- Evans DA, Moore AT. The first case of vesico-vaginal fistula in a patient with primary lymphoma of the bladder - a case report. *J Med Case Rep*. 2007;1:105.
- Leite KR, Bruschini H, Camara-Lopes LH. Primary lymphoma of the bladder. *Int Braz J Urol*. 2004;30(1):37-9.
- Simpson WG, Lopez A, Babbar P, Payne LF. Primary bladder lymphoma, diffuse large B-cell type: Case report and literature review of 26 cases. *Urol Ann*. 2015;7(2):268-72.
- Hughes M, Morrison A, Jackson R. Primary bladder lymphoma: management and outcome of 12 patients with a review of the literature. *Leuk Lymphoma*. 2005;46(6):873-7.
- Min J, Geng H, Yu D, Zhang T, Zhang Z. Malignant lymphoma occurring simultaneously in the urinary bladder wall and bilateral renal parenchyma: A case report. *Oncol Lett*. 2015;10(3):1579-82.
- Blum KA, Bartlett NL. Antibodies for the treatment of diffuse large cell lymphoma. *Semin Oncol*. 2003;30(4):448-56.
- Ohsawa M, Aozasa K, Horiuchi K, Kanamaru A. Malignant lymphoma of bladder. Report of three cases and review of the literature. *Cancer*. 1993;72(6):1969-74.
- Venyo AK. Lymphoma of the urinary bladder. *Adv Urol*. 2014;2014:327917.
- Bates AW, Norton AJ, Baithun SI. Malignant lymphoma of the urinary bladder: a clinicopathological study of 11 cases. *J Clin Pathol*. 2000;53(6):458-61.
- Díaz-Peromingo JA, Tato-Rodríguez J, Pesqueira-Fontán PM, Molinos-Castro S, Gayol-Fernández MC, Struzik JP. Non-Hodgkin's lymphoma presenting as a primary bladder tumor: a case report. *J Med Case Rep*. 2010;4:114.

12. Montironi R, Santoni M, Goteri G, Mazzucchelli R, Lopez-Beltran A, Cheng L, et al. Pseudocarcinomatous hyperplasia associated with primary lymphoma in the urinary bladder: a case report. *Hum Pathol.* 2015;46(7):1040-4.
13. Hayashi A, Miyakawa Y, Bokuda K, Kimura T, Nakashima E, Irie R, et al. Primary diffuse large B-cell lymphoma of the bladder. *Intern Med.* 2009;48(16):1403-6.
14. Anderson T, Chabner BA, Young RC, Berard CW, Garvin AJ, Simon RM, et al. Malignant lymphoma. 1. The histology and staging of 473 patients at the National Cancer Institute. *Cancer.* 1982;50(12):2699-707.
15. Coskun U, Günel N, Eroglu A, Biri H, Poyraz A, Gurocak S, et al. Primary high grade malignant lymphoma of bladder. *Urol Oncol.* 2002;7(5):181-3.
16. Tasu JP, Geffroy D, Rocher L, Eschwege P, Strohl D, Benoit G, et al. Primary malignant lymphoma of the urinary bladder: report of three cases and review of the literature. *Eur Radiol.* 2000;10(8):1261-4.
17. Khaitan A, Gupta NP, Goel A, Safaya R, Kumar L. Primary non-Hodgkin's lymphoma of urinary bladder. Report of a case and review of the literature. *Urol Int.* 2004;72(1):82-4.
18. Horasanli K, Kadihasanoglu M, Aksakal OT, Ozagari A, Miroglu C. A case of primary lymphoma of the bladder managed with multimodal therapy. *Nat Clin Pract Urol.* 2008;5(3):167-70.
19. Kawasaki T, Suzuki M, Sato A, Yashima-Abo A, Satoh T, Kato R, et al. Neural cell adhesion molecule (CD56)-positive B cell lymphoma of the urinary bladder. *J Clin Pathol.* 2016;69(1):89-92.
20. Khurana A, Kamboj M, Mehta A. Primary diffuse large B-cell lymphoma of the urinary bladder mimicking a clear cell variant of an infiltrating urothelial carcinoma. *Indian J Pathol Microbiol.* 2010;53(4):879-80.
21. Mantzarides M, Papathanassiou D, Bonardel G, Soret M, Gontier E, Foehrenbach H. High-grade lymphoma of the bladder visualized on PET. *Clin Nucl Med.* 2005;30(7):478-80.