

A Desmoplastic Small Round Cell Tumor in a Twenty-Eight Year-old Adult Male Presenting with Urological Symptoms

Amr Idris

Syrian Private University, Damascus Hospital, Damascus, Syrian Arab Republic

Abstract

A desmoplastic small round cell tumor is a malignant tumor of the abdominal and pelvic cavities. This tumor involves serosal surfaces such as the peritoneum, pleura, and scrotum. In this case report a 28-year old male presented with a desmoplastic small round cell tumor located in the abdomen along with urological symptoms. When the diagnosis was completed, the patient's tumor had metastasized to the liver and retroperitoneal lymph nodes. This case not only has exemplified that this tumor is rare and fatal but its prompt diagnosis is critical. However it is most likely that the diagnosis of this tumor is found when it has metastasized and this is unfortunately very late.

Keywords: Desmoplastic small round cell tumor, Radiology, Histology, Prognosis, Survival, Therapy

Introduction

Desmoplastic small round cell tumor (DSRCT) is a malignant cell tumor. The numbers of cases that have been reported since 1989 are less than 200 which makes this type of invasive, malevolent tumor very uncommon but not less dangerous.¹ Desmoplastic small round cell tumor appears to be more prevalent among males with a mean age of 18.6 years. In these patients the tumor usually appears in either the abdominal or pelvic peritoneum, or both, and follows an aggressive clinical course with an extremely poor prognosis. Subsequently, DSRCT metastasizes

and spreads to distant lymph nodes. It is able to gradually disseminate to important functional internal organs such as the liver and lungs.^{2,3} Currently chemotherapy, radiation therapy and surgery have resulted in a poor survival of 30% to 55%.⁴

In some cases patients with DSRCT undergo aggressive multimodality therapy. This therapy tends to extend the survival rate in these patients.⁵

Case Report

A 28-year old male was admitted to the hospital on January 6th, 2014 for a medical evaluation. For a one-

Corresponding Author:

Amr Idris, MD
Syrian Private University,
Damascus Hospital, Damascus,
Syrian Arab Republic
Email: amr-idris@hotmail.com



month period, the patient experienced constant lower abdominal pain with fullness and constipation followed by a weight loss of 25 pounds over this same period. He suffered from night sweats along with changes in his urinary habits such as dribbling, urgency and dysuria. The color of his urine became abnormal, turning to a dark red color. However the patient's physical examination was normal except for mild abdominal distention. His past medical history was unremarkable for major surgery, trauma, or severe sickness. The patient was a regular smoker who, for the last nine years, smoked a pack of cigarettes per day.

All laboratory analyses were normal, except for the urinalysis results that showed hematuria.

An ultrasound was done on the patient's abdomen, which revealed an extensive heterogeneous mass between the umbilical level and the pelvis. Additionally the tumor extended beyond the bladder and it measured 15×10×10 cm. The ultrasound revealed the presence of multiple enlarged lymph nodes in the abdomen near the spleen and tail of the pancreas - the largest was approximately 40 mm. Ultrasound also showed an enlarged liver. The liver presented with a total of four masses in the left and right hepatic lobes

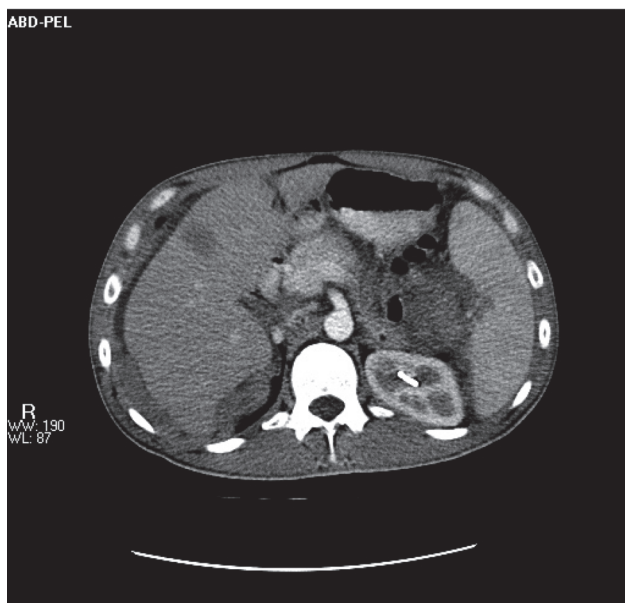


Figure 2. Computed tomography scan (CT scan) shows multiple heterogeneous soft tissue masses of different sizes. The smallest in the abdomen is compressing the surrounding organs, near the spleen and liver.

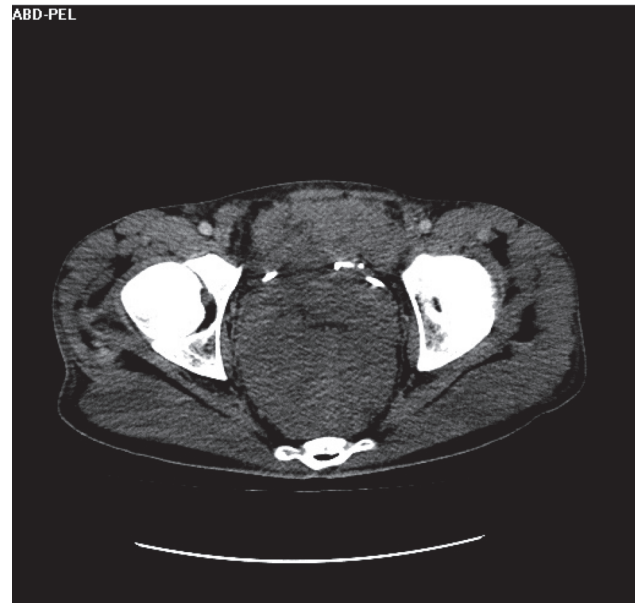


Figure 1. Computed tomography scan (CT scan) shows retroperitoneal soft tissue mass behind the bladder compressing the rectum and displacing the adjacent organs.

that measured 15 mm, 34 mm, 37 mm, and 20 mm. These measurements clearly indicated liver involvement, which was most likely liver metastases. The absence of intrahepatic or extrahepatic biliary tract enlargement meant there was no blockage to the normal flow of bile from the liver.

A computed tomography scan (CT scan) of

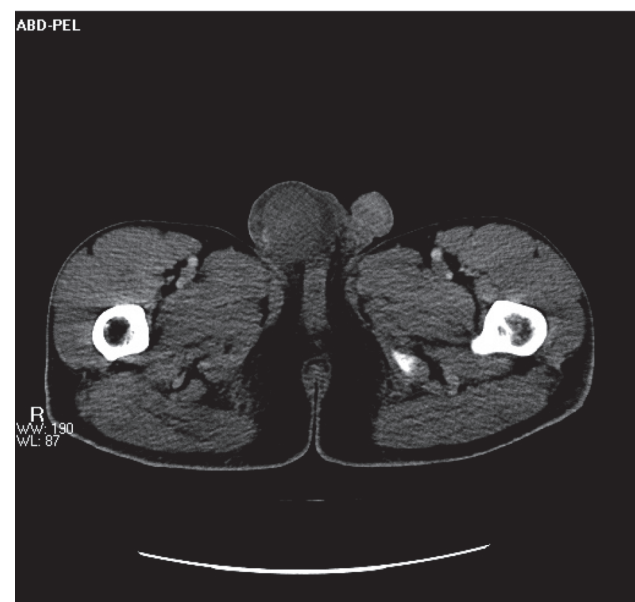

Figure 3. Computed tomography scan (CT scan) shows a heterogeneous 4-6 cm scrotal mass near the right testes.

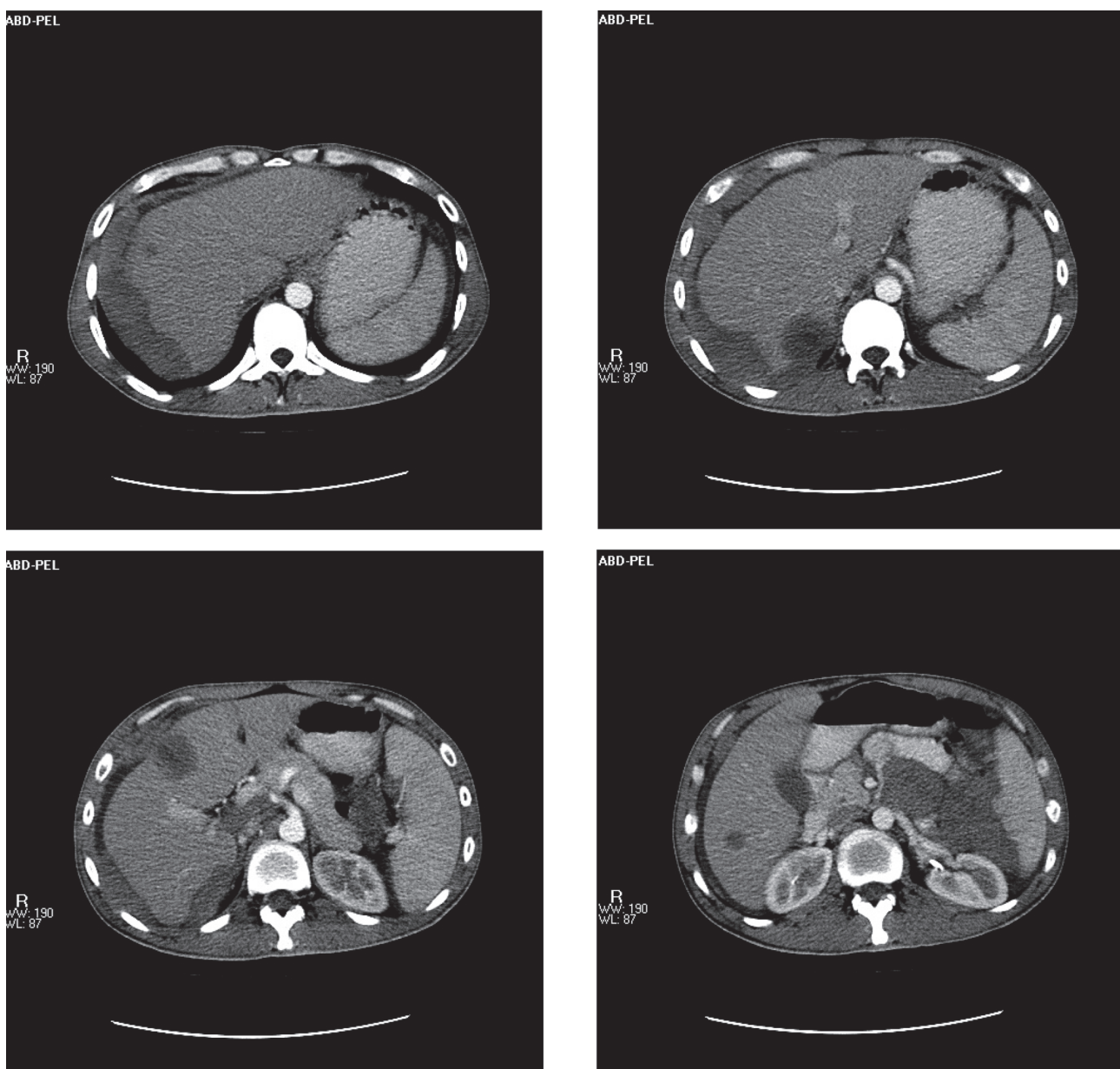
the abdomen and pelvis revealed the presence of a retroperitoneal soft tissue mass behind the bladder. The mass measured 15×10×10 cm. This mass compressed the rectum and displaced the adjacent organs due to its size (Figure 1).

The CT scan also showed the existence of multiple heterogeneous soft tissue masses in the abdomen and pelvis, which varied in their measurements. These masses compressed the surrounding organs. In addition, the CT scan found a heterogeneous scrotal mass near the right testis; this mass measured 4-6 cm and was more

consistent with metastasis (Figures 2, 3).

The liver had four heterogeneous solid cystic low density masses, with central necrosis in the right and left hepatic lobes. These four masses were more likely metastases (Figures. 4-7).

This patient underwent exploratory surgery. During this procedure a retroperitoneal mass was observed. The biopsies showed that the tumor mass was composed of well-defined nests of small, round, blue cells. These tumor cells were uniform and small-to-medium sized with scanty cytoplasm and separated by an abundant



Figures 4-7. Computed tomography scans (CT scans) show four heterogeneous solid cystic low density masses with central necrosis in the right and left hepatic lobes.

desmoplastic stroma. The pathological findings were suggestive of DSRCT (Figure 8).

Immunostaining confirmed the diagnosis of DSRCT. The tumor cells were positive for cytokeratin, vimentin, smooth muscle actin, and neuron specific enolase (Figures 9, 10).

The patient underwent a debulking palliative surgery where most of his tumor was removed. After surgery, an adjuvant two-stage multi-agent chemotherapy regimen was administered. This therapy consisted of vincristine and cyclophosphamide. Despite treatment, the patient did not recover. The tumor spread to other organs and the patient died after two months of treatment.

Discussion

Desmoplastic small round cell tumor is considered to be a rare, uncommon tumor. In addition, this tumor is a deadly, aggressive soft tissue sarcoma. Although the etiology is unknown it can be inferred that this malignancy arises from the mesothelium and, as such, occurs most commonly in the peritoneum and omentum.⁶ Extraperitoneal structures can also be affected as indicated in numerous reported cases and include the lungs, pleural serosa, parotid gland, ovaries, paratesticular region, posterior cranial fossa, pancreas, and bones.

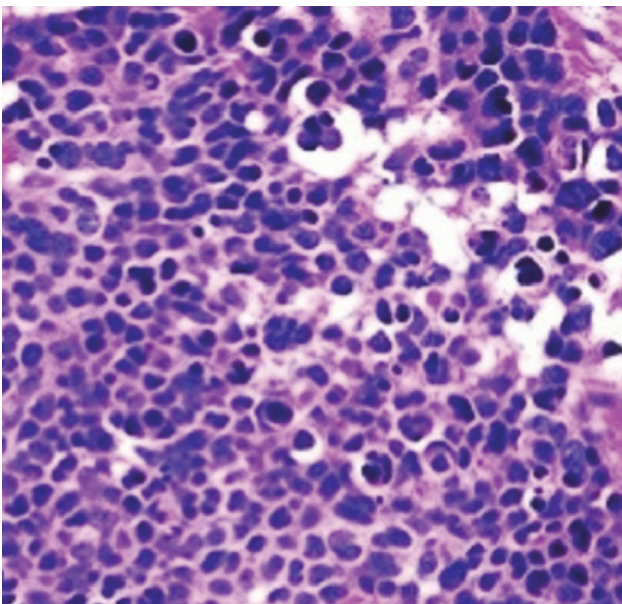


Figure 8. Tumor composed of well-defined nests of small round blue tumor cells separated by abundant desmoplastic stroma (hematoxylin and eosin).

The differential diagnosis of desmoplastic small round cell tumor could be fairly broad, because DSRCT has the same characteristics of the other small round cell tumors such as Ewing sarcoma, small cell mesothelioma, neuroblastoma and lymphoma. Therefore, a complete diagnosis of DSRCT can only be made by immunohistochemistry, a technique that utilizes antibodies in the diagnosis of abnormal cells. These antibodies in DSRCT demonstrate multidirectional differentiation. In many instances, a perinuclear dot-like immunostaining with desmin is strongly suggestive of the diagnosis of DSRCT.⁷

This tumor is associated with a unique chromosomal translocation, (t11;22)(p13;q12), which results in an EWS/WT1 transcription. This transcription is a particular characteristic used to support the diagnosis of DSRCT.^{8,9}

The histopathology of DSRCT is defined as nests or clusters of undifferentiated small round cells with small hyperchromic nuclei and scanty cytoplasm. These round cells are surrounded by a prominent desmoplastic stroma.

Desmoplastic small round cell tumor causes diffuse involvement of the abdominal cavity, pelvis and visceral organs. This diffusion gives rise to obstructive symptoms. The patient usually manifests with vague abdominal or pelvic

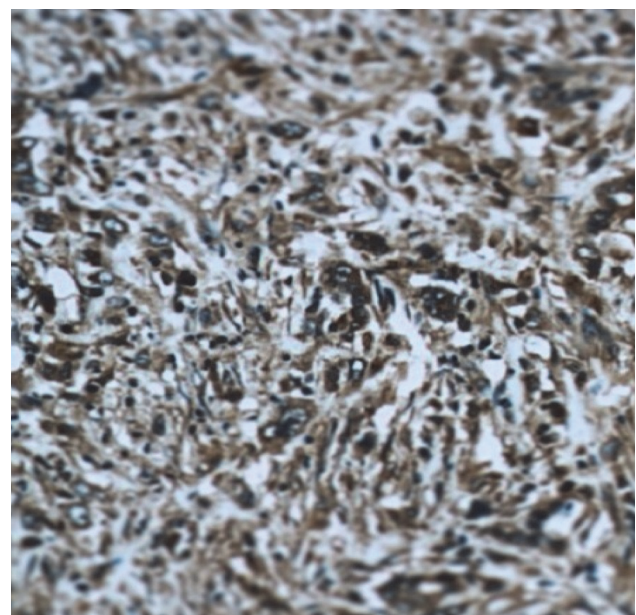


Figure 9. Positive immunohistochemistry for cytokeratin.

discomfort, weight loss, a palpable abdominal mass, and abdominal distention accompanied by constipation, dysuria, intestinal obstruction and other compressive symptoms.

Desmoplastic small round cell tumor is considered to be an aggressive disease with a poor prognosis. Statistically, the average survival is approximate 23 months.⁸ Therefore prompt diagnosis is critical in a patient that manifests with symptoms resembling DSRCT. The radiologist should consider the diagnosis of DSRCT when a dominant intraperitoneal soft-tissue mass without a primary visceral site of origin arises with lymphadenopathy, mesenteric nodules and peritoneal spread. Other characteristics include possible calcification in both primary and metastatic masses, heterogeneous enhancement and development of peritoneal sacromatosis. The CT scan plays the most useful role in diagnosis and staging and should be the initial imaging technique.¹⁰

The ultrasound may be helpful in guiding a percutaneous biopsy of relatively superficial lesions. However, it does not assist with additional characterization of the lesions. Generally, the ultrasound shows lobulated heterogeneous hypo-echoic lesions.¹¹

There is no general consensus regarding the best therapeutic approach as strong evidence is lacking due to the rarity of this disease. Although multimodality treatment with chemotherapy, surgery and radiotherapy appear to present hope in controlling this malignant tumor, recent studies have shown that complete surgical excision, including DSRCT seeding as small as 1 to 2 mm, is necessary to achieve long term disease control. There is evidence that intraperitoneal hyperthermic chemotherapy using cisplatin is thought to be effective at reducing the recurrence rate of the disease and lowers the morbidity treatment option for DSRCT patients.¹²

In conclusion, an intra-abdominal DSRCT remains an aggressive malignancy that mainly affects young males. Imaging examination alone is inadequate for a definitive diagnosis. Immunohistochemistry and cytogenetic studies are strongly

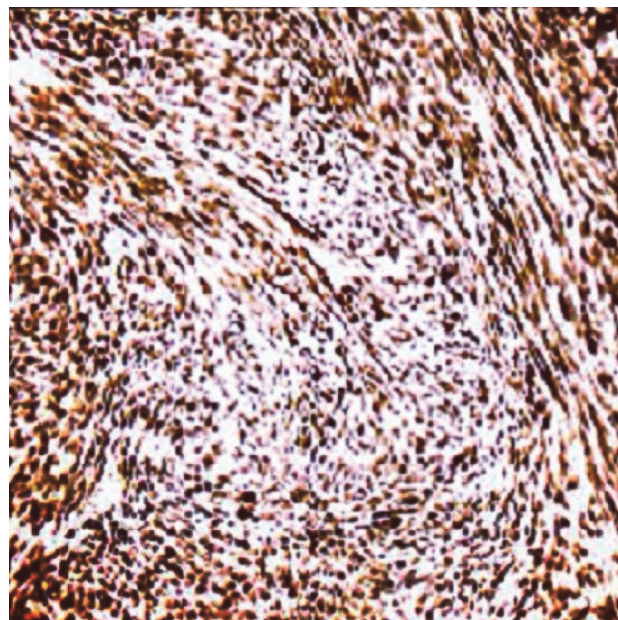


Figure 10. Positive immunohistochemistry for vimentin.

recommended. A complete resection is rare and surgical efforts are generally to provide the patient with symptom relief and improve quality of life.

Conflict of Interest

No conflict of interest is declared.

References

1. Gerald WL, Rosai J. Case 2. Desmoplastic small cell tumor with divergent differentiation. *Pediatr Pathol.* 1989;9(2):177-83.
2. Gerald WL, Miller HK, Battifora H, Miettinen M, Silva EG, Rosai J. Intra-abdominal desmoplastic small round-cell tumor. Report of 19 cases of a distinctive type of high-grade polyphenotypic malignancy affecting young individuals. *Am J Surg Pathol.* 1991;15:499-513.
3. Kretschmar CS, Colbach C, Bhan I, Crombleholme TM. Desmoplastic small cell tumor: a report of three cases and a review of the literature. *J Pediatr Hematol Oncol.* 1996;18(3):293-8.
4. Hayes-Jordan A, Green H, Fitzgerald N, Xiao L, Anderson P. Novel treatment for desmoplastic small round cell tumor: hyperthermic intraperitoneal perfusion. *J Pediatr Surg.* 2010;45(5):1000-6.
5. Weiss, SW; Goldblum, JR. Enzinger and Weiss's soft tissue tumors, 5th ed. Philadelphia, PA: Mosby Elsevier, c2008.
6. Thomas R, Rajeswaran G, Thway K, Benson C, Shahabuddin K, Moskovic E. Desmoplastic small round cell tumour: the radiological, pathological and clinical features. *Insights Imaging.* 2013;4(1):111-8.
7. Ordóñez NG. Desmoplastic small round cell tumor: I:

- a histopathologic study of 39 cases with emphasis on unusual histological patterns. *Am J Surg Pathol.* 1998;22(11):1303-13.
8. Murphy AJ, Bishop K, Pereira C, Chilton-MacNeill S, Ho M, Zielenska M, et al. A new molecular variant of desmoplastic small round cell tumor: significance of WT1 immunostaining in this entity. *Hum Pathol.* 2008;39(12):1763-70.
 9. Gerald WL, Haber DA. The EWS-WT1 gene fusion in desmoplastic small round cell tumor. *Semin Cancer Biol.* 2005;15(3):197-205.
 10. Bellah R, Suzuki-Bordalo L, Brecher E, Ginsberg JP, Maris J, Pawel BR. Desmoplastic small round cell tumor in the abdomen and pelvis: report of CT findings in 11 affected children and young adults. *Am J Roentgenol(AJR).* 2005;184(6):1910-4.
 11. Kis B, O'Regan KN, Agoston A, Javery O, Jagannathan J, Ramaiya NH. Imaging of desmoplastic small round cell tumour in adults. *Br J Radiol.* 2012;85(1010):187-92.
 12. Hayes-Jordan A, Anderson PM. The diagnosis and management of desmoplastic small round cell tumor: a review. *Curr Opin Oncol.* 2011;23(4):385-9.