

## Myxofibrosarcoma of the Breast in a Young Pregnant Woman: A Case Report and Review of the Literature

Fatemeh Nili\*, Elham Asadinejad\*, Hana Saffar\*, Alireza Ghanadan\*,\*\*♦

\*Department of Pathology, Cancer Institute, Imam Khomeini Hospital Complex, Tehran University of Medical Sciences, Tehran, Iran

\*\*Department of Dermatopathology, Razi Dermatology Hospital, Tehran University of Medical Sciences, Tehran, Iran

### Abstract

Sarcomas of the breast are rare and comprise less than 1% of mammary cancers. Myxofibrosarcoma as an unusual variant of malignant fibrous histiocytoma in the breast and during pregnancy has not previously been reported in the literature. We present the case of a 32-year-old woman with a rapidly growing subcutaneous left breast mass that appeared during her first pregnancy. After ultrasonography and core needle biopsy, she underwent a modified radical mastectomy. Pathologic examination revealed a multinodular subcutaneous mass with characteristic microscopic features consistent with myxofibrosarcoma. Immunohistochemistry findings supported the diagnosis and excluded other differential diagnoses. There has been no consensus about proper management and surveillance in these rare groups of malignancies, however wide local excision and adjuvant treatment for moderate and high grade tumors are recommended.

**Keywords:** Breast, Sarcoma, Myxofibrosarcoma, Malignant fibrous histiocytoma, Pregnancy

### Introduction

Mammary sarcomas are a rare, heterogeneous group of malignant neoplasms that more frequently affect the female breast. According to data from the Surveillance Epidemiology and End Results (SEER) database, the annual incidence is 4.6 cases/million women.<sup>1</sup> Predisposing factors that include irradiation for breast carcinoma or foreign bodies are considered risk factors for the

development of stromal sarcoma. Primary sarcomas in the breast are classified as other anatomic sites according to their pattern of growth and cell of origin. Angiosarcoma, malignant fibrous histiocytoma (MFH), fibrosarcoma, liposarcoma, and leiomyosarcoma are the more frequent types of mammary sarcomas.<sup>2</sup> Myxofibrosarcomas, an unusual variant of MFH based on the current WHO definition, include

♦Corresponding Author:  
Alireza Ghanadan, MD  
Department of Pathology,  
Cancer Institute, Imam  
Khomeini Hospital Complex,  
Tehran University of Medical  
Sciences, Tehran, Iran  
Tel/ Fax: +982161192554  
Email: dermpath101@gmail.com

tumors with a broad range of nuclear atypia, myxoid stroma, multinodular growth pattern, and curvilinear vascular structures.<sup>3</sup> They usually arise in subcutaneous tissue in the extremities of elderly patients and are rarely reported in the breast.<sup>3-11</sup> Breast cancer during pregnancy, while breast feeding, or within the first year of delivery is very rare. However, it is among the most common types of malignancies during this period.<sup>12</sup>

Herein, we report a case of mammary myxofibrosarcoma with rapid growth during pregnancy in a young woman.

### Case report

A 32-year-old woman without any significant diseases in her past medical history detected a palpable mass in the left breast since a few years prior that gradually increased in size. During her first pregnancy the mass rapidly grew. An ultrasound was performed which revealed two hypoechoic lobulated vascularized masses that measured 52×33 mm and 49×39 mm in greatest diameters, adjacent to the nipple. Core needle biopsy was performed and revealed a spindle cell proliferation composed of cells with oval to elongated slightly pleomorphic nuclei and elongated eosinophilic cytoplasm in a myxoid background. Vascular proliferation, some mitotic figures, and perivascular infiltration of predominantly small lymphocytes were also noted. The pathology report stated that differential diagnoses of sarcoma or pseudosarcoma were suggested with recommendations for a definitive diagnosis after excisional biopsy. Due to the large size of the mass and rapid growth pattern, she underwent a modified radical mastectomy at the end of the pregnancy. No evidence of metastatic involvement was reported on imaging studies.

Gross examination revealed a well-circumscribed subcutaneous multinodular mass at the central through lateral portion of breast tissue that measured 16×15×5 cm. Other parts of the breast had a yellowish orange-colored lobulated appearance (Figure 1).

Microscopic examination showed neoplastic tissue with a multinodular growth pattern, composed of spindle cells with eosinophilic or vacuolated cytoplasm and elongated spindle nuclei with mild to moderate degree of atypia. Neoplastic cells were arranged in short and elongated interlacing fascicles in an abundant myxoid stroma. Curvilinear blood vessels with condensation of neoplastic cells around them were also seen. Mitotic activity in some areas was approximately 10-12/10 high power field (HPF). Frequent atypical figures were also noted (Figure 2A-D).

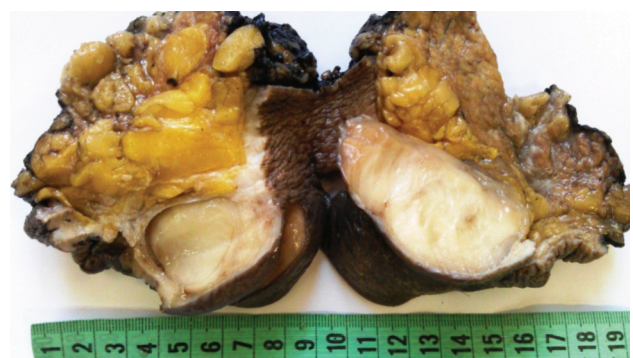
Based on the French Federation Cancer Center System grading, the specimen had a tumor differentiation score of 2, mitotic rate score of 2, tumor cell necrosis of 0, and overall histologic grade of 2.

Immunohistochemistry study revealed a negative immune reaction with cytokeratin AE1/AE3, epithelial membrane antigen (EMA), desmin, smooth muscle actin (SMA), CD99, Bcl-2, estrogen receptor (ER), progesterone receptor (PR), and S100. The neoplastic cells were positive for vimentin and CD34. Nuclear beta-catenin. Ki-67 (MIB-1) reaction was approximately 30%-40% (Figure 3A, B).

Unfortunately the patient did not refer to our institute for adjuvant treatment and was lost to follow-up.

### Discussion

Sarcomas of the breast are rare and represent less than 1% of mammary cancers.<sup>7</sup> Malignant



**Figure 1.** Well-circumscribed subcutaneous multinodular breast mass that measured 16×15×5 cm with homogeneous whitish cut surface.

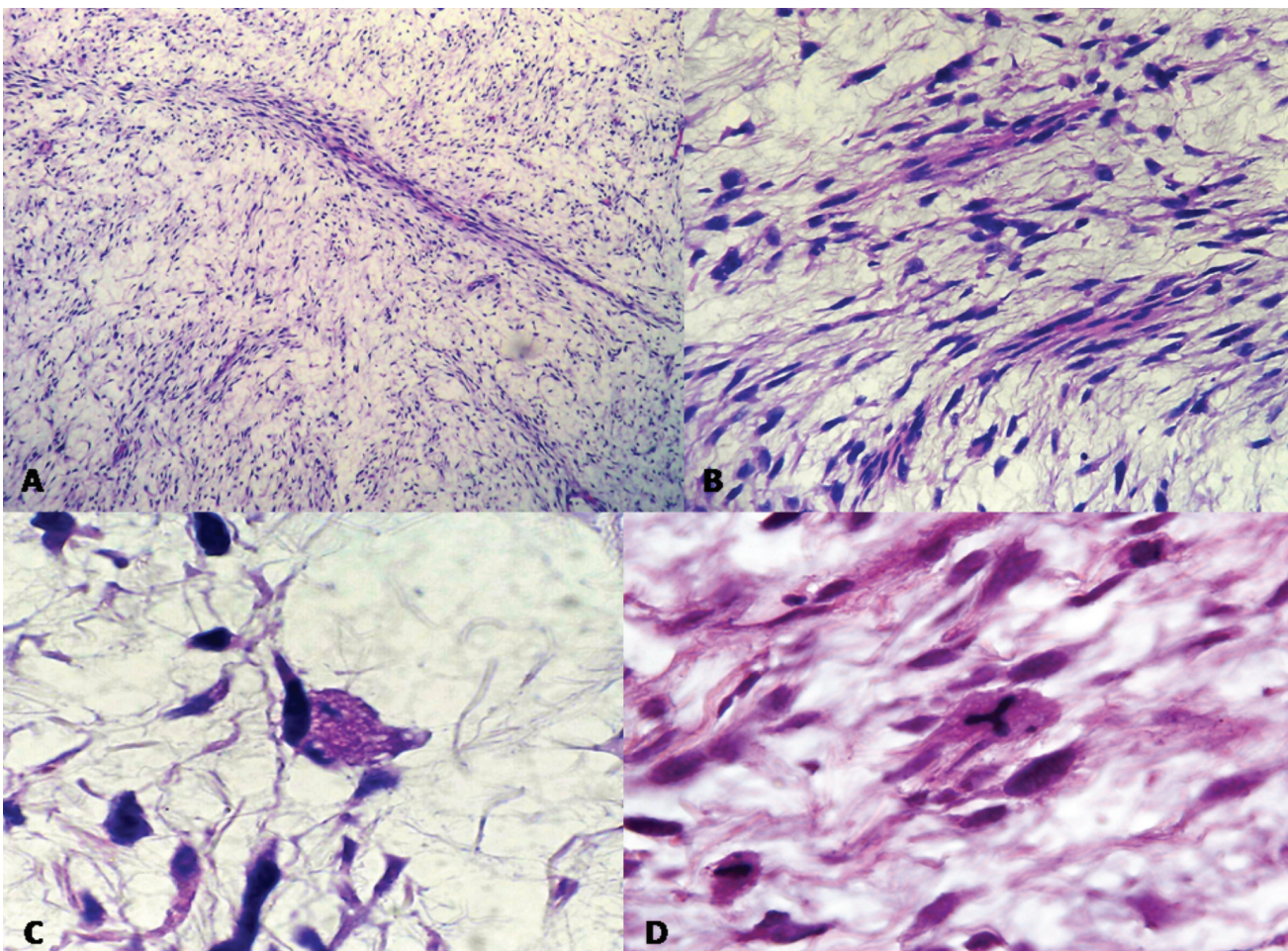
fibrous histiocytoma is the second most common type of sarcoma in the breast. There are several morphologic subtypes of MFH which include myxoid, pleomorphic, inflammatory and angiomatoid variants.<sup>4-11</sup>

Myxofibrosarcoma or myxoid variant of MFH is the second most common type of MFH in which proliferation of spindle cells with broad variation in atypia is seen in a myxoid stroma. Multinodular growth pattern and curvilinear vascular structures are also characteristic of this tumor subtype.<sup>3</sup> Although they are among the most frequent malignant mesenchymal tumors in the extremities of elderly individuals, there are rare reported cases of breast involvement in young adults (Table 1).

To the best of our knowledge, this was the first report of this unusual variant of sarcoma in the breast that occurred during pregnancy. In the

presented case, the immunohistochemistry (IHC) study in addition to characteristic morphologic findings contributed to the accurate diagnosis and exclusion of other differential diagnoses. Metaplastic carcinoma and other types of soft tissue sarcoma were excluded by the negative reaction of tumor cells with CK AE1/AE3, EMA, SMA, desmin, and S100. We eliminated phyllodes tumor and periductal stromal sarcoma due to the absence of any epithelial component. Smith et al. reported positive staining for CD34 in 50% of superficial myxofibrosarcomas.<sup>13</sup> Focal moderate nuclear atypia and scattered mitotic figures which were not sampled on the core needle biopsy led to difficulty in the primary definite diagnosis.

Clinical behavior of myxofibrosarcoma is closely related to the tumor grade. While the rate of metastasis in pure low-grade tumors is minimal,



**Figure 2.** Microscopic examination revealed A) multinodular neoplasm composed of interlacing short fascicles of spindle cells embedded in a myxoid stroma (H&E, 10 $\times$ ). B) Curvilinear vascular channels with perivascular condensation of neoplastic cells (H&E, 40 $\times$ ). C) Pleomorphic spindle cells with hyperchromatic vesicular nuclei. Some of the cells had vacuolated cytoplasm that resembled lipoblasts (H&E, 100 $\times$ ). D) Increased mitotic figures with atypical tripolar figures (H&E, 100 $\times$ ).

**Table 1.** Clinical, demographic, and immunohistochemistry characteristics of reported cases of breast myxofibrosarcoma in the literature.

Authors (Ref)	Year	Age/Gender	Side	Diagnosis	IHC	Procedure	Size (cm)
Ajisaka et al. <sup>7</sup>	2002	52/F	Left	Myxoid MFH	CD34 (+) Myogenic markers (-) S100 (-)	Radical mastectomy	22×20×11.5
Hocevar et al. <sup>4</sup>	2004	58/F	Left	MFS	CK (-), S100 (-)	Lumpectomy	3.4×1.5×1.2
Klopcic et al. <sup>5</sup>	2009	45/F	Right	MFS	CK (-)	Mastectomy	10
Hartel et al. <sup>6</sup>	2011	Mean age: 59/ 6 F	Not specified	MFS	CD34 (-)	Not specified	Not specified
Ono et al. <sup>9</sup>	2012	50/F	Right	MFS	CD34 (+), α-SMA (+)	Not specified	3
Leal et al. <sup>8</sup>	2012	26/F	Left	MFS	CK (-), S100 (-)	Mastectomy	4.1×3.9 and 3.1×2.3
Qadri et al. <sup>11</sup>	2014	25/M	Right	MFS	CD34 (+), vimentin(+), CK (-), S100 (-), CD68 (-)	MRM	22×14×12
Hwang et al. <sup>10</sup>	2015	59/F	Left	MFS	Not mentioned	Not specified	4
Our case	2016	32/F	Left	MFS	CD34 (+), β-catenin (+), CK (-), EMA (-)	MRM	16×15×5

MFH: malignant fibrous histiocytoma; MFS: Myxofibrosarcoma, IHC: Immunohistochemistry; MRM: Modified radical mastectomy

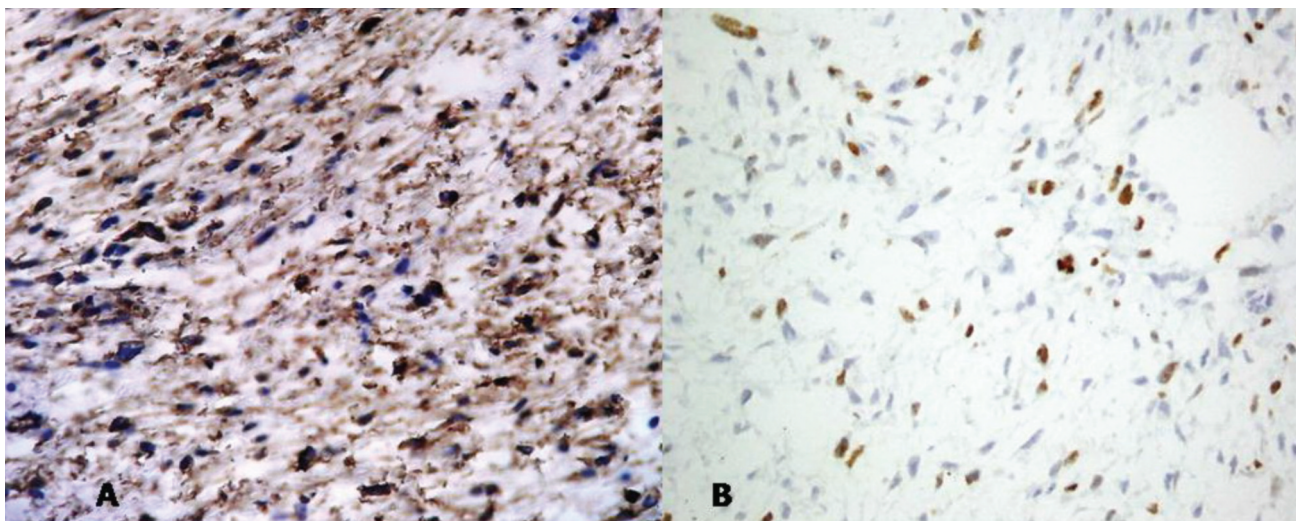
higher grades behave as MFH. Tumor size larger than 5 cm, tumor necrosis and myxoid stroma >75% are also associated with poor prognosis.<sup>3</sup>

Few small series of breast sarcoma exist in the literature, hence, there is no consensus about proper management. However, surgical excision with tumor free margins is recommended.<sup>7</sup> Distant metastases from breast sarcoma commonly disseminate through the blood vessels, therefore

axillary lymph node dissection is debatable. Due to the high recurrence and metastatic rate of moderate and high grade tumors, adjuvant treatments can be considered for these cases.<sup>7</sup>

Dewan et al. reported a 5-year survival rate of 63% and 10-year survival rate of 42% for soft tissue tumors in the extremities, which was comparable with previous studies.<sup>14,15</sup> There was no report for breast counterparts in the literature.

Breast cancer diagnosed during pregnancy,



**Figure 3.** A) Positive immunoreactivity of tumor cells with CD34. B) Positive immunoreaction of approximately 30%-40% of neoplastic cells with Ki-67 (MIB-1) (40×).

breastfeeding, and within the first year after delivery is defined as pregnancy-associated breast cancer (PABC). It is very rare but expected to increase because of delayed childbearing in women.<sup>16</sup> Breast carcinoma is among the most common type of malignancies diagnosed in this period.<sup>12</sup> Mammary sarcoma is extremely rare. There are controversial studies about the prognosis in PABC. While it is believed that overall and disease free survival rates in pregnant and non-pregnant women after adjustments for age, stage, and other prognostic factors are the same.<sup>17-20</sup> However, because of delayed diagnosis, higher tumor stage, higher grade of the primary tumor, and unfavorable biologic features, more aggressive behavior and poorer prognosis are usually expected.<sup>12</sup> Unfortunately the study case did not refer to our hospital for treatment and was lost to follow-up.

## Conclusion

Myxofibrosarcoma is an unusual variant of MFH that uncommonly involves the breast. During pregnancy it is extremely rare and has not been reported in the literature thus far. As with other infrequent sarcomas of the breast, radial surgery with adequate safe margins is the first step of treatment. Axillary lymph node dissection is debatable and adjuvant treatment must be considered for moderate and high grade tumors. There is no consensus about the outcome and prognosis in these rare groups of malignancies in the breast.

## Conflict of Interest

No conflict of interest is declared.

## References

1. Koerner Frederick, C; Sarcoma. Rosen's breast pathology. In: Hoda Syed, A; Brogi, Edi; Koerner Frederick, C' Rosen, Paul Peter, editors. 4<sup>th</sup> ed. Philadelphia: Wolters Kluwer Health/Lippincott Williams & Wilkins; 2014. p. 1095-1155.
2. Sandra J, Shin; Joseph T, Rabban. Breast pathology. In: Dabbs David J. 1<sup>st</sup> ed. Philadelphia: Elsevier/Saunders; 2012. p. 596-635.
3. Goldblum, JR; Weiss, SW; Folpe, AL. Borderline and malignant fibroblastic and myofibroblastic tumors. Enzinger and Weiss's soft tissue tumors. 6<sup>th</sup> ed. Philadelphia: Elsevier Saunders; 2012.p.318-324.
4. Hocevar M, Marinsek ZP, Zidar A. Myxofibrosarcoma of the breast as an unusual variant of malignant fibrous histiocytoma: report of a case. *Surg Today*. 2004;34(9):752-4.
5. Klopčič U, Lamovec J, Luzar B. Fine needle aspiration biopsy of primary breast myxofibrosarcoma: a case report. *Acta Cytol*. 2009;53(1):109-12.
6. Hartel PH, Bratthauer G, Hartel JV, Fanburg-Smith JC. Primary malignant fibrous histiocytoma (myxofibrosarcoma/pleomorphic sarcoma not otherwise specified) of the breast: clinicopathologic study of 19 cases. *Ann Diagn Pathol*. 2011;15(6):407-13.
7. Ajsaka H1, Maeda K, Uchiyama A, Miwa A. Myxoid malignant fibrous histiocytoma of the breast: report of a case. *Surg Today*. 2002;32(10):887-90.
8. Leal M, Miranda J, Porto L, Paz A. Myxofibrosarcoma of the breast: Case report. *J Senologic International Society*. 2012;1(3).
9. Ono S, Kimura K, Yoneyama H, Kimura A, Kouno H, Satake T. A case of a myxofibrosarcoma of the breast. *J Japan Surgical Association*. 2012; 73(9): 2200-4.
10. Hwang JD, Kim JY, Hwang MS, Bae YK, Lee SJ. Post radiation myxofibrosarcoma in breast: A case report. *J Korean Soc Radiol*. 2015;73(1):53-7.
11. Qadri S, Alam F, Shamim N, Rabindranath D, Naim M, Alam K. Myxofibrosarcoma of the male breast—An infrequent neoplasm: A case report and comprehensive review. *Int J of Allied Med Sci and Clin Research*. 2014;2(4):410-4.
12. Raphael J, Trudeau ME, Chan K. Outcome of patients with pregnancy during or after breast cancer: a review of the recent literature. *Curr Oncol*. 2015;22(Suppl 1):S8-S18.
13. Smith SC, Poznanski AA, Fullen DR, Ma L, McHugh JB, Lucas DR, et al. CD34-positive superficial myxofibrosarcoma: a potential diagnostic pitfall. *J Cutan Pathol*. 2013;40(7):639-45.
14. Dewan V, Darbyshire A, Sumathi V, Jeys L, Grimer R. Prognostic and survival factors in myxofibrosarcomas. *Sarcoma*. 2012;2012:830879.
15. Mentzel T, Calonje E, Wadden C, Camplejohn RS, Beham A, Smith MA, et al. Myxofibrosarcoma. Clinicopathologic analysis of 75 cases with emphasis on the low-grade variant. *Am J Surg Pathol*. 1996;20(4):391-405.
16. Woo JC, Yu T, Hurd TC. Breast cancer in pregnancy: a literature review. *Arch Surg*. 2003;138(1):91-8; discussion 99.
17. Bonnier P, Romain S, Dilhuydy JM, Bonichon F, Julien JP, Charpin C, et al. Influence of pregnancy on the outcome of breast cancer: a case-control study. Societe Francaise de Senologie et de Pathologie Mammaire Study Group. *Int J Cancer*. 1997;72(5):720-7.

18. Beadle BM, Woodward WA, Middleton LP, Tereffe W, Strom EA, Litton JK, et al. The impact of pregnancy on breast cancer outcomes in women  $\leq 35$  years. *Cancer*. 2009;115(6):1174-84.
19. Amant F, von Minckwitz G, Han SN, Bontenbal M, Ring AE, Giermek J, et al. Prognosis of women with primary breast cancer diagnosed during pregnancy: results from an international collaborative study. *J Clin Oncol*. 2013;31(20):2532-9.
20. Cardonick E, Dougherty R, Grana G, Gilmandyar D, Ghaffar S, Usmani A. Breast cancer during pregnancy: maternal and fetal outcomes. *Cancer J*. 2010;16(1):76-82.