

Diagnostic Delay: Nasal Polyp to Extra-nodal Natural Killer T-cell Lymphoma - A Case Report

Adithya Vikrama Acharya, MBBS, Thiru Raju Arulponni*, MD

Department of Radiation Oncology, Ramaiah Medical College and Hospitals, Ramaiah University of Applied Sciences, Bangalore, India

Please cite this article as:
Acharya AV, Arulponni TR.
Diagnostic delay: Nasal polyp
to extra-nodal natural killer
T-cell lymphoma - A case
report. Middle East J Cancer.
2024;15(3):249-54. doi:10.
30476/mejc.2023.98978.1922.

Abstract

Extra-nodal natural killer/T-cell lymphoma-nasal type (ENKTCL-NT) represents a rare clinical entity that often masquerades as benign lesions during its early stages, resulting in delayed diagnosis and appropriate treatment. The optimal management of this condition hinges on immunohistochemistry, disease stage, and risk stratification based on five critical prognostic factors, which encompass stage, age, performance status, lactate dehydrogenase levels, and primary tumor invasion. Radiation therapy is the cornerstone for achieving locoregional control in localized and advanced disease stages. In this case report, we present the case of a 49-year-old male, who sought medical attention at our center due to uncontrolled epistaxis following an interventional procedure for a suspected nasal polyp. Subsequent examination of histopathology slides and blocks, along with immunohistochemistry, confirmed the diagnosis of ENKTCL-NT, with residual disease evident on positron emission tomography-computed tomography. Following deliberation by the multidisciplinary tumor board, the decision was made to administer radical radiation therapy alone, with a total dose of 5940 cGy (centigray) delivered in 30 fractions employing intensity-modulated radiotherapy techniques, considering the patient's cardiac comorbidities.

Keywords: Extra-nodal natural killer T-cell lymphoma, Nasal polyps, Radiotherapy, Immunohistochemistry, Case report

Introduction

Lymphoma forms the third most common sino-nasal cancer after squamous cell carcinoma and adenocarcinoma, accounting for 12%-15% of head and neck malignancies.¹ Extra-nodal- natural killer/T-cell lymphoma-nasal type (ENKTCL-NT) is an aggressive type

mainly affecting the nasal or upper aero-digestive sites, rarely affecting the skin, soft tissue, and testes.² The first report of ENKTCL-NT was in the 19th century when the nature of the disease was unknown, and it was currently classified less than 30 years ago. This case is reported, as although the presentation was a nasal polyp,

Corresponding Author:

Thiru Raju Arulponni, MD
Department of Radiation
Oncology, Ramaiah Medical
College and Hospitals, Ramaiah
University of Applied Sciences,
Bangalore, India
Email: arulponni@gmail.com



one should have a high degree of suspicion, so that early diagnosis and effective treatment can be made.

Case Presentation

We present a case reported following receiving informed consent and approval from the Ramaiah Medical College Ethics Committee under registration number ECR/215/Inst/KA/2013/RR-19 (code: EC/CR-67/2023). The patient was initially diagnosed with a nasal polyp at a general hospital but was subsequently referred to our hospital due to uncontrolled epistaxis, despite multiple interventions.

The patient is a 49-year-old male with a known medical history of type 2 diabetes mellitus and ischemic heart disease, which has led to heart failure with reduced ejection fraction. He initially sought evaluation at an external medical facility due to complaints of 20 days duration, involving difficulty in breathing and nasal obstruction. Upon examination, tenderness was noted in the paranasal sinuses, and a polyp was observed in the right nasal cavity, causing significant narrowing of the nasal passage. The initial computerized tomography (CT) scan of the paranasal sinuses

indicated pan-sinusitis and the presence of a polypoidal thickening in the anterior half of the right nasal cavity, resulting in severe constriction. This raised concerns regarding the possibility of a neoplastic or inflammatory lesion. Subsequently, the patient consulted with an ear, nose, and throat (ENT) surgeon at an external hospital, where the diagnosis of a nasal polyp was confirmed. The patient underwent functional endoscopic sinus surgery, along with a right middle meatal antrostomy and excision of the mass under general anesthesia at the general hospital. Following the excision, the patient experienced repeated episodes of excessive nasal bleeding, necessitating cauterization on three separate occasions within three months.

Due to the persistent nasal bleeding, the patient was referred to our medical center and was admitted to the Department of ENT for supportive care. A review of postoperative histopathology slides revealed the presence of monomorphic lymphoid cells, indicative of a lymphoproliferative disease, most likely non-Hodgkin's lymphoma. Subsequently, the patient was referred to the Department of Oncology for further management. Clinically, the patient presented with swelling at

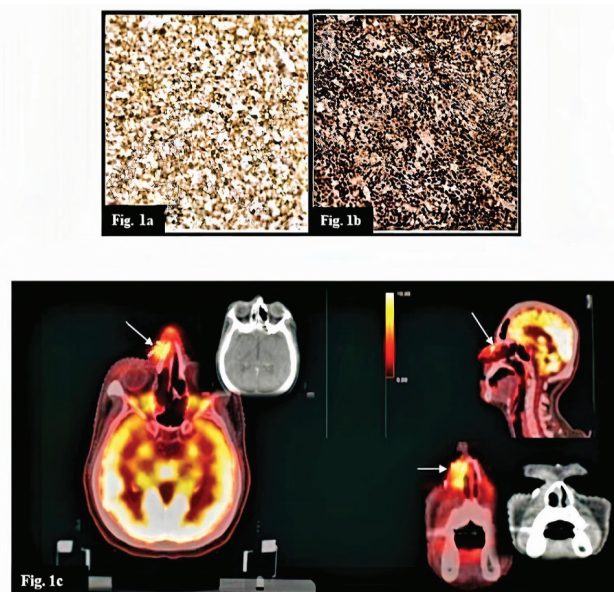


Figure 1: This figure displays (a) a pictomicrograph of IHC with CD3 positivity, (b) a pictomicrograph of IHC with EBV-LMP1 positivity, and (c) PET-CT-based radiotherapy planning images in axial, sagittal, and coronal sections. The solid white arrow indicates anomalous 19-FDG uptake in the soft tissue of the nasal cavity.

IHC: Immunohistochemistry; CD: Cluster of differentiation; EBV-LMP1: Epstein barr virus latent membrane protein; PET-CT: Positron emission tomography-computed tomography; FDG: Fluoro-deoxy-glucose

the root of the nose on the right side, close to the right medial canthus of the eye. Immunohistochemistry (IHC) (Figure 1a,b) yielded positive results for cluster of differentiation 2 (CD), CD3, EBVLMP1, and negative results for CD4, CD5, CD7, CD8, CD20, CD30, CD56, TdT, with EBER expression at 70%-75% and Ki67 at 70%-80%, suggesting a diagnosis leaning towards ENKTCL-NT, with stage IE.

Following a multidisciplinary tumor board discussion, the decision was made to postpone chemotherapy due to the patient's ejection fraction of 35%, as revealed by a 2D Echo, combined with a previous history of ischemic heart disease. Instead, the patient was scheduled for radical radiation therapy alone. A positron emission tomography-computed tomography (PET-CT) was utilized for treatment planning, revealing soft tissue thickening of the external nose and a thin, soft tissue mass in the anterior nasal cavity, with a standardized uptake value (SUV) of 9.39, suggestive of residual disease, and no evidence of involvement of extra nasal sites (Figure 1c).

Target volume delineation was conducted by recent guidelines published by SN Qi et al.³ The patient received a dose of 5940 cGy (centi Gray) in 30 fractions (fr) to the PET uptake gross disease and 54Gy in 30 fr to the clinical target volume, which encompassed the entire nasal cavity, ipsilateral maxilla, and hard palate, using intensity-modulated radiotherapy (IMRT) technique (Figure 2). The radiation doses received by 1 cc of serial structures were as follows: Brain-56 Gy,

Brainstem-29 Gy, Optic Chiasma-51.7Gy, and Optic nerves (right and left) were exposed to 52.3 and 52.4 Gy, respectively. The patient underwent weekly assessments for acute toxicities throughout the treatment course. Over the treatment duration, the patient developed grade two mucositis in the nasal cavity, managed symptomatically using saline nasal drops. Lubricating eye drops were initiated for eye dryness, which later subsided. In the fourth week of treatment, nasal cavity mucositis progressed to grade 3, and the patient was prescribed steroid nasal drops.

A candidiasis patch was also observed over the hard palate (Figure 3e), for which oral candid mouth paint was administered. The patient tolerated the treatment well and is currently undergoing regular follow-up. Two weeks after completion, the first follow-up revealed a reduction in mucositis to grade 1 (Figure 3 g, h) and the disappearance of candidiasis over the hard palate. Presently, the patient is disease-free at the end of three months following the completion of treatment.

Discussion

The incidence of ENKTCL in the Asian population is 28.65% as per the study by SE Yoon et al.,⁴ while it is 10.4% globally.⁵ In the Indian scenario, the incidence ranges between 0.92% - 13.5% of the total lymphoma cases, and around 25% have advanced disease at the time of presentation.^{6,7,8} Usually, patients of ENKTCL-NT present with symptoms of nasal

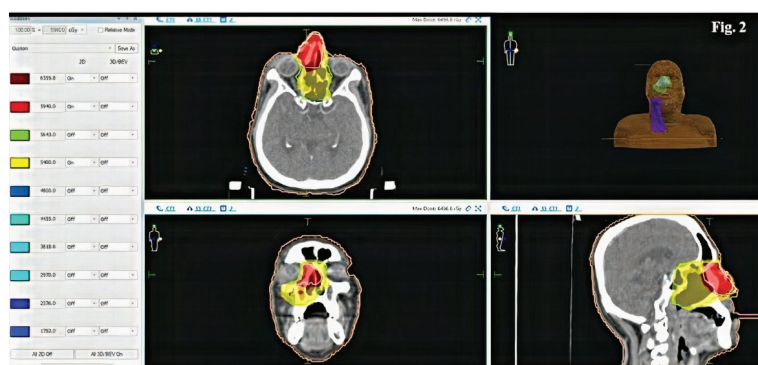


Figure 2: This figure illustrates the dose distribution of the planned treatment. The red color wash represents a 59.3 Gy volume for GTV, while the yellow color wash represents a 53 Gy volume for the CTV. GTV: Gross tumor volume; CTV: Clinical target volume

obstruction/epistaxis due to a mass in the nasal cavity. On disease progression, necrotic changes in the areas close to the midline of the face, i.e., nose, pharynx, and mouth, are seen, leading to ulceration and erosion of the structures. The other presentation mode involves extra nasal sites and bone marrow involvement without the primary site involvement. Our patient presented with nasal obstruction and breathing difficulty.

Arriving at an early diagnosis of ENKTCL-NT is difficult as the symptoms mimic sinusitis or nasal polyps in the early stages. The ordinary differential diagnoses are chronic sinusitis/rhinitis, rhinoscleroma, facial cellulitis, and deep mycoses, and they are started on antibiotics antimycotics or undergo an interventional procedure for the same, leading to the delay in appropriate treatment and disease progression. Our patient was initially diagnosed as a nasal polyp and underwent excision. When evaluated further to rule out an oncological cause for persistent nasal epistaxis, he was found to have ENKTCL-NT on immunohistochemistry with residual disease on PET-CT imaging.

The optimal management for localized

ENKTCL-NT remains unclear. Three main approaches to therapy are defined: a) Radiation alone, b) Concurrent chemoradiation, and c) Sequential treatment with radiation followed by consolidative chemotherapy.

ENKTCL are radiosensitive, while B-cell lymphomas are chemosensitive. Initially, radiation alone was considered for treating early disease as there is an excellent locoregional control rate of more than 90% and 5-year overall survival of 70 to 90%.⁷ But it was seen that a high incidence of systemic relapse (25%-40%) was seen in patients who were treated with radiation alone in the early stages. Hence, combined chemoradiation showed a better survival trend but did not provide any additional benefit, reserving chemotherapy for advanced stages.^{9,10}

Yong Yang et al. in 2015⁹ suggested a risk-adapted therapy for early-stage ENKTCL in which the patients were classified as either low or high risk using five independent prognostic factors such as stage, age, performance status, lactate dehydrogenase levels, and primary tumor invasion. It was seen that radiotherapy alone for the low-risk group was adequate compared with the

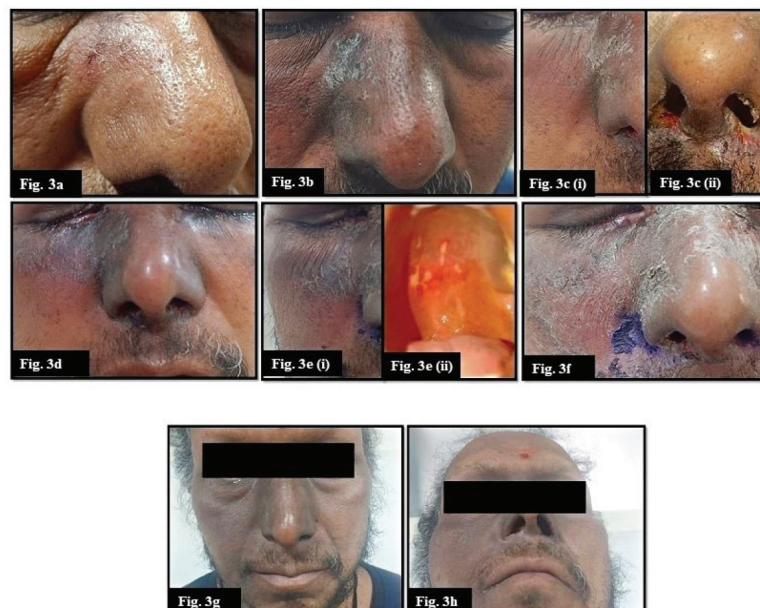

Figure 3. This figure presents clinical photographs of the patient throughout the treatment course. (a) At the initial presentation, (b) Grade 1 dermatitis was observed two weeks after the initiation of radiation, (c) (i) Dermatitis after three weeks of radiation, (c) (ii) Grade 3 mucositis of the nasal cavity at three weeks, (d) Progression of dermatitis at the lower eyelid level, (e) (i) Dermatitis after five weeks, (e) (ii) Candida patch observed at the hard palate at the fifth week, (f) Dermatitis observed after the treatment, and (g) and (h) Grade 1 dermatitis and Grade 1 mucositis of the nasal cavity, two weeks after the completion of radiation.

high-risk group that required both management modalities. Our patient was classified under the low-risk category, although he was initially managed with surgery with post-op residual disease, which is not included under risk stratification.

The target volume for our patient was delineated as per SN Qi et al.¹⁰ The gross tumor volume as seen on PET-CT was only 20 cc and hence planned 5940 cGy (centi Gray) in 30 fr and the clinical target volume included the entire nasal cavity, ipsilateral maxillary sinus, hard palate and the subcutaneous soft tissue which received 5400 cGy in 30 fr.¹²

With regards to the dose, it ranged from 15 - 74Gy with a median dose of 50-54Gy. It is observed that ≥ 50 Gy is required for adequate local control.^{7,11,12}

The acute toxicities seen in our patient were dermatitis, mucositis of the nasal cavity, hard palate, and dry eye. In the study by Wang H Y et al., where the IMRT technique was used, grade one mucositis was seen in 51.5% of patients, while grade 2 was seen in 19.2%.¹³ No patient developed grade 3 or 4 toxicity.

Conclusion

ENKTCL-NT is a rare clinical entity that warrants consideration in the differential diagnosis of nasal polyps. Accurate evaluation necessitates appropriate imaging and substantial histopathological evidence to establish the diagnosis, complemented by immunohistochemistry, before determining the treatment approach. Treatment strategies typically hinge on risk stratification, where radiation therapy alone is the preferred course of action for low-risk cases, whereas high-risk cases necessitate a combined approach involving both chemotherapy and radiation.

Since T-cell lymphomas exhibit radiosensitivity, radiation should serve as the primary therapeutic modality for both low- and high-risk groups, as it affords robust local control. Subsequent consolidation chemotherapy is recommended. The suggested radiation dose typically approximates 50 Gy or more, employing

IMRT or volumetric modulated arc therapy (VMAT) techniques for superior control and a favorable toxicity profile.

Informed Consent

Written informed consent was received from the patient.

Conflict of Interest

None declared

References

1. Kreisel FH. Hematolymphoid lesions of the sinonasal tract. *Head Neck Pathol.* 2016;10(1):109-17. doi: 10.1007/s12105-016-0698-5.
2. Ohshima K, Kimura H, Yoshino T, Kim CW, Ko YH, Lee SS, et al. Proposed categorization of pathological states of EBV-associated T/natural killer-cell lymphoproliferative disorder (LPD) in children and young adults: overlap with chronic active EBV infection and infantile fulminant EBV T-LPD. *Pathol Int.* 2008;58(4):209-17. doi: 10.1111/j.1440-1827.2008.02213.x.
3. Qi SN, Li YX, Specht L, Oguchi M, Tsang R, Ng A, et al. Modern radiation therapy for extranodal nasal-type NK/T-cell lymphoma: Risk-adapted therapy, target volume, and dose guidelines from the International Lymphoma Radiation Oncology Group. *Int J Radiat Oncol Biol Phys.* 2021;110(4):1064-81. doi:10.1016/j.ijrobp.2021.02.011.
4. Yoon SE, Song Y, Kim SJ, Yoon DH, Chen TY, Koh Y, et al. Comprehensive analysis of peripheral T-cell and natural killer/T-cell lymphoma in Asian patients: A multinational, multicenter, prospective registry study in Asia. *Lancet Reg Health West Pac.* 2021;10(100126): 100126. doi:10.1016/j.lanwpc.2021.100126.
5. Vose J, Armitage J, Weisenburger D; International T-Cell Lymphoma Project. International peripheral T-cell and natural killer/T-cell lymphoma study: pathology findings and clinical outcomes. *J Clin Oncol.* 2008; 26(25):4124-30. doi: 10.1200/JCO.2008.16.4558.
6. Jain S, Lone MR, Goswami A, Mandal T, Panda AK, Ramteke P, et al. Lymphoma subtypes in India: a tertiary care center review. *Clin Exp Med.* 2021;21(2): 315-21. doi:10.1007/s10238-021-00683-2.
7. Agrawal M, Champaka G, Amirtham U, Jacob LA, Premalata CS. Extranodal natural-killer/T-cell lymphoma, nasal type: An immunomorphological study from a regional cancer institute in India. *J Cancer Res Ther.* 2022;18(4):1137-43. doi:10.4103/jcrt.JCRT_226_20.
8. Khandare P, Saldanha S, Dasappa L, Jacob L, Babu MCS, Lokesh KN, et al. Extranodal NK/T-cell

- lymphoma-nasal type: Experience from a regional cancer center in India. *Muller J Med Sci Res.* 2020; 11(1):20. doi: 10.4103/mjmsr.mjmsr_39_19.
9. Yang Y, Zhu Y, Cao JZ, Zhang YJ, Xu LM, Yuan ZY, et al. Risk-adapted therapy for early-stage extranodal nasal-type NK/T-cell lymphoma: analysis from a multicenter study. *Blood.* 2015;126(12):1424-32; quiz 1517. doi:10.1182/blood-2015-04-639336
 10. Qi SN, Yang Y, Song YQ, Wang Y, He X, Hu C, et al. First-line non-anthracycline-based chemotherapy for extranodal nasal-type NK/T-cell lymphoma: a retrospective analysis from the CLCG. *Blood Adv.* 2020;4(13):3141-53. doi: 10.1182/bloodadvances.2020001852.
 11. Wang ZY, Li YX, Wang WH, Jin J, Wang H, Song YW, et al. Primary radiotherapy showed favorable outcome in treating extranodal nasal-type NK/T-cell lymphoma in children and adolescents. *Blood.* 2009; 114(23):4771-6. doi: 10.1182/blood-2009-07-235853.
 12. Yahalom J, Illidge T, Specht L, Hoppe RT, Li YX, Tsang R, et al. Modern radiation therapy for extranodal lymphomas: field and dose guidelines from the International Lymphoma Radiation Oncology Group. *Int J Radiat Oncol Biol Phys.* 2015;92(1):11-31. doi: 10.1016/j.ijrobp.2015.01.009.
 13. Wang HY, Niu SQ, Yang YY, Li YY, Chen HB, Zhang YJ. Promising clinical outcomes of sequential and "Sandwich" chemotherapy and extended involved-field intensity-modulated radiotherapy in patients with stage IE /IIE extranodal natural killer/T-cell lymphoma. *Cancer Med.* 2018;7(12):5863-9. doi: 10.1002/cam4.1755.