

An Immunohistochemical Study of Vascular Endothelial Growth Factor Expression in Meningioma and Its Correlation with Tumor Grade

Parvin Mahzouni, Elham Aghili*, Behnaz Sabaghi

Department of Pathology, School of Medicine, Isfahan University of Medical Sciences, Isfahan, Iran

Abstract

Background: Meningiomas are one of the most common primary brain tumors and the most common intradural spinal tumors. Vascular endothelial growth factor has been demonstrated to play an important role in the stimulation of angiogenesis in many types of cancers. Agents that block the vascular endothelial growth factor pathway, such as bevacizumab, have the capability to decrease vascular permeability. The aim of this study is to evaluate vascular endothelial growth factor expression in meningioma patients.

Methods: This retrospective, cross-sectional study used an immunohistochemical method to assess vascular endothelial growth factor expression in meningioma. We randomly chose 83 paraffin-embedded tissue blocks of meningiomas diagnosed during 2015 from the files of the Pathology Laboratory of Al-Zahra Hospital, affiliated with Isfahan University of Medical Sciences, Iran.

Results: All of the meningioma samples (100%) were vascular endothelial growth factor-immunoreactive. There was a vascular endothelial growth factor score of 1 in 6 (7.2%) cases, a score of 2 in 54 (65.1%) cases, and score of 3 in 23 (27.7%) cases. A correlation existed between vascular endothelial growth factor score and tumor grade. However, there was no correlation between vascular endothelial growth factor score and age and sex of patients.

Conclusion: Our study demonstrated a significant role of vascular endothelial growth factor expression in the pathogenesis of peritumoral brain edema in low- and high-grade meningiomas as well as in recurrence or malignant transformation. Thus, anti-vascular endothelial growth factor agents such as bevacizumab might be useful as a treatment of this condition.

Keywords: Meningioma, VEGF expression, Stage

♦Corresponding Author:

Elham Aghili, MD
Department of Pathology,
School of Medicine, Isfahan
University of Medical Sciences,
Isfahan, Iran
Tel: +989132262447
Email: aghili_elham@yahoo.com

Introduction

Meningiomas are one of the most common primary brain tumors and one of the most common intradural spinal tumors. Hospital-based series have reported that approximately 20% of all primary brain tumors are meningiomas; however, autopsy reports are closer to 30%. Despite the large majority that are categorized as benign lesions, there is a great variation in histology, recurrence rates, aggressiveness, symptoms, and survival outcomes.^{1,2} Meningiomas are conventionally divided into three groups: benign (grade I), atypical (grade II), and malignant or anaplastic (grade III). The 2007 World Health Organization (WHO) classification of tumors of the central nervous system (CNS) lists 16 various subtypes of meningioma, divided into 3 grade categories (Table 1). Grade I tumors account for approximately 70%-80% of meningiomas, whereas grade II accounts for 19%-27%, and grade III accounts for 1%-3% of meningiomas.^{3,4}

Angiogenesis is dependent upon the balance between angiogenic and anti-angiogenic regulators. Vascular endothelial growth factor (VEGF) has been demonstrated to play an important role in the stimulation of angiogenesis in many types of cancers.⁵⁻⁷ Most brain tumors over secrete VEGF which leads to an impaired permeable tumor vasculature. This hyper permeability permits fluid to leak from the

intravascular space into the brain parenchyma, which causes vasogenic cerebral edema and increased interstitial fluid pressure. Agents that block the VEGF pathway (such as bevacizumab) have the capability to decrease vascular permeability. More than 50 years after the introduction of corticosteroids for the treatment of vasogenic cerebral edema, vascular normalization by anti-VEGF agents are promising as efficient therapeutic mechanisms for progression and recurrence of brain tumors.^{8,9}

A few studies have reported the relationship between meningioma and VEGF expression, with different results. Despite the higher vascularity encountered in high-grade tumors, the correlation between histological grade and VEGF expression in meningiomas is not as clear. The aim of this study is to evaluate VEGF expression in meningiomas. We also have assessed the correlation between tumor grade and VEGF expression by immunohistochemical (IHC) methods.

Materials and Methods

Case selection

This retrospective, cross-sectional study used an IHC method to assess VEGF expression in meningiomas. We randomly selected 83 paraffin-embedded tissue blocks of meningiomas diagnosed during 2015 from the files of the

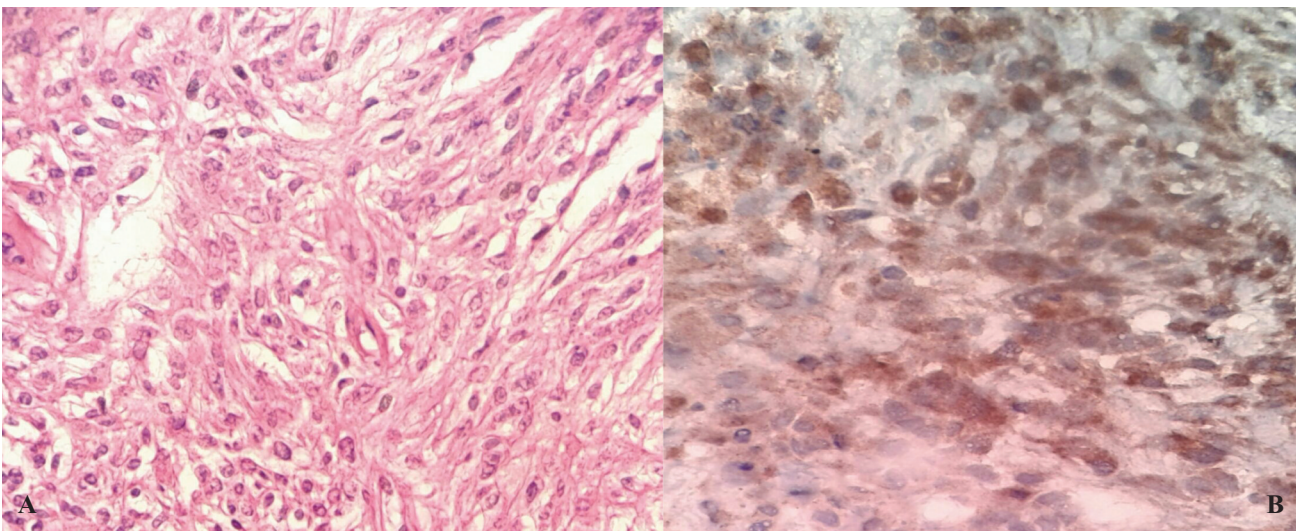


Figure 1. A) Meningothelial cells arranged in whorling pattern [hematoxylin and eosin (H&E); 100 \times]. B) Vascular endothelial growth factor (VEGF) expression in meningioma [Immunohistochemical (IHC) staining; 400 \times].

Table 1. Meningioma subtypes and grades according to the 2007 World Health Organization (WHO) classification.¹²

WHO grade	Histological subtypes
I	Meningothelial, fibroblastic, transitional, psammomatous, angiomatous, microcystic, secretory, lymphoplasmacytic, metaplastic
II	Atypical, chordoid, clear cell, brain invasive
III	Anaplastic, papillary, rhabdoid

Pathology Laboratory of Al-Zahra Hospital, affiliated with Isfahan University of Medical Sciences, Iran. The Ethics Committee at Isfahan University of Medical Sciences, Isfahan, Iran approved this study (Approval code: 394146).

Study design

In this retrospective cross-sectional study, we defined the inclusion criteria as: (1) paraffin-embedded blocks of meningioma which had adequate tissue to section and (2) cases of meningioma for which clinical data were available.

Immunohistochemistry for vascular endothelial growth factor (VEGF)

Initially, we obtained and reviewed the archived hematoxylin and eosin (H&E) stained slides of the meningiomas to determine their histological subtypes and grades according to the 2007 WHO classification. Subsequently, IHC staining was performed as follows.^{10,11} We prepared 3- μ m thick sections from each paraffin block. Next, the sections were dewaxed and rehydrated in a graded alcohol series. For antigen retrieval, we applied a heat-induced method. Endogenous peroxidase activity was blocked using H₂O₂ 3%. The slides were incubated with anti-VEGF antibody (mouse monoclonal antibody against VEGF-189 isoform, Clone VG1, Dako) at room temperature. The slides were incubated with EnVision polymer for 30 min at room temperature. The slides were treated with DAB chromogen

followed by counterstaining and dehydration. Intervening washing was carried out (Washing was done) with tris-buffered saline (pH 7.6).

Statistical analysis

The mounted slides were assessed by two pathologists. The results were recorded and analyzed by SPSS-22 software. *P*-values less than 0.05 were considered to be significant. For interpretation of VEGF immunoreactivity, we used the latest scoring system (Table 2).

Results

In the present study we enrolled 83 patients (56 males and 27 females) with meningioma. The mean age of cases was 59.6 years (range: 14 to 91 years). There were 62 (74.7%) grade I tumors, 18 (21.7%) grade II tumors, and 3 (3.6%) grade III tumors (Table 3).

The most common subtypes of meningioma were transitional (38.6%), fibroblastic (15.7%), and atypical (16.9%).

All meningioma samples (100%) were VEGF-immunoreactive. A total of 6 (7.2%) of the samples had a VEGF score of 1, 54 (65.1%) had a score of 2, and 23 (27.7%) had a score of 3 (Figure 1). There was a correlation between VEGF score and tumor grade ($r=0.2$, $P=0.03$). However, there was no correlation between VEGF score and age and sex of patients ($P=0.83$). No significant association existed between VEGF score and the tumor subtypes. Table 4 lists the tumor characteristics.

Table 2. Vascular endothelial growth factor (VEGF) immunoreactivity scoring system.

Score 0	Negative
Score 1	Weak reaction in less than 10% of tumor cells.
Score 2	Weak to moderate reaction in 10%-50% of tumor cells.
Score 3	Strong or moderate intensity in more than 50% of tumor cells.

Table 3. Vascular endothelial growth factor (VEGF) staining score for each grade of meningioma.

VEGF score	WHO grade I		WHO grade II		WHO grade III	
	Percent	Number	Percent	Number	Percent	Number
1	9.7	6	0	0	0	0
2	66.10	41	72.2	13	0	0
3	24.2	15	27.8	5	100	3
Total	100	62	100	18	100	3

WHO: World Health Organization.

Discussion

The human VEGF gene, located on chromosome 6q21.3, contains 8 exons separated by 7 introns. Alternative exon splicing results in generation of 6 different isoforms – VEGF-121, VEGF-145, VEGF-165, VEGF-183, VEGF-189, and VEGF-206. The antibody labels the VEGF-121, VEGF-165, and VEGF-189 isoforms of VEGF. Most brain tumors oversecrete VEGF, which leads to an abnormally permeable tumor vasculature. This hyper permeability lets fluid to leak from the intravascular space into the brain parenchyma that causes increased interstitial fluid pressure and vasogenic cerebral edema.⁹ A positive correlation between VEGF and edema has been found in a number of previous studies. VEGF is a regulator of vasculogenesis, angiogenesis, and vascular permeability. It may play a critical role in the formation of peritumoral brain edema (PTBE) associated with meningiomas.^{13,14}

Huang et al. studied VEGF in all types of brain tumors. As evidenced by real-time RT2PCR and immunocytochemistry, all tumor sample types expressed VEGFR1 (Flt-1) and -2 (Flk-1), but in different amounts and locations.¹⁵

Metastatic tumors, medulloblastomas, oligoastrocytoma III, and oligodendroglioma II show only a moderate VEGFR expression compared with meningiomas and glioblastomas, despite the fact that the metastatic kidney tumor produced considerably more VEGF. However, since metastatic tumors and medulloblastomas are clinically malignant and grow rapidly, the tumor cells easily lead to hypoxia which could be responsible for VEGFR expression.¹⁵

Vokuda et al. conducted a similar study in an Indian population with astrocytomas (12 diffuse astrocytomas, 3 oligodendrogliomas, 2 anaplastic

astrocytomas, 13 anaplastic oligodendrogliomas, and 30 glioblastomas). They concluded that VEGF expression was associated with tumor grade. The results indicated that VEGF-regulated angiogenesis played an important role in tumor progression of astrocytomas and oligodendrogliomas.¹⁶

Solid brain tumors of various histologies have been found to secrete significant amounts of VEGF into cyst fluid, with maximum VEGF levels in recurrent glioblastoma and brain metastasis. These data confirm and extend previous findings of high VEGF levels in cyst fluid of glioblastomas and suggest a role of VEGF in local tumor progression and metastasis.^{17,18}

A number of studies indicate the bi-functional role of VEGF in the biology of brain tumors which regulates both angiogenesis and vascular permeability. An association has been shown between VEGF expression in glioblastomas and meningiomas with peritumoral edema. Vascular endothelial growth factor highly expresses in glioblastoma tissue, being most abundant in the perinecrotic palisading cells, but also in cyst fluids from glioblastomas.¹⁹

Effective therapy for patients with recurrent/progressive meningioma after surgery and radiation therapy is an unmet need in neuro-oncology. Pre-clinical studies have suggested that microvessel density and VEGF expression appear to increase with increasing meningioma grade,^{20,21} which suggests that anti-VEGF therapies may be active in this setting. Bevacizumab, administered as a single-agent or in combination with chemotherapy, has activity for patients with recurrent/progressive meningioma and can be safely administered. However, findings are limited by the overall small number of patients evaluated

and the retrospective nature of our analysis. Prospective studies of anti-VEGF/VEGFR therapeutics are warranted for recurrent/progressive meningioma patients.²² Bevacizumab is well-tolerated in patients with meningioma, and may be considered in patients who have exhausted radiation and surgical options. Prospective studies are required to define the safety and efficacy of bevacizumab in atypical and anaplastic meningiomas.²³

The pattern of VEGF expression in meningiomas has been variably reported in the literature. Some authors reported that VEGF expression was specific to the tumor cells and not present in the tumor stroma, connective tissue, or endothelial cells.^{24,25} Another study noted that VEGF expression was found in the neighboring endothelial cells.²⁶ We found degrees of VEGF positivity in the neighboring endothelial cells in some cases. A paracrine role of VEGF in inducing angiogenesis could be postulated by its presence both in tumor cells as well as in neighboring cells. Similar expression of VEGF in both tumor cells and surrounding vessels in gliomas has been reported.²⁷ The extent of VEGF expression needs to be scored so that accurate classification and reporting is possible. As with any IHC evaluation, both the intensity of staining and the percentage of positive cells need to be taken into consideration. Various scoring methods have been described for VEGF immunohistochemistry in tumors.^{28,29} Meningiomas are still poorly examined tumors and the predictive factors are less known than in other primary brain tumors. Peritumoral brain edema is one of the most important factors that leads to worse postoperative recovery and clinical outcome. Our study seems to prove a significant role VEGF expression in the pathogenesis of PTBE in low-and high-grade meningiomas as well as in recurrence or malignant transformation. Hence, VEGF may be a useful prognostic factor for worse clinical outcome of meningiomas.

Table 4. Tumor characteristics of the meningiomas.

Variables		Percent (%)
Type of tumor	Transitional	38.6
	Fibroblastic	15.7
	Syncytial	16.9
	Secretory	1.2
	Psammomatous	1.2
	Angiomatous	1.2
	Atypical	16.9
	Chordoid	4.8
	Anaplastic	3.5
VEGF score	1	7.2
	2	65.1
	3	27.7
Tumor grade	I	74.7
	II	21.7
	III	3.6

VEGF: Vascular endothelial growth factor

Conclusion

Meningiomas are quite poorly studied tumors, and the predictive features are less identified than in other brain tumors. Peritumoral brain edema, recurrence, and progression are the most important factors that determine clinical outcome. Our study has demonstrated a significant role for VEGF expression in the pathogenesis of PTBE in low-and high-grade meningiomas as well as in recurrence or malignant transformation.

Conflict of Interest

None declared.

References

1. Saraf S, McCarthy BJ, Villano JL. Update on meningiomas. *Oncologist*. 2011;16(11):1604-13. doi: 10.1634/theoncologist.2011-0193.
2. Schellinger KA, Propp JM, Villano JL, McCarthy BJ. Descriptive epidemiology of primary spinal cord tumors. *J Neurooncol*. 2008;87(2):173-9.
3. Mahzouni P, Movahedipour M. An immunohistochemical study of HER2 expression in meningioma and its correlation with tumor grade. *Pathol Res Pract*. 2012;208(4):221-4. doi: 10.1016/j.prp.2012.01.009.
4. Rogers L, Gilbert M, Vogelbaum MA. Intracranial meningiomas of atypical (WHO grade II) histology. *J Neurooncol*. 2010;99(3):393-405. doi: 10.1007/s11060-010-0343-1.

5. Rooprai HK, Martin AJ, King A, Appadu UD, Jones H, Selway RP, et al. Comparative gene expression profiling of ADAMs, MMPs, TIMPs, EMMPRIN, EGF-R and VEGFA in low grade meningioma. *Int J Oncol*. 2016;49(6):2309-18. doi: 10.3892/ijo.2016.3739.
6. Nassehi D. Intracranial meningiomas, the VEGF-A pathway, and peritumoral brain oedema. *Dan Med J*. 2013;60(4):B4626.
7. Dietrich J, Rao K, Pastorino S, Kesari S. Corticosteroids in brain cancer patients: benefits and pitfalls. *Expert Rev Clin Pharmacol*. 2011;4(2):233-42. doi: 10.1586/ecp.11.1.
8. Hawasli AH, Rubin JB, Tran DD, Adkins DR, Waheed S, Hullar TE, et al. Antiangiogenic agents for nonmalignant brain tumors. *J Neurol Surg B Skull Base*. 2013;74(3):136-41. doi: 10.1055/s-0033-1338262.
9. Gerstner ER, Duda DG, di Tomaso E, Ryg PA, Loeffler JS, Sorensen AG, et al. VEGF inhibitors in the treatment of cerebral edema in patients with brain cancer. *Nat Rev Clin Oncol*. 2009;6(4):229-36. doi: 10.1038/nrclinonc.2009.14.
10. Pfister C, Pfrommer H, Tatagiba MS, Roser F. Vascular endothelial growth factor signals through platelet-derived growth factor receptor β in meningiomas *in vitro*. *Br J Cancer*. 2012;107(10):1702-13. doi: 10.1038/bjc.2012.459.
11. Reszec J, Hermanowicz A, Rutkowski R, Turek G, Mariak Z, Chyczewski L. Expression of MMP-9 and VEGF in meningiomas and their correlation with peritumoral brain edema. *Biomed Res Int*. 2015;2015:646853. doi: 10.1155/2015/646853.
12. Louis DN, Ohgaki H, Wiestler OD, Cavenee WK (eds), 2007. WHO Classification of tumours of the central nervous system. IARC, Lyon.
13. Ding YS, Wang HD, Tang K, Hu ZG, Jin W, Yan W. Expression of vascular endothelial growth factor in human meningiomas and peritumoral brain areas. *Ann Clin Lab Sci*. 2008;38(4):344-51.
14. Kim BW, Kim MS, Kim SW, Chang CH, Kim OL. Peritumoral brain edema in meningiomas: correlation of radiologic and pathologic features. *J Korean Neurosurg Soc*. 2011;49(1):26-30. doi: 10.3340/jkns.2011.49.1.26.
15. Huang H, Held-Feindt J, Buhl R, Mehdorn HM, Mentlein R. Expression of VEGF and its receptors in different brain tumors. *Neurol Res*. 2005;27(4):371-7.
16. Vokuda RS, Srinivas BH, Madhugiri VS, Verma SK. Vascular endothelial growth factor as an angiogenic marker in malignant astrocytoma and oligodendroglioma: An Indian scenario. *J Clin Diagn Res*. 2017;11(2): EC05-EC07. doi: 10.7860/JCDR/2017/24353.9331.
17. Weindel K, Moringlane JR, Marmé D, Weich HA. Detection and quantification of vascular endothelial growth factor/vascular permeability factor in brain tumor tissue and cyst fluid: the key to angiogenesis? *Neurosurgery*. 1994;35(3):439-48; discussion 448-9.
18. Criscuolo GR. The genesis of peritumoral vasogenic brain edema and tumor cysts: a hypothetical role for tumor-derived vascular permeability factor. *Yale J Biol Med*. 1993;66(4):277-314.
19. Plate KH, Breier G, Weich HA, Risau W. Vascular endothelial growth factor is a potential tumour angiogenesis factor in human gliomas *in vivo*. *Nature*. 1992;359(6398):845-8.
20. Maiuri F, De Caro MB, Esposito F, Cappabianca P, Strazzullo V, Pettinato G, et al. Recurrences of meningiomas: predictive value of pathological features and hormonal and growth factors. *J Neurooncol*. 2007;82(1):63-8.
21. Pistolesi S, Boldrini L, Gisfredi S, De Ieso K, Camacci T, Caniglia M, et al. Angiogenesis in intracranial meningiomas: immunohistochemical and molecular study. *Neuropathol Appl Neurobiol*. 2004;30(2):118-25.
22. Lou E, Sumrall AL, Turner S, Peters KB, Desjardins A, Vredenburgh JJ, et al. Bevacizumab therapy for adults with recurrent/progressive meningioma: a retrospective series. *J Neurooncol*. 2012;109(1):63-70. doi: 10.1007/s11060-012-0861-0.
23. Nayak L, Iwamoto FM, Rudnick JD, Norden AD, Lee EQ, Drappatz J, et al. Atypical and anaplastic meningiomas treated with bevacizumab. *J Neurooncol*. 2012;109(1):187-93. doi: 10.1007/s11060-012-0886-4.
24. Schmid S, Aboul-Enein F, Pfisterer W, Birkner T, Stadek C, Knosp E. Vascular endothelial growth factor: the major factor for tumor neovascularization and edema formation in meningioma patients. *Neurosurgery*. 2010;67(6):1703-8; discussion 1708. doi: 10.1227/NEU.0b013e3181fb801b.
25. Provias J, Claffey K, delAguila L, Lau N, Feldkamp M, Guha A. Meningiomas: role of vascular endothelial growth factor/vascular permeability factor in angiogenesis and peritumoral edema. *Neurosurgery*. 1997;40(5):1016-26.
26. Dharmalingam P, Roopesh Kumar VR, Verma SK. Vascular endothelial growth factor expression and angiogenesis in various grades and subtypes of meningioma. *Indian J Pathol Microbiol*. 2013;56(4):349-54. doi: 10.4103/0377-4929.125286.
27. Dvorak HF, Brown LF, Detmar M, Dvorak AM. Vascular permeability factor/vascular endothelial growth factor, microvascular hyperpermeability, and angiogenesis. *Am J Pathol*. 1995;146(5):1029-39.
28. Klein M, Picard E, Vignaud JM, Marie B, Bresler L, Toussaint B, et al. Vascular endothelial growth factor gene and protein: strong expression in thyroiditis and thyroid carcinoma. *J Endocrinol*. 1999;161(1):41-9.
29. Klein M, Vignaud JM, Hennequin V, Toussaint B,

Bresler L, Plénat F, et al. Increased expression of the vascular endothelial growth factor is a pejorative prognosis marker in papillary thyroid carcinoma. *J Clin Endocrinol Metab.* 2001;86(2):656-8.