

# Intracranial Atypical Teratoid/Rhabdoid Tumor during Infancy: A Case Report

Bitá Geramizadeh<sup>\*,\*\*\*</sup>, Mohammad Reza Farzaneh<sup>\*</sup>,  
Ahmad Kamgarpour<sup>\*\*\*</sup>

*\*Department of Pathology, Shiraz University of Medical Sciences, Shiraz, Iran*

*\*\*Transplant Research Center, Shiraz University of Medical Sciences, Shiraz, Iran*

*\*\*\*Department of Neurosurgery, Shiraz University of Medical Sciences, Shiraz, Iran*

## Abstract

Central nervous system atypical teratoid/rhabdoid tumor during infancy is a rare, highly aggressive tumor most commonly seen in the cerebellar area. Herein we describe the case of a 4-month-old baby who presented with convulsions. Pathologic examination of her cerebellar mass showed an atypical teratoid/rhabdoid tumor. The patient died 5 days after surgery despite complete excision of the mass and prior to chemoradiation. Histopathologic diagnosis of this tumor type should be considered in posterior fossa masses of children, particularly before the age of 2 years, because the treatment protocol and prognosis of this tumor completely differ from other tumors of this region such as medulloblastoma and primitive neuroectodermal tumors.

**Keywords:** Atypical teratoid/rhabdoid tumor of infancy, Brain, Infant

## Introduction

Atypical teratoid/rhabdoid tumor (AT/RT) is a highly malignant intracranial tumor initially described in 1987 by Lefkowitz et al.<sup>1</sup> This tumor has a unique histologic feature composed of a combination of rhabdoid cells, neuroepithelial, epithelial and mesenchymal elements.<sup>2</sup>

Because of a rather unfamiliar pathological entity, it is frequently misdiagnosed as a primitive neuroectodermal/medulloblastoma

(PNET/MB). However, the prognosis and response to treatment vastly differ in these two tumors. We have reported our experience with this rare tumor, which was the first case in our center, as a referral center.

### Corresponding Author:

Bitá Geramizadeh, MD  
Department of Pathology,  
Shiraz University of Medical  
Sciences, Shiraz, Iran  
Tel/fax: +98-713-6474331  
Email: geramib@sums.ac.ir



## Case report

A 4-month-old girl was admitted to Nemazee hospital affiliated to Shiraz University of Medical Sciences, with recurrent intractable seizures for 2 months, without vomiting or fever. Her mother's pregnancy was uneventful and the baby was born at term without any complications. Physical examination was unremarkable and the patient had normal chest and abdomen examinations with normal neurological examination of cranial nerves and upper as well as lower extremities. Laboratory findings showed normal complete blood count, BUN/Cr, FBS, Na/K and calcium. Electroencephalopathy was normal.

MRI of brain with gadolinium showed a large mass in the posterior fossa that involved the left cerebellar hemisphere and pons. The mass measured approximately 5 cm in largest diameter and had a cystic component (Figure 1).

The patient underwent surgical excision of the mass. After the suboccipital incision, a large mass was exposed in the right cerebellar hemisphere. Frozen section diagnosis of the tumor was positive for malignancy in favor of medulloblastoma. Pathologic examination of the permanent formalin-fixed tissue of the tumor revealed high cellularity composed of undifferentiated large and pale cells (rhabdoid cells) with moderate amounts of slightly eosinophilic or pale cytoplasm. They were admixed with a number of small round cells with scant cytoplasm. There were numerous mitotic figures observed (Figure 2a, b).

Immunohistochemistry of the above-mentioned cells showed reactions to vimentin (Figure 3a), EMA (Figure 3b) and glial fibrillary acidic protein (GFAP). Ki-67 was positive in more than 90% of the tumor cells. The patient was diagnosed with AT/RT. Unfortunately, 5 days after surgery and prior to onset of chemotherapy, the patient died in the intensive care unit (ICU) with cardiorespiratory arrest.

## Discussion

Atypical teratoid/rhabdoid tumor of the central nervous system (CNS) is a rare, highly malignant tumor of infancy and childhood comprising 1%-

3% of primary CNS tumors in the pediatric population.<sup>3</sup> The vast majority of these tumors occur during the first 2 years of life.<sup>2</sup> The most common location is infratentorial, in the posterior fossa and cerebellum.<sup>4</sup>

Our patient was a 4-month-old baby who presented with intractable seizures and a large cerebellar mass.

Atypical teratoid/rhabdoid tumor is a histologically mixed tumor which contains a combination of rhabdoid cells and primitive neuroectodermal tumor-like areas.<sup>3</sup> Rhabdoid cells are of a large-to-medium size with a moderate amount of eosinophilic or pale cytoplasm. Nuclei are elongated, reniform, oval and polygonal with small moderately prominent nuclei.<sup>2</sup> Numerous mitotic figures are common histologic findings of AT/RT. In addition to the above-mentioned cells, AT/RTs contain varying percentages of PNET cells and cells with epithelial differentiation as well as malignant mesenchymal cells.<sup>4</sup> Variable immunohistochemical staining results have been reported in previous studies, but most reported cases were positive for EMA, vimentin and SMA. Ki-67 as a marker of cell proliferation has been shown to be significantly elevated in AT/RT.<sup>2</sup> According to the differential diagnosis, PNET/MB is a major concern. Presence of rhabdoid cells and reactivity with EMA is against the diagnosis of

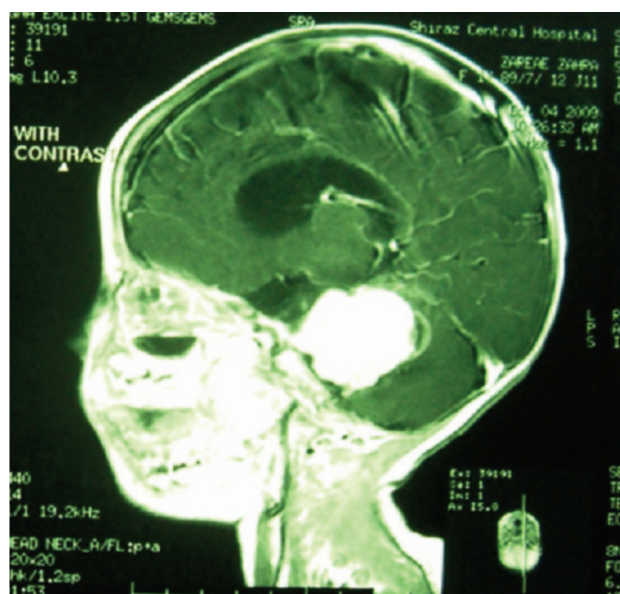
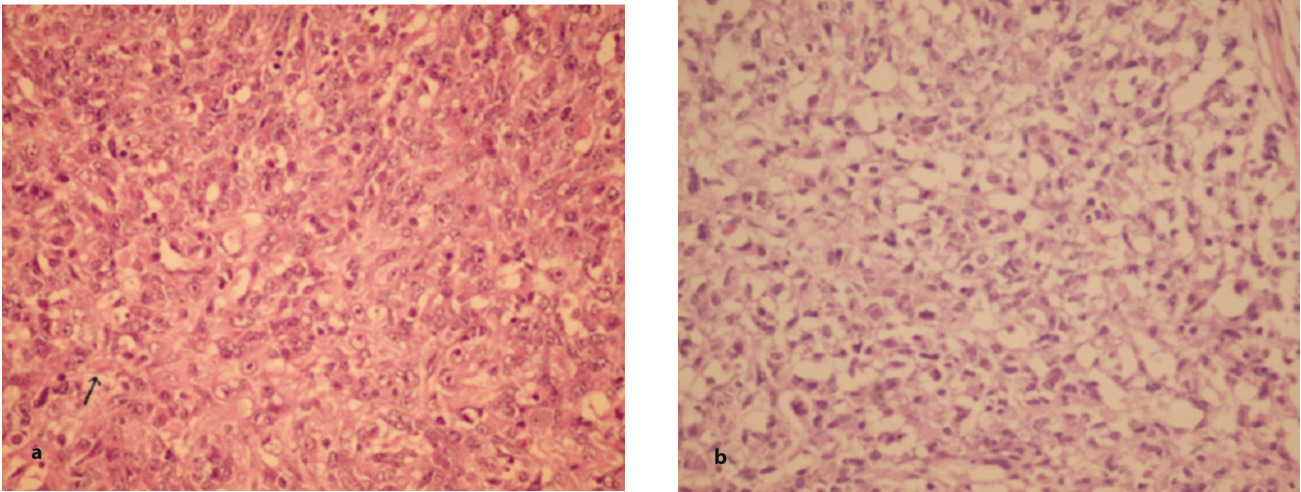


Figure 1. MRI of the brain with gadolinium.



**Figure 2.** (a) Sections from the brain tumor show hypercellular tumor composed of highly atypical malignant cells with rhabdoid features (H&E, 250 $\times$ ). (b) Microscopic foci of tumor shows small cell components (H&E, 250 $\times$ ).

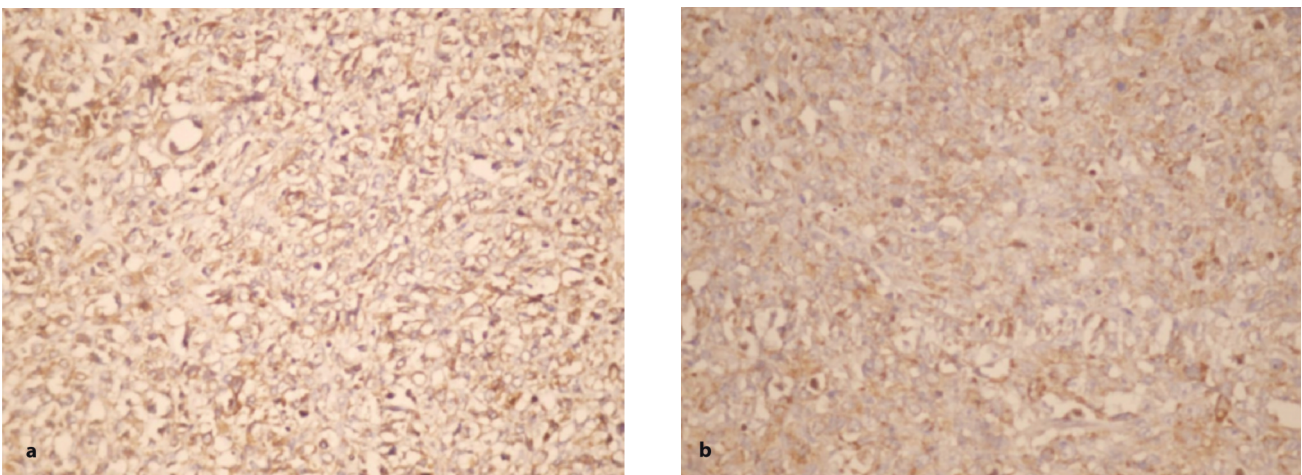
PNET/MB, which was seen in our case.<sup>5</sup>

Treatment of this tumor is not curative and therapeutic approaches include surgery, chemotherapy and radiotherapy.<sup>6</sup> MR imaging and CT features of AT/RT are inhomogeneous, with multiple cystic/necrotic and solid components.<sup>7</sup>

Atypical teratoid/rhabdoid tumors, although rare, should be considered in the differential diagnosis of CNS tumors in patients under the age of 2 years because correct diagnosis is essentially important for intensive treatment which differs from standard treatment of PNET/MB.

### Conflict of Interest

No conflict of interest is declared.



**Figure 3.** (a) Vimentin positive tumor cells. (b) EMA positive tumor cells.

## References

1. Lefkowitz IB, Rorke LB, Packer RJ, Sutton LN, Siegel KR, Katnick RJ. Atypical teratoid tumor of infancy: definition of an entity. *Ann Neurol*. 1987;22(3):448.
2. Ho DM, Hsu CY, Wong TT, Ting LT, Chiang H. Atypical teratoid/rhabdoid tumor of the central nervous system: a comparative study with primitive neuroectodermal tumor/medulloblastoma. *Acta Neuropathol*. 2000;99(5):482-8.
3. Arslanoglu A, Aygun N, Tekhtani D, Aronson L, Cohen K, Burger PC, et al. Imaging findings of CNS atypical teratoid/rhabdoid tumors. *AJNR Am J Neuroradiol*. 2004;25(3):476-80.
4. Meyers SP, Khademian ZP, Biegel JA, Chuang SH, Korones DN, Zimmerman RA. Primary intracranial atypical teratoid/rhabdoid tumors of infancy and childhood: MRI features and patient outcomes. *AJNR Am J Neuroradiol*. 2006;27(5):962-71.
5. Packer RJ, Biegel JA, Blaney S, Finlay J, Geyer JR, Heideman R, et al. Atypical teratoid/rhabdoid tumor of the central nervous system: report on workshop. *J Pediatr Hematol Oncol*. 2002;24(5):337-42.
6. Rahmat K, Kua CH, Ramli N. A child with atypical teratoid/rhabdoid tumour of the posterior cranial fossa. *Singapore Med J*. 2008;49(12):e365-8.
7. Utsuki S, Oka H, Tanaka S, Kondo K, Tanizaki Y, Fujii K. Importance of re-examination for medulloblastoma and atypical teratoid/rhabdoid tumor. *Acta Neurochir (Wien)*. 2003;145(8):663-6; discussion 666.