

Case Report

Middle East Journal of Cancer; April 2023; 14(2): 327-331

Adenosquamous Carcinoma of the Colon: A Report of Two Cases and Literature Review

Mohammad Zuhdy*, MD, Reham Alghandour**, MD, Mohamed Elhawary***, MD,
Islam H. Metwally*†, MD, MRCS, Farida A. Shokeir****, MSc

*Surgical Oncology Department, Oncology Center Mansoura University (OCMU),
Mansoura, Egypt

**Medical Oncology Department, Oncology Center Mansoura University (OCMU),
Mansoura, Egypt

***Radiology Department, Mansoura University Hospitals (MUH), Mansoura, Egypt

****Pathology Department, Mansoura University Hospitals (MUH), Mansoura, Egypt

Please cite this article as: Zuhdy M, Alghandour R, Elhawary M, Metwally IH, Shokeir FA. Adenosquamous carcinoma of the colon: a report of two cases and literature review. Middle East J Cancer. 2023;14(2):327-31. doi: 10.30476/mejc.2022.92185.1648.

Abstract

Colon cancer is one of the commonest tumours in the world. Although most colon cancer patients are colonized by adenocarcinoma, some other pathologies such as adenosquamous carcinoma are rarely encountered. We present two patients with right colon adenosquamous carcinoma. Both patients were males and both suffered a node-positive disease. Furthermore, one of them developed recurrence 7 months after initial radical surgery, despite formal colon adjuvant chemotherapy given. In conclusion, the patients with adenosquamous colon cancer are a subgroup with a worse prognosis, and questionable response to the conventional chemotherapeutic regimens as FOLFOX (flourouracil, leucovorin, and oxaloplatin) and CAPEOX (capecitabine and oxaloplatin).

Keywords: Carcinoma, Adenosquamous, Colon Neoplasms

Introduction

Colorectal cancer is the third most commonly diagnosed cancer in the world and the second cause of cancer death.¹ The most common pathological subtype of colon cancer is adenocarcinoma.² In contrast, rare pathological subgroups of colon cancer include adenosquamous carcinoma, sarcomas, lymphomas, and neuroendocrine tumors.³ With a reported incidence of 2 to 4% for lung cancer and 0.38 to 10% for pancreatic carcinoma, adenosquamous

carcinoma has been shown to occur in a variety of organs, including the lung, pancreas, and colon. The least incidence was documented in the colon comprising approximately 0.1% of colon cancer.⁴ Due to scarce reports, there are no concise data about presentation, clinical outcomes, and management of these patients.⁵ Hence, we report two cases of colonic adenosquamous carcinoma, their management, and prognosis.

Corresponding Author:

Islam H. Metwally, MD, MRCS
Surgical Oncology Department,
Oncology Center Mansoura
University (OCMU), Mansoura,
Egypt
Email: drislamhany@mans.edu.eg



Received: July 29, 2021; Accepted: July 02, 2022

Case Presentation

The case report was approved by the institutional review board of the faculty of medicine Mansoura University (IRB-MFM) with code number R 22.04.1690.

Case 1

A 56-year-old man smoker who previously had stomach discomfort visited our hospital. His medical and surgical background were irrelevant. Abdominal ultrasonography and computed tomography (CT) were used to assess his complaint. The CT indicated an exophytic heterogeneously enhancing mass including the hepatic flexure and the upper third of the ascending colon as well as enlarged pericolic lymph nodes (LNs) (Figure 1). The patient performed a colonoscopy that revealed a fungating cauliflower mass at the hepatic flexure which was biopsied to reveal moderately differentiated squamous cell carcinoma that was confirmed by diffuse cytoplasmic positivity to immune histochemical stain CK 5/6 (Figure 2). Carci-

noembryonic antigen (CEA) level was 10.61 ng/ml, while cancer antigen 19-9 was 0.6 u/ml. The case was discussed at the multidisciplinary tumour board (MDT) of our hospital and surgery was decided.

An upper midline laparotomy approach was selected to perform right hemicolectomy along with complete mesocolic excision followed by end-to-end ileo-transverse hand-sewn anastomosis after exclusion of any peritoneal or hepatic metastasis. The patient experienced a smooth postoperative course.

Postoperative pathological assessment revealed malignant tumoural proliferation formed of malignant epithelial cells reaching down to the subserosa. These were arranged both as glandular elements lined by cells showing pleomorphism, hyperchromasia, with a moderate degree of atypia with detected mucin component. They were admixed with sheets of malignant squamous cells, entrenched in the desmoplastic stroma, with limited keratin pearl production (Figure 3). Since there were discrete rather than arbitrary

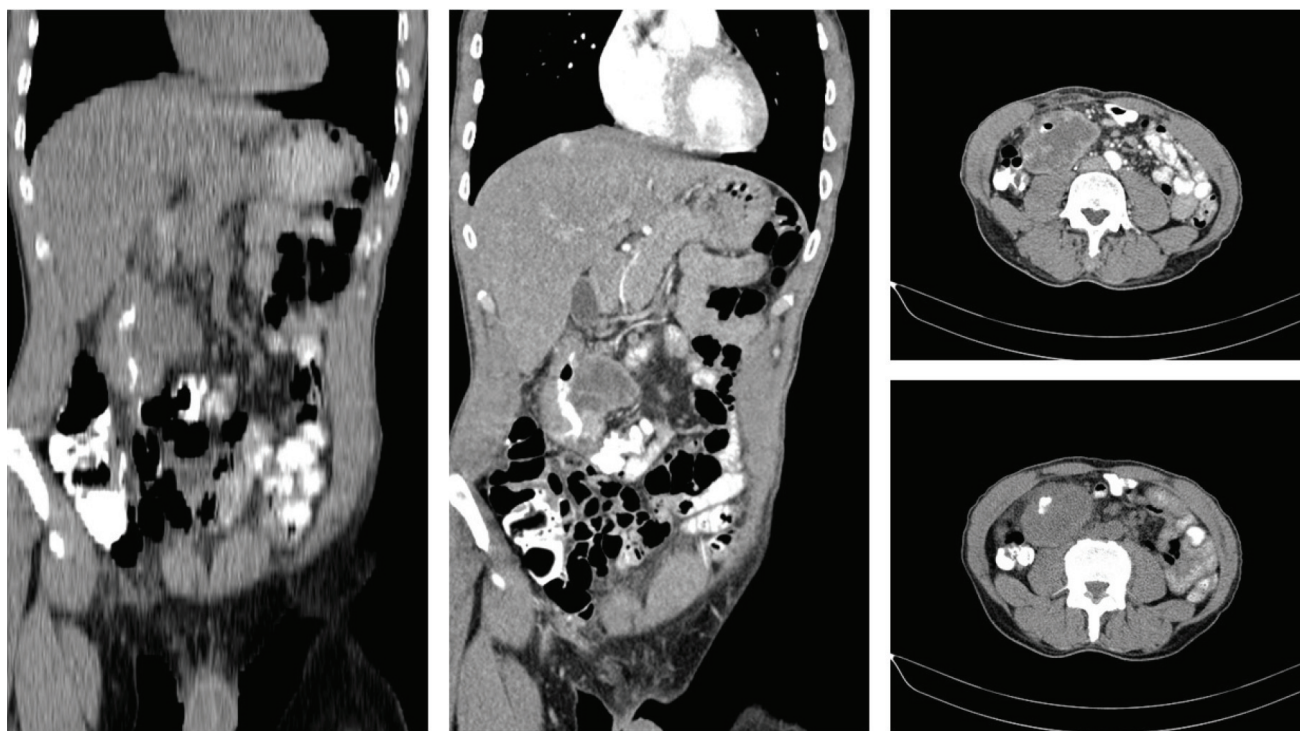


Figure 1. Sagittal and coronal sections of a post-contrast CT scan of the abdomen and pelvis showing a well-defined long segment of irregular circumferential wall thickening associated with significant luminal narrowing is seen involving the hepatic flexure as well as the related upper third of the ascending colon. It is associated with large extra-luminal exophytic heterogeneously enhanced mass extending posteromedial abutting related right psoas muscle.

CT: Computed tomography

configurations of both the malignant squamous and malignant epithelial components, adenosquamous carcinoma (composite type) was determined to be the cause. Dissected surrounding LNs showed infiltration in 2 out of 40 LNs by the same tumour tissue tumor, node, and metastasis (TNM) staging: pT3N1M0). The patient was subjected to 8 cycles of CAPEOX regimen after which he was maintained on follow-up till writing this report, 15 months from starting the active treatment.

Case 2

A 49 years-old male patient with irrelevant medical history, had a right hemicolectomy for adenosquamous carcinoma of the ascending colon. The histopathological examination revealed adenosquamous carcinoma infiltrating down to the subserosal fat with detected lymphovascular emboli and no detected perineural invasion. The adenocarcinoma component was positive for CK7 and CDX2, while the squamous component was positive for p63. Nine out of the 29 LNs that were evaluated had adenocarcinoma component

infiltration. In addition to the free appendix, both surgical margins were devoid of tumor tissue. Stage IIIC of the AJCC staging was pT3N2aM0. The patient had six rounds of the FOLFOX treatment as adjuvant chemotherapy. Unfortunately, 7 months after the surgery, the patient suffered from right lumbar pain. A positron emission tomography (PET) CT was requested and revealed a well-defined cystic mass measuring 5.2×4.5 cm in the right iliac fossa showing increased tracer uptake ($SUV = 15$). This mass was seen inseparable from the right psoas major muscle, entangling the right ureter leading to right-sided hydronephrosis and abutting the external iliac vessels. The serum creatinine was mildly elevated 1.7 mg/dl (normal range 0.6-1.3 mg/dl), and serum CEA was elevated 7.29 ng/ml (normal range 0-4.7 ng/ml).

A CT-guided core needle biopsy was requested and revealed moderately-differentiated adenocarcinoma focally positive for CK7 and CDX2, while CK20 was non-conclusive suggestive of a local recurrence of previous caecal adenosquamous carcinoma. In light of the patient's

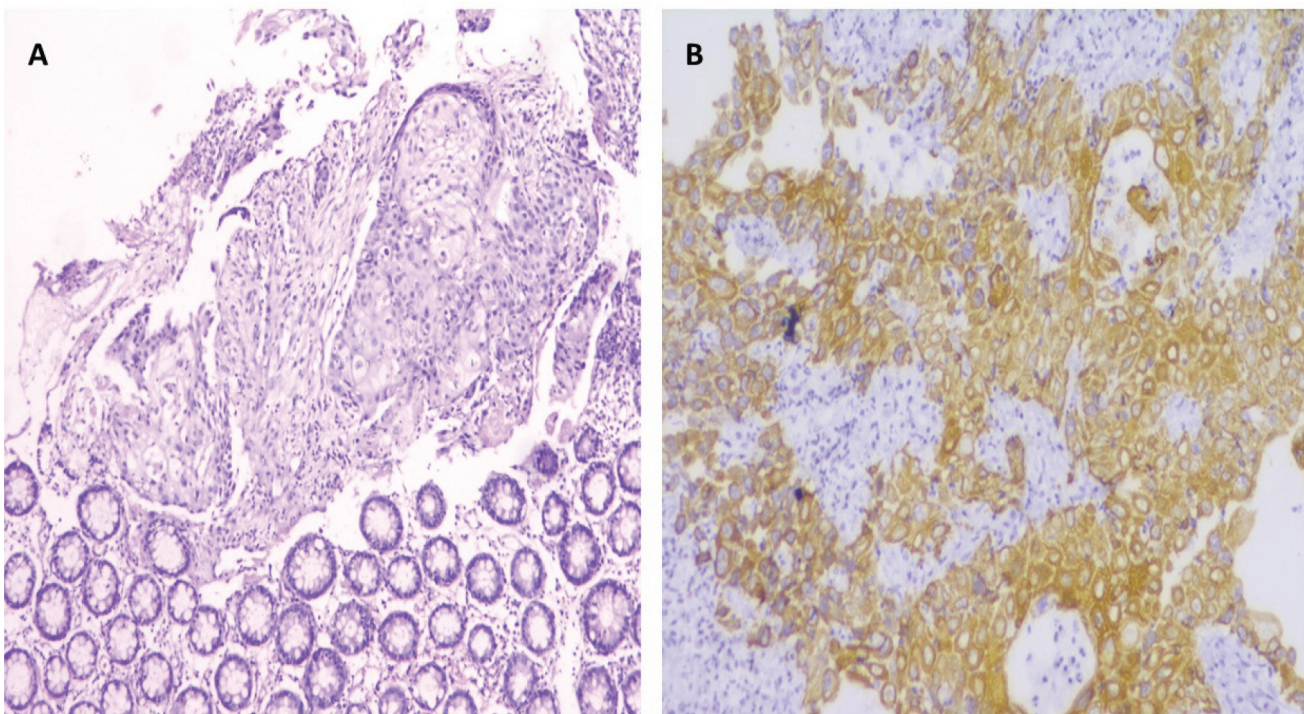


Figure 2. (A): Colonoscopic biopsy: sheets of malignant squamous epithelial cells infiltrating lamina admixed with inflammatory infiltrate. These are lined by malignant pleomorphic squamous cells showing abundant eosinophilic cytoplasm and moderate atypia. Some cells show evident prickling (H & E, $\times 10$). (B) Diffuse cytoplasmic positivity of tumour cells for CK5/6 (H & E, $\times 20$).

locally advanced tumor, fast recurrence, and advanced primary illness, the MDT decided to provide the patient palliative treatment. They also spoke with urologists about inserting a nephrostomy tube for the hydronephrosis and re-evaluating the patient's response. Unfortunately, follow-up on the patient was lost.

Discussion

The majority of colon carcinoma is adenocarcinoma, while adenosquamous carcinoma of the colon is considered exceedingly rare.⁶ This rare entity comprises both adenocarcinoma and squamous cell carcinoma components with an increased tendency of metastasis and hence poorer prognosis.⁷

Though it is customary in >90% of colon cancer cases to express CK20 & CDX2, and stain negative to CK7, it is accepted and reported that colon cancer can be positive for CK7 in 10%-50% of cases according to Tuffaha et al.⁸ This was the case in the second reported patient, where the tumour was CK7+ve.

Colonic adenosquamous carcinoma's patho-

physiology is still poorly understood. In addition to squamous metaplasia as a result of persistent inflammation, squamous differentiation from pluripotent stem cells, and/or malignant squamous transformation from unidentified basal cells were some of the possibilities put forward. Some authors hypothesized a connection between endometriosis, the human papilloma virus, and ulcerative colitis.^{9, 10}

In their study, Nasser et al., reported a female to male predominance in adenosquamous colonic carcinoma, unlike our report of two male patients. This pathology affected the caecum and ascending colon in more than 50% of their study patients which is consistent with the presentation pattern of our two reported patients. Furthermore, they found that 40% of adenosquamous colonic carcinoma patients present with stage IV disease.¹¹

The mainstay of therapy for colonic adenosquamous carcinoma is surgical resection in the form of colectomy and mesenteric lymph node dissection. The recommended chemotherapeutic drug and the function of adjuvant chemotherapy are not yet standardized.⁴ In our

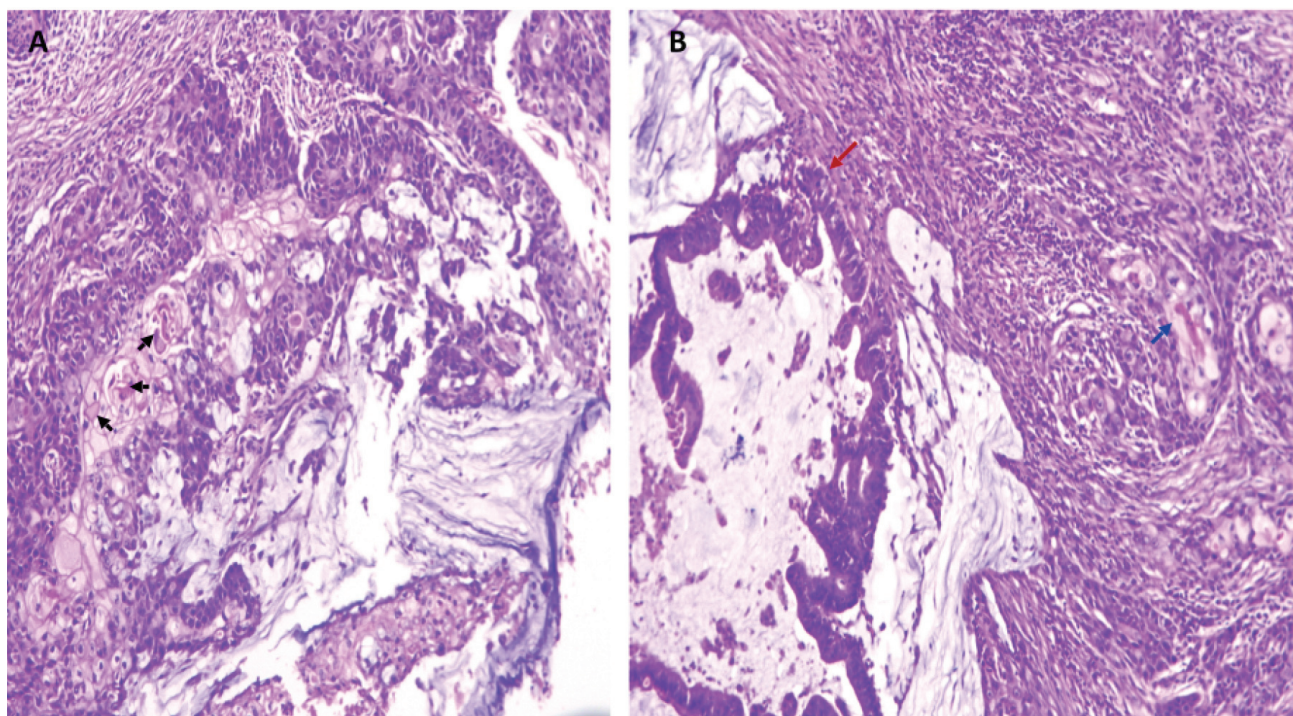


Figure 3. Paraffin section (A) sheets of malignant squamous cells embedded in mucin pools and desmoplastic stroma (H & E, $\times 10$). These are encased by sheets of malignant epithelial cells with minor glandular formation. Arrowhead shows poor keratin pearls. (B) Right; squamous morulas with surrounding desmoplasia, left; adjacent glands lined by malignant epithelial cells embedded in mucin pools (H & E, $\times 10$).

patients, right hemicolectomy with complete mesocolic excision was followed by adjuvant FOLFOX or CAPEOX protocol. Unfortunately, this was not effective, particularly in the second case who developed local recurrence 7 months after his primary surgery.

In their study, Frizelle et al. reported aggressive behaviour and a bad prognosis in colorectal adenosquamous carcinoma patients, especially those who presented with advanced disease stage.¹² The same results were stated by Masoomi et al., who highlighted the impact of advanced disease stage on the increased overall mortality.³ Moreover, Nasser et al. reported a significant increased risk of death among adenosquamous colonic carcinoma patients who presented with adverse features as advanced disease stage, nodal metastasis, and/or lymphovascular tumour emboli.¹¹ Both patients reported here had adverse features like advanced disease stage, nodal metastasis, and/or lymphovascular emboli.

Conclusion

In conclusion, adenosquamous carcinoma is a rare pathological subtype, usually affecting the right colon. Patients commonly present at an advanced disease stage. Surgical resection is the cornerstone of management, since chemotherapy protocols are not standardized yet.

Informed Consent

Informed consent was obtained from all individual participants included in the study.

Conflict of Interest

None declared.

References

1. Bray F, Ferlay J, Soerjomataram I, Siegel RL, Torre LA, Jemal A. Global cancer statistics 2018: GLOBOCAN estimates of incidence and mortality worldwide for 36 cancers in 185 countries. *CA Cancer J Clin.* 2018;68(6):394-424. doi: 10.3322/caac.21492. Erratum in: *CA Cancer J Clin.* 2020;70(4):313.
2. Fleming M, Ravula S, Tatishchev SF, Wang HL. Colorectal carcinoma: Pathologic aspects. *J Gastrointest Oncol.* 2012;3(3):153-73. doi: 10.3978/j.issn.2078-6891.2012.030.
3. Masoomi H, Ziogas A, Lin BS, Barleben A, Mills S, Stamos MJ, et al. Population-based evaluation of adenosquamous carcinoma of the colon and rectum. *Dis Colon Rectum.* 2012;55(5):509-14. doi: 10.1097/DCR.0b013e3182420953.
4. Ishida H, Yamaguchi T, Chiba K, Iijima T, Horiguchi SI. A case report of ascending colon adenosquamous carcinoma with BRAF V600E mutation. *Int Cancer Conf J.* 2017;6(3):93-7. doi: 10.1007/s13691-017-0283-0.
5. Abdalla M, Cornish C, Taboada S, Kothari S, Doshi R, Kothari T, et al. Adenosquamous carcinoma of the cecum: A rare but aggressive form of colonic neoplasia. *Fam Med Med Sci Res.* 2014;3(142):2.
6. Matsuoka H, Nakagawa M, Hanai T, Masumori K, Koide Y, Katsuno H, et al. A case of locally advanced adenosquamous carcinoma of the cecum with long-term survival. *Fujita Med J.* 2019;5(4):107-9. doi: 10.20407/fmj.2019-007.
7. Toumi O, Hamida B, Njima M, Bouchrika A, Ammar H, Daldoul A, et al. Adenosquamous carcinoma of the right colon: A case report and review of the literature. *Int J Surg Case Rep.* 2018;50:119-21. doi: 10.1016/j.ijscr.2018.07.001.
8. Tuffaha MS, Guski H, Kristiansen G. Markers and immunoprofile of tumors of the gastrointestinal tract. In *Immunohistochemistry in tumor diagnostics*: Berlin: Springer; 2018. p. 49-58.
9. Chandra S, Abdalla M, Taboada S, Kaul V. Adenosquamous carcinoma of the cecum: A rare but aggressive form of colonic neoplasia. *Am J Gastroenterol.* 2013;108:S387-S8.
10. Grimes DA, Fowler WC Jr. Adenosquamous carcinoma of the cecum arising in endometriosis. *Gynecol Oncol.* 1980;9(2):254-5. doi: 10.1016/0090-8258(80)90035-9.
11. Nasser Y, Cox B, Shen W, Zhu R, Stettler I, Cohen J, et al. Adenosquamous carcinoma: An aggressive histologic sub-type of colon cancer with poor prognosis. *Am J Surg.* 2021;221(3):649-53. doi: 10.1016/j.amjsurg.2020.07.038.
12. Frizelle FA, Hobday KS, Batts KP, Nelson H. Adenosquamous and squamous carcinoma of the colon and upper rectum: a clinical and histopathologic study. *Dis Colon Rectum.* 2001;44(3):341-6. doi: 10.1007/BF02234730.