

Molar Tissue in Spleen: A Case Report

Maral Mokhtari**, Mojgan Akbarzadeh Jahromi*, Zeinab Amiri*,
Mozhdeh Momtahan**

*Department of Pathology, Shiraz University of Medical Sciences, Shiraz, Iran

**Department of Gynecology and Obstetrics, Shiraz University of Medical Sciences,
Shiraz, Iran

Abstract

An invasive mole is a rare form of gestational trophoblastic disease in which the molar tissue invades into the deep myometrium, cervical stroma, blood vessels or extra-uterine sites. This report is of an invasive mole of spleen that has originated from an ectopic pregnancy, which was primarily thought to be a choriocarcinoma.

Keywords: Spleen, Invasive Mole, Hydatidiform mole

Introduction

Gestational trophoblastic diseases comprise a group of disorders that arise from placental trophoblastic tissue. Based on morphology, cytogenetic and clinical features, they are sub-grouped into hydatidiform mole (complete mole, partial mole, invasive mole), choriocarcinoma, placental site trophoblastic tumor, and miscellaneous trophoblastic lesions.¹⁻³

Microscopically, a hydatidiform mole shows hydropic swelling of placental villi with varying degrees of trophoblastic proliferation. An invasive mole is defined as molar villi that invades into the deep myometrium, cervical stroma, blood vessels or extra-uterine sites.¹

Herein we report a case of ectopic invasive mole that metastasized to the spleen.

Case report

A 31-year-old pregnant lady (gestational age: 7th week) presented with lower abdominal pain and nausea. Her past medical history was unremarkable. She had a normal pregnancy 3 years prior. On physical examination, she had stable vital signs. Other exams were unremarkable except for mild tenderness in the lower abdomen. Her lab data that included hematological, biochemical and liver function tests were within normal limits. Her β HCG titer was greater than 200,000 mIU/ml on two consecutive blood samples. Transvaginal ultrasound showed an enlarged uterus that measured 100×43 mm with an endometrial thickness of approximately 8 mm. No gestational sac was seen in the endometrial cavity. There was a 28

Corresponding Author:

Maral Mokhtari, MD
Pathology Department, Shiraz
University of Medical Sciences,
Zand Street, Shiraz, Iran
Fax: +98-71-32301784
Tel: +98-71-32301784
Email: Maral_mokhtari@yahoo.com

mm simple cyst in the left ovary. The right ovary was unremarkable, other than some irregularity in the right fallopian tube, suspicious for ectopic pregnancy. There was also significant free fluid in the pelvic cavity. An abdominal ultrasound showed a hyperechoic well-defined lesion with non-homogenous echogenicity in the spleen that measured 56×23 mm. All other organs were unremarkable. Abdominal CT scan with contrast confirmed the splenic mass, which was partly cystic and enhanced with contrast (Figure 1).

A chest CT scan was unremarkable. On the second admission day she developed tachycardia accompanied by hypotension. Therefore, with the impression of an ectopic pregnancy, the patient underwent a laparoscopy. The findings were as follows. The uterus was enlarged (compatible with 10 weeks of gestational age). Right adnexa were normal. The left ovary showed a simple cyst and left fallopian tube was unremarkable. There was a significant blood clot in the pelvic cavity. The cyst and a portion of the blood clots were sent for histopathologic examination. The cyst was diagnosed as corpus luteal cyst and the blood clots which were submitted to pathology department were totally embedded, but no placental villi were found. Simultaneously, uterine curettage was performed which showed decidualization without evidence of intrauterine pregnancy. Due to rising β HCG titers and the presence of splenic lesions the possibility of choriocarcinoma was considered. Because of the fear of uncontrolled bleeding, chemotherapy was started without a splenic mass biopsy. The chemotherapy regimen consisted of methotrexate, actinomycin-D and cyclophosphamide. The β HCG titer declined and became negative after 6 cycles of chemotherapy but the splenic mass persisted so the patient was scheduled for splenectomy. There was a solid-cystic lesion in the spleen that measured 4×4×3cm with an area of central necrosis. Histopathologic examination revealed degenerated hydropic placental villi, therefore the diagnosis of invasive mole was made (Figure 2A and B). Her post-operative course was uneventful and the patient had a negative β HCG titer at the 6 month follow-up.

Discussion

An invasive mole is a rare form of gestational trophoblastic disease. It is preceded by complete or partial mole in 75% and 18.5% of cases, respectively. This disorder is defined by molar tissue that invades into the myometrium, cervical stroma, and blood vessels or metastasis to extra-uterine sites. The most common sites of metastasis are the lungs, liver, brain, vagina and vulva.¹⁻³ The main differential diagnosis of invasive mole is choriocarcinoma. Both show persistent, rising β HCG titers, however, in choriocarcinoma no placental villi are seen. An invasive mole shows hydropic placental villi with varying degrees of trophoblastic proliferation.¹ We reported a case of ectopic invasive mole with spleen metastasis. The primary location of the molar pregnancy was not identified. The molar tissue might have arisen from an ectopic pregnancy of the fimbria with subsequent rupture into the pelvic cavity or from an intra-abdominal ectopic pregnancy. No histologic evidence of pregnancy was identified on totally submitted clots; gross examination of the fallopian tubes and ovaries during laparoscopy revealed a corpus luteal cyst.

Chemotherapy is the mainstay of treatment, whether single or multi-agent, based on clinical scoring system. In general, patients with invasive mole have a good prognosis.^{4,5}

In conclusion, invasive mole should be considered in any patients with high, persistent

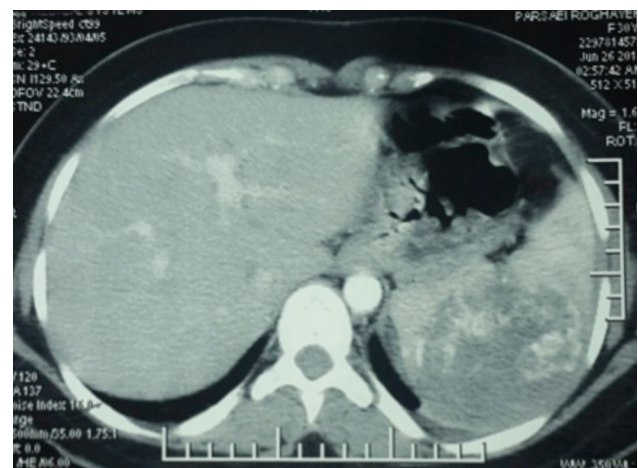


Figure 1. Abdominal CT scan with intravenous contrast shows a solid-cystic mass in the spleen.

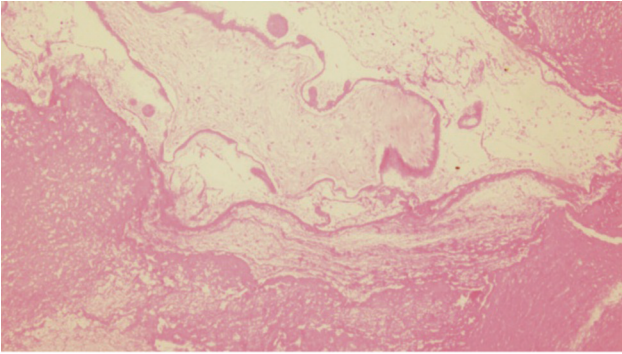


Figure 2A. Histologic sections of the splenic mass showed non-viable degenerated and hydropic placental villi (H&E, 100×).

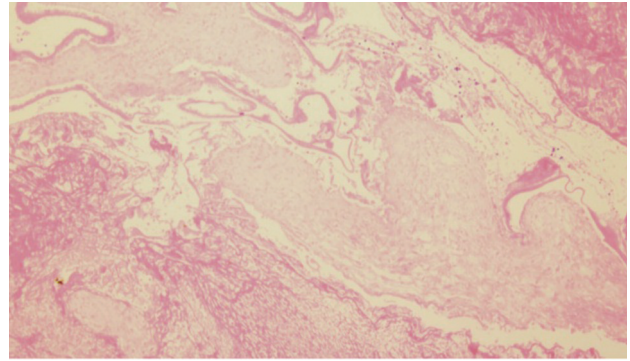


Figure 2B. Histologic sections of the splenic mass showed non-viable degenerated and hydropic placental villi (H&E, 100×).

levels of β HCG, extra-uterine involvement besides choriocarcinoma, and it is better to obtain tissue diagnosis before administration of chemotherapy.

Conflict of Interest

No conflict of interest is declared.

References:

1. Kim, K. Gestational trophoblastic disease. In: Mutter, G; Prat, J, editors. Pathology of the female reproductive tract. 3rd edition, USA: Elsevier; 2014.p.779-800.
2. Chhabra S, Quershi A. Gestational trophoblastic neoplasms with special reference to invasive mole. *Obstet Gynecol India.* 2007; 57(2): 124-7.
3. Froeling FE, Seckl MJ. Gestational trophoblastic tumours: an update for 2014. *Curr Oncol Rep.* 2014;16(11):408.
4. Biscaro A, Braga A, Berkowitz RS. Diagnosis, classification and treatment of gestational trophoblastic neoplasia. *Rev Bras Ginecol Obstet.* 2015;37(1):42-51.
5. May T, Goldstein DP, Berkowitz RS. Current chemotherapeutic management of patients with gestational trophoblastic neoplasia. *Chemother Res Pract.* 2011;2011:806256.