

# Primary Glioblastoma Multiforme with Concurrent Leptomeningeal Metastasis: A Case Report

Kazem Anvari\*, MD, Elham Zarei\*\*\*, MD, Mansoureh Dehghani\*, MD

\*Cancer Research Center, Mashhad University of Medical Sciences, Mashhad, Iran

\*\*\*Student Research Committee, Mashhad University of Medical Sciences, Mashhad

Please cite this article as: Anvari K, Zarei E, Dehghani M. Primary glioblastoma multiforme with concurrent leptomeningeal metastasis: a case report. Middle East J Cancer. 2023;14(2):343-7. doi: 10.30476/mejc.2022.92906.1669.

## Abstract

Brain glioblastoma multiforme with leptomeningeal metastasis is a rare medical condition. Although autopsy series have demonstrated a higher incidence of leptomeningeal metastasis, it is usually a late complication in the course of the disease. The disease progression is almost always rapid, resulting in a poor performance status and short survival. There is no single standard treatment but different individualized choices including chemotherapy (standard, anti-angiogenic, intrathecal, immunotherapy), and radiation have been utilized. In this manuscript, we report a male patient with glioblastoma multiforme of left prefrontal lobe that presented with concomitant cervical leptomeningeal metastasis. Because of poor performance, he received hypofractionated radiotherapy of brain and cervical spine which consisted of a total dose of 45 Gy in 10 fractions with 300c Gy per fraction and 30 Gy local boost to the areas of enhancement. Despite this treatment, there was no response and the patient died three days after the completion of the treatment.

**Keywords:** Glioblastoma, Leptomeningeal carcinomatosis, Hypofractionation, Radiotherapy

## Introduction

Leptomeningeal metastasis is a late event in the clinical course of most malignant tumors that is characterized by the presence of malignant cells in the cerebrospinal fluid (CSF) and different patterns of involvement related to the leptomeninges.<sup>1</sup> Although CSF dissemination has been reported in nearly 20% of supratentorial glioblastoma multiforme (GBM)

cases and 60% of infratentorial cases, autopsy series have shown a higher incidence of spinal involvement of GBM, indicating that some remain clinically asymptomatic, and likely underdiagnosed.<sup>2</sup> Presentation is variable, but patients are usually presented with signs of increased intracranial pressure (ICP) including headache, nausea, vomiting, increased blood pressure, and decreased mental abilities. Primary

### Corresponding Author:

Elham Zarei, MD  
Student Research Committee,  
Mashhad University of Medical  
Sciences, Mashhad, Iran.  
Tel: +98 51 38426936  
Fax: +98 51 38428622  
Email: ZareiE961@mums.ac.ir

GBM with concurrent leptomeningeal metastasis is an extremely rare phenomenon.<sup>3</sup> In this manuscript, we report a male patient with GBM of the left prefrontal lobe that presented with concomitant cervical leptomeningeal metastasis.

### Case Presentation

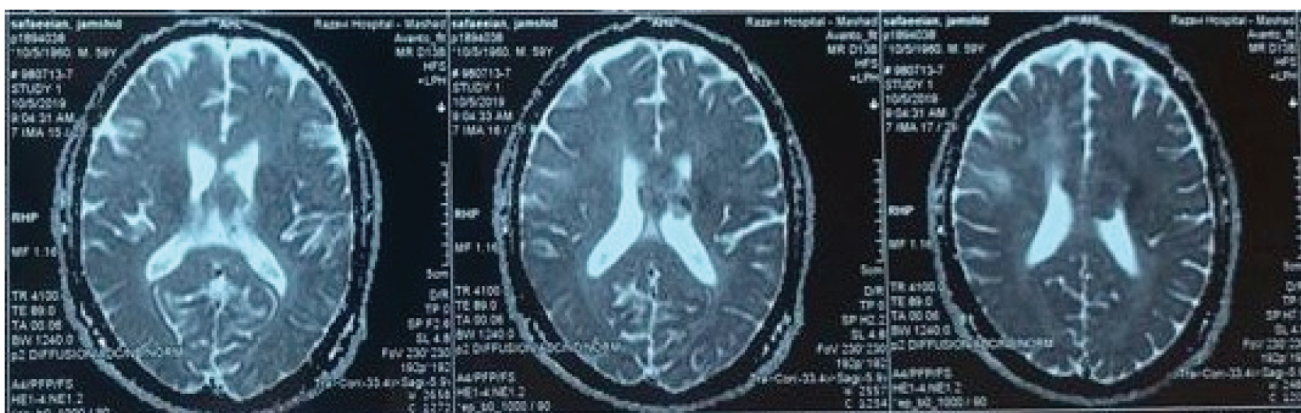A 59-year-old non-smoker male patient with no previous medical history and no family history of cancer referred to the neurology clinic of Qaem Educational Hospital, Mashhad, two years ago because of generalized tonic-clonic seizure. Initial assessments consisted of a normal neurological examination and brain magnetic resonance imaging (MRI) and the patient underwent anticonvulsant therapy with levetiracetam. The seizures were controlled for one year, at which point he experienced focal right lower limb seizures. He had no signs and cranial nerves had a normal function. He was medically investigated once again, which consisted of brain MRI and angiography. MRI demonstrated a high signal region in T2 and fluid attenuated inversion recovery (FLAIR) imaging sequences in biparietal cortex and subcortical white matter with involvement of corpus callosum without restriction and enhancement (Figure 1) (the proposed differential diagnosis was subacute infarction). There was also an intraventricular lesion in the left lateral ventricle with enhancement, suggestive of plexus papilloma or central neurocytoma and or metastasis. Brain MR angiography (MRA) was normal. Close follow-up was then

recommended and the anticonvulsant therapy was changed to carbamazepine.

Following one month, depressive symptoms and mood disorders appeared, and the patient eventually developed progressive right hemiparesis but was still alert and able to carry out daily activities. Physical examinations showed normal cranial nerves function, right hemiparesis, and right equivocal palmoplantar reflex.

The new brain MRI revealed a mass-like lesion in the left lateral ventricle with involvement of the body of corpus callosum and left semi oval centrum. Lesions were iso-signal in T2 and there were high signal portions in T1 in favor of hemorrhage with heterogeneous enhancement after contrast (Figure 2). There existed another signal abnormality in bilateral high parietal zones with ill-defined brief enhancement. High signal T2 in the right parietal with faint enhancement was further detected. High signal mass-like lesions in T2 with heterogeneous enhancement in the suprasellar region and infundibulum were also observed along with two focal enhancements in the right and left cerebellar hemispheres (Figure 3). Spine MRI showed pathological enhancement in the subarachnoid space of the 4<sup>th</sup> ventricle and anterior portion of pons and medulla with extension to the meningeal space of upper cervical cord.

Differential diagnoses primarily considered were sarcoidosis and brain metastasis. Suspected of metastasis, the patient underwent thoracic, abdominal and pelvic computed tomography



**Figure 1.** This figure shows the high signal in biparietal cortex and subcortical white matter with involvement of corpus callosum in T2 sequences.

(CT)-scan, which demonstrated no positive findings. Prostate-specific antigen (PSA) level and tumor markers were normal. For sarcoidosis, angiotensin converting enzyme (ACE) level was normal.

During the investigations, the patient experienced loss of consciousness and was admitted to the hospital and dexamethasone treatment was started. Lumbar puncture was performed, and the CSF cytology was negative. Therefore, the patient underwent stereotactic biopsy from brain lesions and microscopic examination showed atypical glial cell proliferation with high nucleus to cytoplasm ratio and pleomorphism with vascular proliferation and necrosis. Immunohistochemistry was also performed and glial fibrillary acidic protein (GFAP) was strongly positive, while leukocyte common antigen (LCA) and cytokeratins (CK) were negative, all compatible with GBM WHO grade 4.

The patient was referred to the Department of Radiation Oncology and was admitted to the hospital. During the initial assessment, he had no verbal and motor and eye response. CT simulation was performed and 2-dimensional radiotherapy was initiated; after 2 days, when contouring and planning were done, the treatment

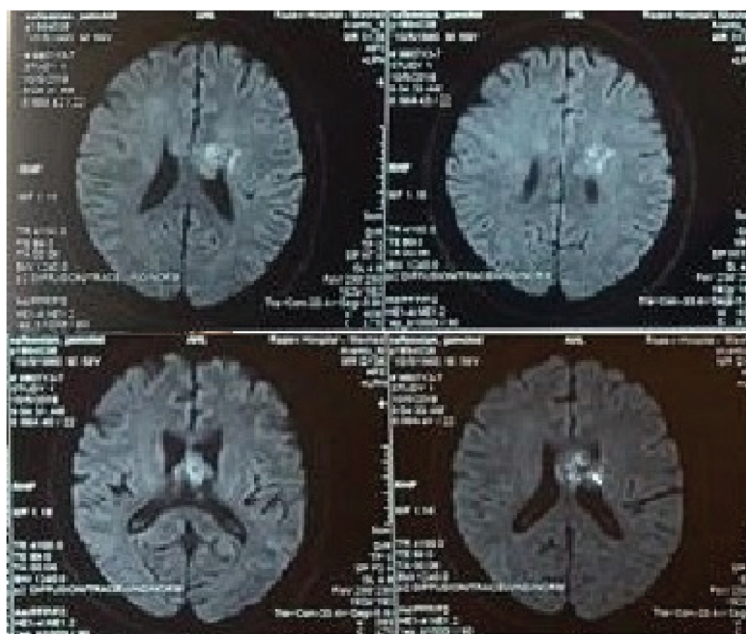
shifted to 3D conformal radiation therapy. Concurrent chemotherapy was not accomplished due to the patients' poor performance. Whole brain radiotherapy was performed with a total dose of 45 Gy in 10 fractions with 300c Gy per fraction and 30 Gy local boost to the areas of enhancement. Patient had no response even at the end of radiotherapy and expired 3 days later.

#### *Ethical considerations*

The manuscript was approved by the Ethics Committee of Mashhad University of Medical Sciences (approval code: IR.MUMS.REC.1401.010).

#### **Discussion**

GBM is the most aggressive category of primary brain tumors amongst adult patients, characterized by a rapid lethal period with an average of approximately 1-year survival after initial diagnosis. It can occur de novo or from a previously low-grade glioma transformation. Low grade lesions mostly present with seizure, unlike the high-grade ones which usually present with headache and behavioral changes.<sup>4</sup> Leptomeningeal metastasis is a seeding of the leptomeninges (the arachnoid and the pia mater) by malignant cells, which is a late complication in solid tumors' course; it is a rare condition in



**Figure 2.** This figure shows the high signal portions of the mass like lesions in T1 in favor of hemorrhage with heterogeneous enhancement after contrast.

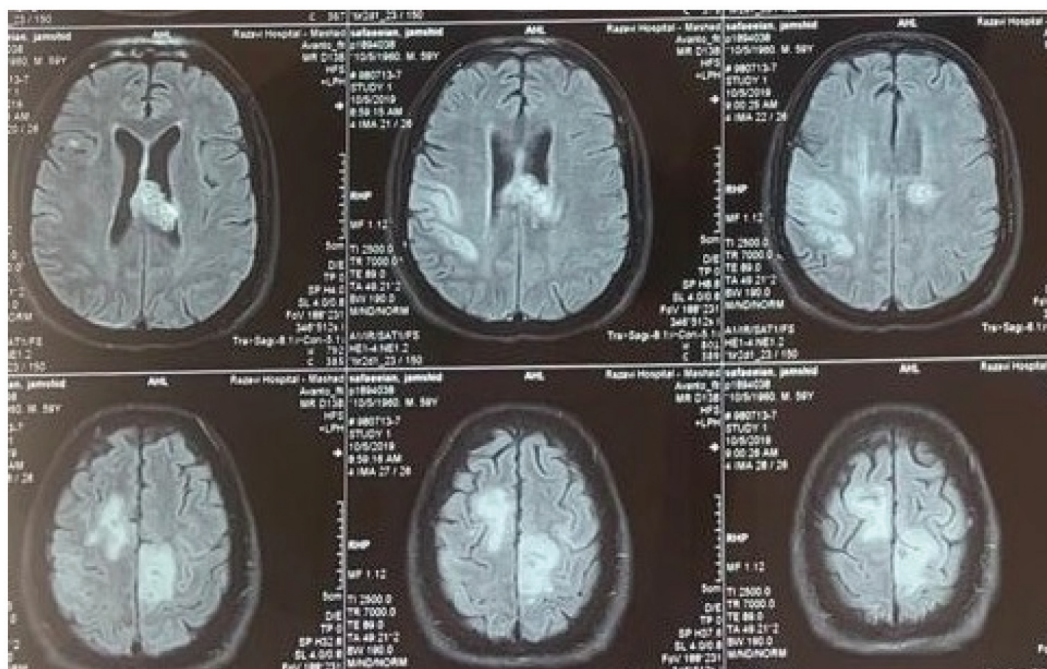
glioblastoma, but has been on the rise over the recent years. It generally faces a dismal prognosis with a median survival of 8-10 weeks.<sup>5</sup> In the present report, we describe a patient who developed a GBM on a seemingly previous low-grade lesion (demonstrating itself by recurrent seizures). The transformation and possibility of glioblastoma was not considered at first, and due to the aggressive nature of the disease, the definitive diagnosis of glioblastoma with leptomeningeal dissemination was made when the patient was clinically deteriorated and had lost consciousness.

At present, the gold standard for diagnosing leptomeningeal carcinomatosis is the detection of malignant cells via cytological examination. However, a positive cytology for malignancy is observable only in 50%-60% of patients, and it depends on multiple preanalytical factors, such as the timing and the processing speed. Cell-free DNA CSF testing is reported to be more sensitive and accurate in comparison with cytologic assessment.<sup>6</sup> With MRI, the existence of FLAIR signal hyperintensity and T1-weighted post-contrast enhancement in the sulci, or the detection of parenchymal involvement can be helpful to the diagnosis when leptomeningeal spread is

clinically suspected.<sup>7</sup>

In a systematic review published this year, Akmal et al. retrieved a total of 18 articles about GBM with leptomeningeal spread. They reported that the overall survival without treatment is 1.6-3.8 months. All the reviewed studies demonstrated that treatment significantly improves overall survival. However, no one particular therapy has been shown to be more efficient over other therapies. Options include chemotherapy (standard, anti-angiogenic, intrathecal, immunotherapy) and radiation.<sup>4</sup>

Radiotherapy has long been an established treatment option. Various methods including whole brain radiotherapy, such as field radiotherapy, focal spinal radiotherapy, or even craniospinal irradiation have been applied on the basis of a careful individualized approach and in different fractionation schedules. Utilization of different radiation techniques including proton beam therapy and stereotactic radiation, along with theco-administration of intrathecal chemotherapy have provided more choices and the role of radiotherapy will likely continue to evolve and advance over time.<sup>8,9</sup> Selection of an approach over another is highly dependent on performance status and the extent of the disease. In the present



**Figure 3.** This figure shows the signal abnormality in bilateral high parietal zone with ill-defined brief enhancement.

patient, low performance status and loss of consciousness limited the primary choice to a whole brain radiotherapy.

A systematic review of radiotherapy for leptomeningeal disease demonstrated that patients treated with a combination of chemotherapy + radiation had significantly higher survival compared with either therapy alone or best supportive care.<sup>10</sup>

As another intervention for increased ICP, CSF diversion can achieve symptom palliation and a safe return to further oncologic therapies, but it should be incorporated judiciously considering the limited prognosis. The following can decrease survival: older age, lower Karnofsky performance status, higher opening pressure, CSF nucleated cell count, and the need for CSF diversion.<sup>11</sup>

## Conclusion

Leptomeningeal metastasis is a rare complication of glioblastoma. There is a lack of evidence and consensus as to a decisive approach. There have been more reports of this condition over the past recent years. Thus, considering this diagnosis and performing more studies is essential, particularly with the emergence of novel agents that may further increase a better survival chance in this morbid state.

## Informed Consent

Informed consent was obtained from the patient's first degree relative to report their case.

## Conflict of Interest

None declared.

## References

- Dehghani M, PeyroShabany B, Shahraini R, Fazilat-Panah D, Hashemi F, Welsh JS, et al. A case report of prostate cancer with leptomeningeal metastasis. *Cancer Rep (Hoboken)*. 2021;e1463. doi: 10.1002/cnr2.1463.
- Yerneni K, Fatemi P, Vogel H, Li G, Zygourakis CC. Leptomeningeal spread with spinal involvement of pineal glioblastoma at initial presentation: A case report. *Interdisciplinary Neurosurgery*. 2020;21:100658.
- Ng WH, Yeo TT, Kaye AH. Spinal and extracranial metastatic dissemination of malignant glioma. *J Clin Neurosci*. 2005;12(4):379-82. doi: 10.1016/j.jocn.2004.11.004.
- Akmal S, Ginalis EE, Patel NV, Aiken R, Dicipinigitis AJ, Hanft SJ. Leptomeningeal disease in glioblastoma: endgame or opportunity? *J Neurooncol*. 2021;155(2):107-15. doi: 10.1007/s11060-021-03864-x.
- Lardinois B, Miller L, Randazzo A, Laurent T, Debois R, Henry S. Leptomeningeal carcinomatosis: A call for optimizing diagnostic sensitivity by the hematology laboratory. *Case Rep Oncol*. 2021;14(2):1248-53. doi: 10.1159/000518314.
- White MD, Klein RH, Shaw B, Kim A, Subramanian M, Mora JL, et al. Detection of leptomeningeal disease using cell-free DNA from cerebrospinal fluid. *JAMA Netw Open*. 2021;4(8):e2120040. doi: 10.1001/jamanetworkopen.2021.20040.
- Debnam JM, Mayer RR, Chi TL, Ketonen L, Weinberg JS, Wei W, et al. Most common sites on MRI of intracranial neoplastic leptomeningeal disease. *J Clin Neurosci*. 2017;45:252-6. doi: 10.1016/j.jocn.2017.07.020.
- Nguyen TK, Myrehaug S, Tseng CL, Husain ZA, Detsky J, Das S, et al. Stereotactic radiotherapy and intracranial leptomeningeal disease. In: Sahgal A, Lo SS, Ma L, Sheehan JP, editors. *Image-Guided Hypofractionated Stereotactic Radiosurgery*. 2<sup>nd</sup> ed. Boca Raton: CRC Press; 2021.p. 451-462.
- Pan Z, Yang G, He H, Cui J, Li W, Yuan T, et al. Intrathecal pemetrexed combined with involved-field radiotherapy as a first-line intra-CSF therapy for leptomeningeal metastases from solid tumors: a phase I/II study. *Ther Adv Med Oncol*. 2020;12:1758835920937953. doi: 10.1177/1758835920937953.
- Buszek SM, Chung C. Radiotherapy in leptomeningeal disease: A systematic review of randomized and non-randomized trials. *Front Oncol*. 2019;9:1224. doi: 10.3389/fonc.2019.01224.
- Bander ED, Yuan M, Reiner AS, Garton ALA, Panageas KS, Brennan CW, et al. Cerebrospinal fluid diversion for leptomeningeal metastasis: palliative, procedural and oncologic outcomes. *J Neurooncol*. 2021;154(3):301-13. doi: 10.1007/s11060-021-03827-2.