

Estrogen and Progesterone Receptor Expression in Endometrioid Endometrial Carcinomas: A Clinicopathological Study

Indu Maniketh*, Gayatri Ravikumar**†, Julian A. Crasta*, Rekha Prabhu**, Elizabeth Vallikad**

*Department of Pathology, St. John's Medical College, Koramangala, Bangalore, India

**Department of Gynecologic Oncology, St. John's Medical College, Koramangala, Bangalore, India

Abstract

Background: This study assesses the expressions of estrogen and progesterone receptors in endometrioid carcinomas of the endometrium and their association with established clinicopathological prognostic parameters.

Methods: We reviewed the pathology and medical records from 45 cases of endometrioid endometrial carcinomas that were seen from 2006 to 2011 for relevant clinical and histological parameters. Grade I and stage IA tumors were analyzed and compared with higher grades and stages IB- IV. Estrogen and progesterone immunostained slides were analyzed.

Results: Patients' age ranged from 32 to 77 years (mean: 58.13 years). Postmenopausal bleeding was the most common presenting complaint seen in 75.6% of cases. Associated co-morbidities such as diabetes, hypertension and other malignancies were seen in 88% of cases. Myometrial invasion of less than 50% of myometrial thickness was seen in 70.5% cases. There were 40% of tumors classified as FIGO grade 1 and 65.85% were FIGO stage IA. Estrogen and progesterone expressions were seen in 40 (90%) cases, predominantly in FIGO stage I disease. However there was no statistically significant association of estrogen and progesterone expression with any of the clinicopathological prognostic factors. In 23 of the 30 cases that had follow up data, there was no evidence of disease. Of these, only one case was negative for both hormone receptors. Progesterone positivity alone was seen in 87% of cases with no evidence of disease.

Conclusions: Nuclear immunostaining with estrogen and progesterone was seen in the majority of cases (90%). Although we have observed a linear increase in progesterone receptor positivity with disease-free survival, this finding needs to be confirmed with additional, larger studies.

Keywords: Endometrial carcinoma, Hormone receptors, Prognostic factors, Survival

†Corresponding Author:

Gayatri Ravikumar, MD
Department of Pathology,
St. John's Medical College,
Bangalore, India
Tel: +91-80-26065053
Email: gayatri.ravikumar@gmail.com

Introduction

Endometrial carcinoma is the third most common malignancy among women in Southeast Asia.¹ Conventionally, endometrial carcinomas are divided into two types: endometrioid and serous variants. Prognosis depends on several uterine and extra-uterine factors that include various molecular markers. The steroid hormones, estrogen and progesterone, play a significant role in the pathogenesis of endometrial carcinoma, particularly the endometrioid variant. Estrogenic action unopposed by progesterone induces sequential malignant changes in the endometrium by atypical hyperplasia changes.² Decreased expressions of estrogen receptor (ER) and progesterone receptor (PR) are observed in invasive tumors with increase in both grade and stage compared to atypical hyperplasia.³ Therefore absence of ER and PR expression may be important in the progression of endometrial carcinogenesis.⁴ However their roles in the progression and behavior of the tumor are not well defined.

Numerous studies have correlated ER and PR expression to histopathological prognostic parameters such as menopausal status, grade, stage, lymphovascular invasion, and myometrial invasion.⁵ However studies that relate hormonal

receptor status with survival have yielded varied results. A few studies have shown a positive association between hormone receptor expression whereas others fail to demonstrate an association.^{6,7} The present study aims to determine the correlation between ER and PR expression to the various clinicopathological prognostic parameters such as survival in patients with endometrioid adenocarcinoma in a Southern Indian population.

Materials and Methods

From 2006 to 2011, a total of 45 non-consecutive cases of endometrioid adenocarcinoma were retrieved from the archives of the Department of Pathology, St. John's Medical College along with their medical records from St. John's Medical College Hospital. The clinical data collected included age; presenting complaints; menopausal status (pre- or postmenopausal); comorbid conditions such as diabetes, hypertension and other malignancies; diabetes, hypertension and malignancies with special reference to gynecological malignancy; and endometrial thickness on ultrasound examination. Histopathological parameters analyzed included the International Federation of Gynecology and Obstetrics (FIGO) grade that includes nuclear

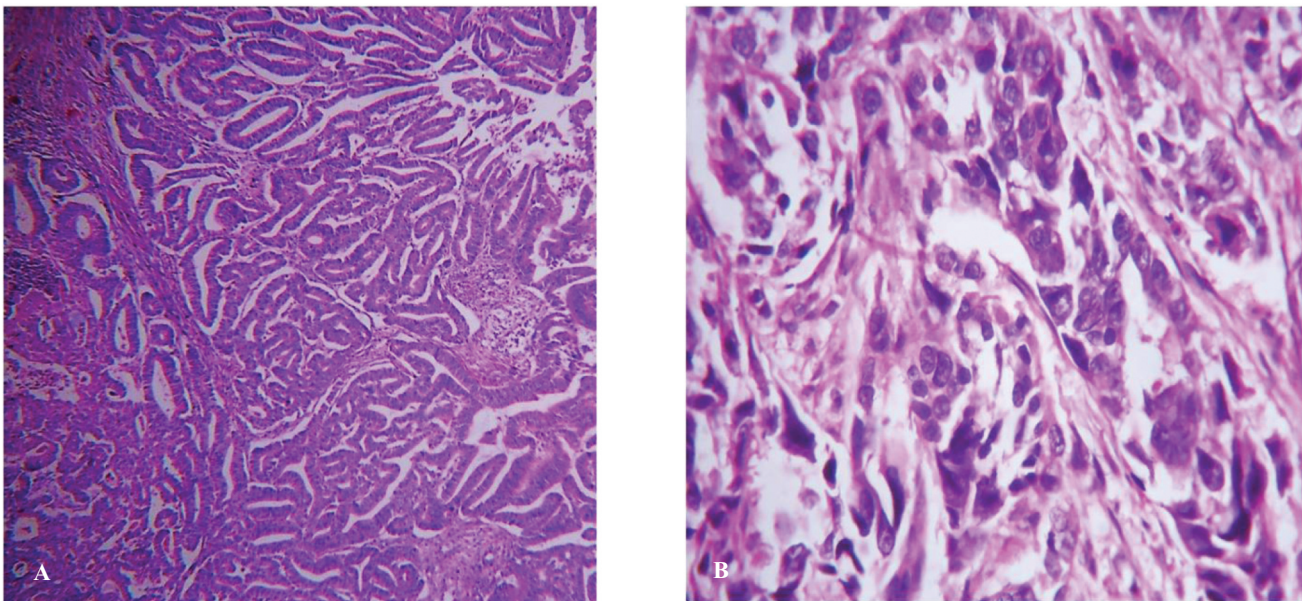


Figure 1. A. H&E stain of well-differentiated FIGO grade 1 endometrioid adenocarcinoma with back-to-back arranged glands lined by columnar cells with relatively uniform nuclei. (Original magnification, 200x) B. H&E stain showing loss of glandular differentiation with nest of cells and bizarre nuclear atypia, FIGO grade 3. (Original magnification, 400x).

Table 1. Estrogen receptor (ER) and progesterone receptor (PR) scoring.

ER and PR	Score	Stained cells	Category (score=P+I)
Proportion (P)	1	0-25%	Category 1: Scores 1 and 2 Category 2: Scores 3 and 4 Category 3: Scores 5 and 6
	2	26%-75%	
	3	>75%	
Intensity (I)	1	Absent-to-weak staining	
	2	Strong staining	
	3	Very strong staining	

A combined score of more than 2 (categories 2 and 3) was considered immunopositive.

and architectural features, depth of myometrial invasion (<50% thickness of the myometrium and >50% thickness of the myometrium), cervical and adnexal involvement, lymphovascular invasion, lymph node metastasis and FIGO stage. Grade I and stage IA tumors were analyzed and compared with higher grade and other stages (i.e., stages IB-IV). Categorization of cases into these two groups was based on the difference in clinical management and prognosis.⁸

We obtained the immunohistochemical (IHC) stained slides for ER and PR from all cases. Immunohistochemical staining was performed using a polymer technique on tissue sections of 4-5 micron thickness, floated on sialinized slides and incubated overnight at 60°C. The slides were deparaffinized with xylene, rehydrated with ethanol and then placed in a hydrogen peroxide solution. Antigen retrieval was done by steam treatment in a tris EDTA buffer. The slides were coated and incubated at room temperature for 30 minutes with primary monoclonal antibodies for ER (SP1) and PR (PR88), which were obtained from BioGenex, San Ramon, CA, USA. Subsequently, the slides were incubated with secondary antibody. Reactivity was detected using DAB as the chromogen and slides were counterstained with Harris' hematoxylin. The slides were interpreted independently by two pathologists blinded to the clinical data. In case of discordant interpretation the slides were analyzed under a multi-headed microscope and consensus obtained. Evaluation of ER and PR status was performed according to the method described by Carcangiu et al. (Table 1).⁵ The results were correlated with clinicopathological

parameters and patients' survival. The correlation between hormone receptor expression and clinicopathological variables was performed by calculating Pearson's correlation coefficient using SPSS for Windows software (version 16, SPSS Inc., Chicago, IL, USA).

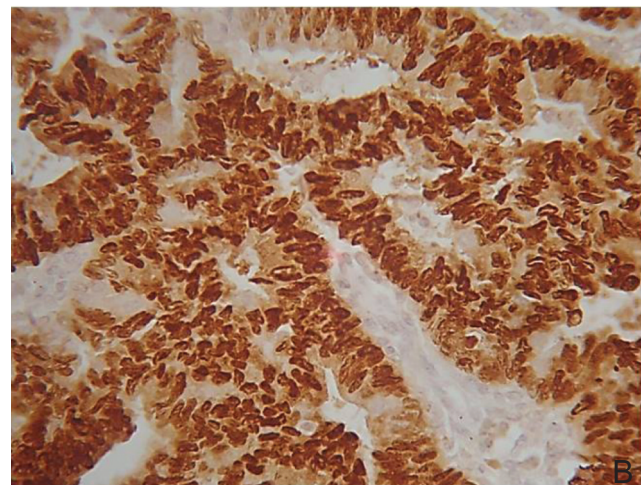
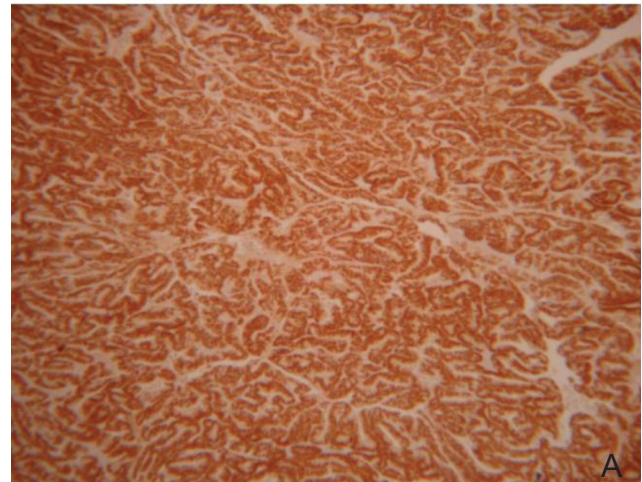


Figure 2. Immunohistochemistry (IHC) showing: A. Nuclear positivity for estrogen receptor (ER) (Original magnification, 200x), B. progesterone receptor (PR) (Original magnification, 400x).

Results

Patients' age ranged from 32 to 79 years with a mean of 58.13 years. The majority (86.6%) were postmenopausal. Of these, 75.56% presented with postmenopausal bleeding; perimenopausal patients presented with menstrual abnormalities and vaginal discharge. Associated co-morbid conditions were seen in 87.9% of patients with diabetes mellitus being the most common (44.2%). A family history of co-morbid conditions such as diabetes, hypertension and malignancy was noted in 58% of patients. Data on pelvic ultrasonological evaluation was available in 26 patients who were postmenopausal. Thickened endometrium, defined as an endometrial thickness >5 mm was a significant finding in 24 patients.

On histopathology, 70.5% of the patients had <50% myometrial invasion. Early stage disease (FIGO stage IA) was seen in 65.85% of cases. There were 18 patients with grade 1 histology and 27 had higher grade histology (Figure 1A and 1B). Hormone receptor positivity as either ER or PR, or both was seen in 90% of cases (Figure 2A and 2 B). However, only 68.9% of cases were positive for both receptors. Table 2 summarizes the clinical, histological and immunohistochemical findings of cases.

We compared and correlated the hormone receptor expressions to the various clinical and pathological prognostic parameters. Of patients who were hormone receptor positive, 39 were postmenopausal from which 27 were both ER and PR positive. There were 7 cases that were either ER or PR positive and 5 cases were hormone receptor negative. Most patients were positive for ER, PR, or both, irrespective of the grade, myometrial invasion and disease stage. Hence the association between receptor expression and histopathological features was not statistically significant. The distribution of the cases with respect to histopathological features and receptor expression is summarized in Table 3. Follow up information was available for 28 cases and the follow up period ranged from 3 to 72 months (mean: 21.54 months). There were 23 (77%) cases alive with no evidence of disease and 2 cases had

recurrence. One case expired due to the disease, another death was attributed to chemotherapy complications and another case expired of natural causes. Among the 23 patients who were disease-free, 17 (73.91%) were ER positive and 20 (86.96%) were PR positive. Of the 17 patients who showed ER positivity, 15 were positive for both ER and PR, whereas 2 were only ER positive. Of the 20 patients who were positive for PR, 15 were positive for both ER and PR and 5 were only PR positive. One patient amongst the 23 cases was negative for both ER and PR. Among the two patients who recurred, one was hormone receptor negative and the other was ER and PR positive. Of the 2 patients who died due to chemotherapy complications and natural causes, both were ER and PR positive. The patient who died due to disease was ER and PR negative. We observed a positive relationship between PR positivity and disease-free survival, however it was not statistically significant ($P=0.072$).

Discussion

Endometrial carcinoma is one of the most common malignant tumors of the female genital tract.^{1,3,7} Definite histopathological parameters that define prognostic value include depth of myometrial invasion, lymphovascular involvement, FIGO grade and stage. The disease is usually detected at an earlier stage and this is probably due to the fact that it most often presents with postmenopausal bleeding for which gynecologic consultation is usually sought.⁹ In the current study, the majority of patients were postmenopausal and presented with postmenopausal bleeding. Additionally, estrogen driven endometrioid carcinomas have a slow, sequential growth process unlike the p53 driven serous papillary carcinomas which thereby provides some lead time for disease detection.¹⁰ A variety of co-morbid conditions are implicated in the pathogenesis of endometrioid carcinomas, including diabetes mellitus, obesity, hypertension and other organ malignancies.¹¹ Diabetes and obesity are known to increase the risk of developing endometrioid carcinomas, possibly

Table 2. Clinical, histological and immunohistochemistry (IHC) data.

Clinical data summary		
Age (mean: 58.13 yrs.)	Postmenopausal	86.6%
	Premenopausal	13.3%
Presenting complaints	Postmenopausal bleeding	75.6%
	Abnormal uterine bleeding	11.1%
	Vaginal discharge	13.3%
Co-morbid conditions	Diabetes	44.2%
	Hypertension	32.6%
	Other malignancies	11.1%
Family history	Diabetes	30.2%
	Hypertension	18.6%
	Malignancy	9.3%
Endometrial thickness	Thickened endometrium (>5mm thickness)	20/24 (all postmenopausal)
Histopathological data summary		
Myometrial invasion	<50%	70.5%
	>50%	29.5%
FIGO grade	I	40%
	II and III	60%
FIGO stage	I A	65.85%
	IB+II + III +IV	34.15%
IHC data summary		
Estrogen receptor (ER) positive	73.3%	
Progesterone receptor (PR) positive	84.4%	
ER and PR positive	68.9%	
ER and PR negative	11.1%	
ER positive PR negative	4.4%	
ER negative and PR positive	15.6%	

through adiponectin and its receptor.¹² We have observed that 44.2% of patients with endometrioid carcinoma had diabetes mellitus as an associated comorbid condition which supported literature reports.

On ultrasonographic examination, endometrial carcinoma is known to have a significant increase in the thickness of the endometrium, especially in postmenopausal women.¹³ In our study we have observed that 83.3% of postmenopausal women had significantly thickened endometrium as visualized by ultrasonography. This result was comparable to a study conducted by Breijer et al.¹³

Endometrioid carcinomas, as with breast carcinomas, are known to express hormone receptors. Although its therapeutic implications are not clearly known in the endometrium, the prognostic implication is a matter of current interest.⁶ The role of adjuvant therapy in

endometrial carcinomas is limited to radiation therapy while hormonal ablation is intended for advanced or recurrent disease. In addition, the tumor response to hormone therapy depends on the tumor differentiation.⁷ Literature review has shown that hormone receptors are positive in 35%-90% of endometrial carcinomas^{4,14} and the absence of these receptors might indicate advanced disease.¹⁰ In our study, there were 73.3% ER positive cases, 84.4% PR positive cases and 68.9% of cases had combined ER and PR positivity, which supported results stated in the literature. The majority of grade 1 and stage 1A tumors showed positive expression of the hormone receptors. The associations of hormone receptor status with the other known clinicopathological prognostic factors were contradictory in the literature. Previous studies have failed to show a direct relationship between hormone receptor expression

Table 3. Clinicopathological parameters and their correlation with estrogen receptor (ER) and progesterone receptor (PR) expression.

	ER+ (ER-)	PR+ (PR-)	ER+ PR+	P value	ER or PR+	P value	ER& PR-	P value
Grade(n=45)								
Grade I(18)	13(5)	14(4)	12		3		3	
Grade II + III(27)	20(7)	24(3)	19	0.792	6	0.939	3	0.628
Stage(n=41)								
Stage IA(27)	19(8)	21(6)	17		6		4	
Stage>1A(14)	10(4)	13(1)	10	0.845	3	0.953	1	0.834
Myometrial invasion(n=44)								
<50%(31)	22(9)	26(5)	21		6		4	
>50%(13)	10(3)	11(2)	9	0.922	3	0.780	1	0.619
Lymphovascular emboli(n=22)								
Present(6)	5(1)	6(0)	5		1		0	
Absent(16)	9(7)	13(3)	9	0.497	4	0.677	3	0.657

to tumor grade and stage,¹⁵ which was similar to our study. Others have disputed the importance of immune expression of these receptors. Hormone receptors can be evaluated by biochemical and immunohistochemical methods although most studies have resorted to immunohistochemistry as it is more widely available, feasible and reliable. However the protein detected by immunohistochemical methods may not exactly identify a fully functioning hormone receptor and therefore the importance of immune expression of these receptors has been disputed.¹⁶ A few studies have demonstrated a statistically significant correlation between positive receptor status and early well differentiated tumors. In the present study, our data was skewed with an unequal distribution of cases in the prognostically varied groups and did not yield statistically significant results. Hormone receptor expression, especially PR expression is known to be associated with better survival in patients with endometrial carcinoma.⁷ In this study 86.96% of patients who were PR positive had disease-free survival which was in concordance with other studies that showed a positive association between PR expression and disease-free survival.⁷

In summary, endometrioid carcinomas are usually detected early due to their symptomatic

presentation. Therefore a significant number are low grade and early stage disease. Most develop in the background of a hyperestrogenic state and are ER and PR positive. Although hormone receptor status did not yield a statistically significant association with other clinicopathological parameters in this study (due to discontinuous distribution of cases with respect to grade and stage), PR expression did show a linear increase association with disease-free survival, which was significant. The present study has reinforced the fact that hormone receptor expression should be studied in endometrioid carcinomas as they have prognostic implications. Receptor negative patients need regular follow up visits, which will aid in earlier detection of recurrence and metastasis.

Conflict of Interest:

No conflict of interest is declared.

References:

1. Kim JW, Kim SH, Kim YT, Kim DK. Clinicopathologic and biological parameters predicting the prognosis in endometrial cancer. *Yonsei Med J.* 2002; 43(6):769-78.
2. Pozharisskii KM, Samsonova EA, Ten VP, Maksimova NA, Urmancheeva AF. Immunohistochemical profile of endometrioid adenocarcinoma of the uterus: ER, PR, HER-2, Ki-67 and their prognostic value. *Arkh Patol.*

- 2005; 67(2):13-7.
3. Shabani N, Kuhn C, Kunze S, Schulze S, Mayr D, Dian D, et al. Prognostic significance of oestrogen receptor alpha (ERalpha) and beta (ERbeta), progesterone receptor A (PR-A) and B (PR-B) in endometrial carcinomas. *Eur J Cancer*. 2007;43(16):2434-44.
 4. Stoian SC, Simionescu C, Mărgăritescu , Stepan A, Nurciu M. Endometrial carcinomas: correlation between ER, PR, Ki67 status and histopathological prognostic parameters. *Rom J Morphol Embryol*. 2011; 52(2):631-6.
 5. Carcangiu ML, Chambers JT, Voynick IM, Pirro M, Schwartz PE. Immunohistochemical evaluation of estrogen and progesterone receptor content in 183 patients with endometrial carcinoma. Part I: Clinical and histologic correlations. *Am J Clin Pathol*. 1990; 94(3):247-54.
 6. Fukuda K, Mori M, Uchiyama M, Iwai K, Iwasaka T, Sugimori H. Prognostic significance of progesterone receptor immunohistochemistry in endometrial carcinoma. *Gynecol Oncol*. 1998; 69(3):220-5.
 7. Srijaipracharoen S, Tangjitgamol S, Tanvanich S, Manusirivithaya S, Khunnarong J, Thavaramara T, et al. Expression of ER, PR, and Her-2/neu in Endometrial Cancer: A Clinicopathological Study. *Asian Pac J Cancer Prev*. 2010; 11(1): 215-20.
 8. National comprehensive cancer network, complier. NCCN clinical practice guidelines in oncology.(NCCN guidelines): Uterine neoplasms[bibliography]. Washington: NCCN; 2014. Available from: <http://www.tri-kobe.org/nccn/guideline/gynecological/english/uterine.pdf>.
 9. Kebaili S, Dhouib M, Chaabane K, Chtioui A, Amouri H, Ben Ayed B, et al. Exploration of post-menopausal uterine bleeding Hysteroscopy-histology correlation in 94 cases. *Santé*. 2010;20(2):99-104.
 10. Kounelis S, Kapranos N, Kouri E, Coppola D, Papadaki H, Jones MW. Immunohistochemical Profile of Endometrial Adenocarcinoma: A Study of 61 Cases and Review of the Literature. *Mod Pathol*. 2000; 13(4):379-88.
 11. Williams GP. The role of oestrogen in the pathogenesis of obesity, type 2 diabetes, breast cancer and prostate disease. *Euro J Cancer Prev*. 2010; 19(4): 256–71.
 12. Moon HS, Chamberland JP, Aronis K, Tseleni-Balafouta S, Mantzoros CS. Direct role of adiponectin and adiponectin receptors in endometrial cancer: in vitro and ex vivo studies in humans. *Mol Cancer Ther*. 2011; 10(12):2234-43.
 13. Breijer MC, Peeters JA, Opmeer BC, Justin Clark T, Verhejen RH, Mol BW, et al. The capacity of endometrial thickness measurement in the diagnosis of endometrial carcinoma in asymptomatic postmenopausal women. A systematic review and meta analysis. *Ultrasound Obstet Gynecol*. 2012;40(6): 621-9.
 14. Nyholm NCJ, Nielsen AL, Lynrup J, Norup P, Thorpe SM. Biochemical and immunohistochemical estrogen and progesterone receptors in adenomatous hyperplasia and endometrial carcinoma: correlation with stage and other clinicopathologic features. *Am J Obstet Gynecol*. 1992; 167(5):1334-42.
 15. Fanning J, Brown S, Phibbs G, Kramer T, Zaher A. Immunohistochemical evaluation is not prognostic for recurrence in fully staged high-risk endometrial cancer. *Int J Gynecol Cancer*. 2002; 12(3):286-9.
 16. Singh M, Zaino RJ, Filiaci VJ, Leslie KK. Relationship of estrogen and progesterone receptors to clinical outcome in metastatic endometrial carcinoma: Gynecologic Oncology Group Study. *Gynecol Oncol*. 2007; 106(2):325-33.