

Surgical Management of Giant Cervico-Axillo-Thoracic Cystic Hygroma: A Case Report

Saleh Al-wageeh*, MD, Faisal Ahmed***, MD, Khalil Al-naggar**, MD, Mohammad Reza Askarpour***, MD, Fayed Al-yousofy****, MD

*Department of General Surgery, Ibb University of Medical Sciences, Ibb, Yemen

**Urology Research Center, Al-Thora General Hospital, Department of Urology, Ibb University of Medical Sciences, Ibb, Yemen

***Department of Urology, Shiraz University of Medical Sciences, Shiraz, Iran

****Department of Pathology, Faculty of Medicine, Taiz University of Medical Sciences, Taiz, Yemen

Please cite this article as: Al-wageeh S, Ahmed F, Al-naggar K, Askarpour, MR, Al-yousofy FA. Surgical management of giant cervico-axillo-thoracic cystic hygroma: a case report. Middle East J Cancer. 2022;13(2):377-82. doi: 10.30476/mejc.2021.87027.1388.

Abstract

Cystic hygroma (CH) is a congenital malformation of the lymphatic system commonly treated with surgical excision. The typical locations of this lesion are the cervico-facial and cervicothoracic region and other rare locations include axilla, mediastinum, and limbs. CH usually presents at birth as a painless mass, which concerns parents. It might also be detected as complications resulting from it, such as respiratory distress fever, a sudden increase in the size, feeding difficulty, and infection. To the best of our knowledge, there are a few cases reported in cervico-axillo-thoracic variants and we reported giant cervico-axillo-thoracic cystic hygroma, which is thoroughly treated with surgical excision.

A 45-days female, full-term delivery, infant presented with big right-side trunk mass, diagnosed through computed tomography scan as a CH involving the right lateral and posterior chest wall with extension to the axilla and right side of the neck, which was managed with surgical excision. After a 6-month of follow-up, no recurrent lesion masses were detected.

CH is a congenital malformation of the lymphatic system that can be treated in the pediatric population. The treatment option depends on size, age, and location of the lesion. In our case, complete surgical excision was the selective treatment for this lesion.

Keywords: Cystic hygroma, Case report, Surgical excision, Axilla, Cervical, Thoracic

Corresponding Author:

Faisal Ahmed, MD
Urology Research Center, Al-Thora General Hospital,
Department of Urology, Ibb University of Medical Sciences,
Ibb, Yemen
Tel/Fax: +9674407128
Email: fmaaa2006@yahoo.com

Introduction

Cystic hygroma (CH) is a congenital malformation of the lymphatic system and the most common type of lymphangioma. It may be a uniloculated or multiloculated lesion or it may have scared communication with other normal lymphatic channels.¹ The pathophysiology of CH is believed to originate from the sequestration of lymphatic tissue from lymphatic sacs in the time of lymphatic-venous sacs development. Fail in communication between sequestered tissues and the remainder of the lymphatic or two venous systems. Dilatation of the sequestered lymphatic tissues leads to cystic morphology of these lesions.² About 1 out of 4000 live births have cystic hygroma and 90% are diagnosed before reaching two years old.³ The typical locations of CH are cervico-facial regions, then axilla, mediastinum, groin, and below the tongue.⁴ CH usually presents at birth as a painless mass, which concerns parents. It might also be detected as complications resulting from it, such as respiratory distress, motion limitation, fever, a sudden increase in the size, feeding difficulty, and infection.^{2, 3} We reported a case of giant cervico-axillo-thoracic CH, giving us the possibility to evaluate the diagnosis and treatment of such lesions critically.

Case Presentation

A 45-day female infant born from a 26 y/o mother, gravid 4, Para 2, abortion 2, living in a rural area, with poor socio-economic status and no prenatal follow-up was our case. She did not use folic acid during her pregnancy and is non-smoker and non-drinker. The patient was brought to the hospital by the parents on the first day after normal vaginal delivery with big right-side painless trunk mass. She was admitted and visited by a pediatrician on June 11, 2019.

Clinical findings

On physical examination, she was completely healthy, with normal crying and normal cardiovascular examination. Lungs were clear and reflexes and limb movements were normal. Apgar index was 10 at 5 min. Her weight was 3500 gr and the length was 47 cm. The right nipple was dragged to the lateral side due to the

mass effect. The mass was about 10 × 12 cm in diameter, bosselated surface, soft in consistency, transilluminate, fluctuating, and had cross fluctuation to the posterior triangle of the neck. The mass was not pulsatile; no tenderness or skin color changes was seen (Figure 1).

Diagnostic assessment

The cervico thoracic computed tomography (CT) scan with contrast revealed a lobulated cystic lesion measured about 10.7 × 9.8 × 9.2 cm with poor enhancement after intravenous contrast injection involving the right lateral and posterior chest wall with extension to the axilla and right side of the neck in the C1 (cervical vertebra) level without right-side major vessels adhesion. No involvements of NV system were observed. The lung parenchyma and chest cage were normal in the CT scan (Figure 2). Abdominal ultrasonography showed that the liver, pancreas, kidneys, and spleen were normal and surgical excision was planned for the patient.

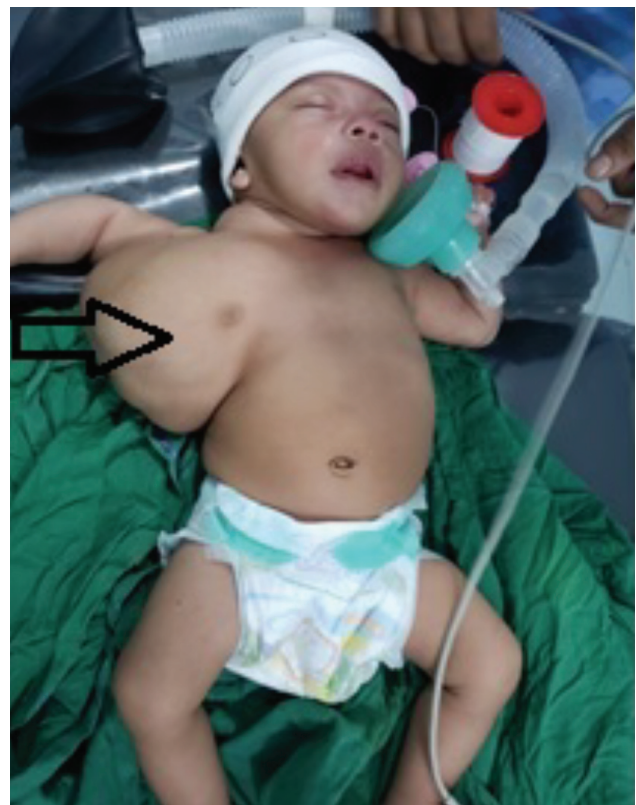

Figure 1. This figure represents the macroscopic view of the lesion of cystic hygromas involving the whole right side of the trunk, the right axillary area, and right side of the neck.

Therapeutic intervention

After preparation and drape under general anesthesia, in supine position, a curved skin incision on the right lateral chest wall was made and the skin was opened. Subcutaneous tissue and the muscles of lateral chest wall, including pectoralis, serratus anterior, and latissimus dorsi muscles, were dissected. Afterwards, the cyst was separated from the surrounding tissue and the major axillary vessels. The ellipse incised toward the axilla and the cyst was dissected from the neck and excised completely from its attachment to the branches of axillary and subclavian veins (Figure 3 A and B). The specimen consisted of a well-circumscribed, ovoid, tan-brown, cystic, soft tissue mass. These cysts produce a milky, serous,

and turbid. Following hemostasis, the vacuum Jackson-Pratt (JP) drain was inserted and primary closure of the wound with nylon 3/0 was performed. The patient was transferred to ICU with good condition. After three days, the patient was discharged with oral antibiotic. No complications were reported. After 48 hours, the drain was nearly nil and it was then removed. The sutures were removed on the 10th postoperative day.

Histological examination demonstrated large irregular vascular spaces mostly denuded and partially lined by flattened and bland endothelial cells with fibroblastic or collagenous stroma. The stroma showed cystic lymphangioma with dilated communicating lymphatic vessels and cystic areas

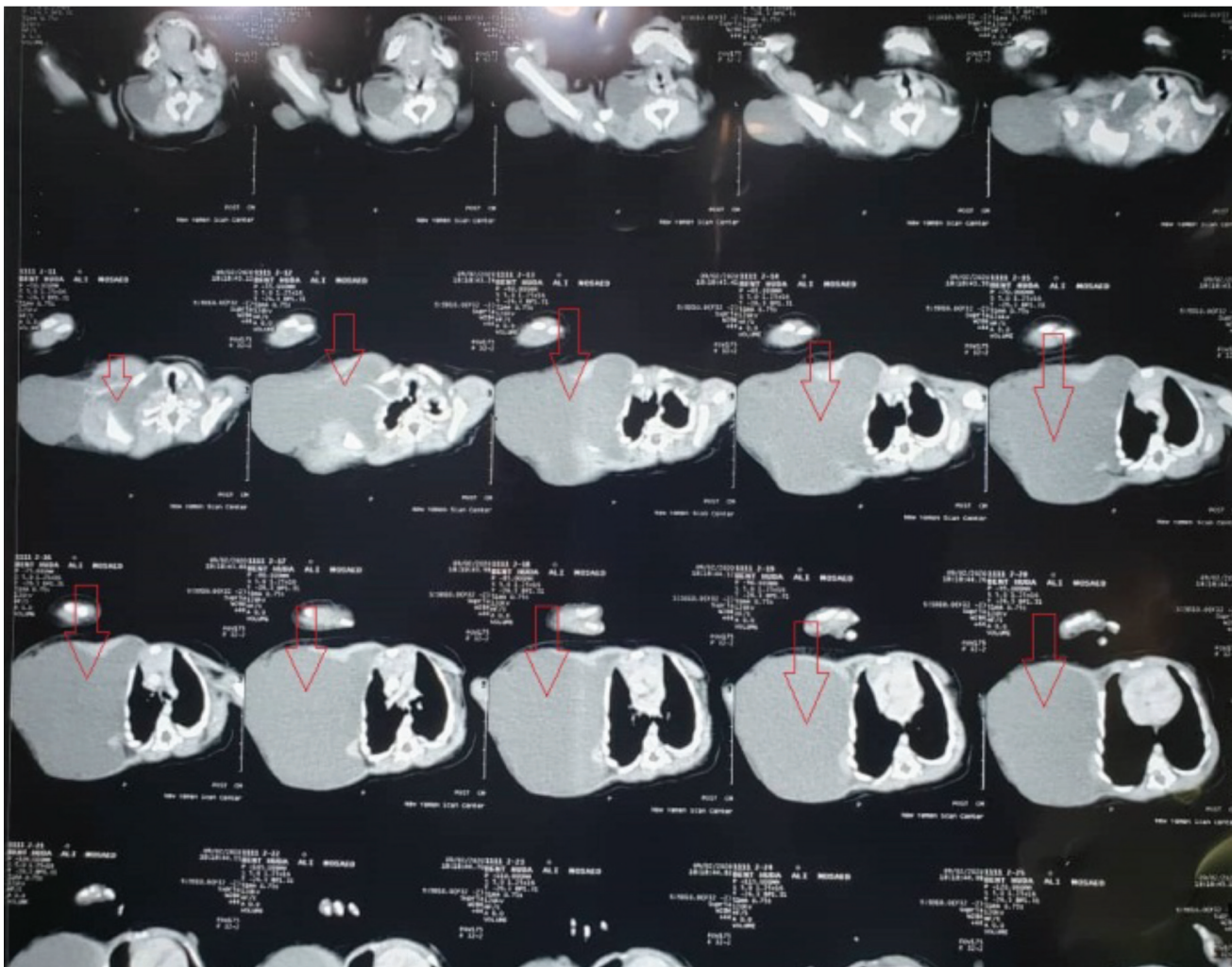


Figure 2. Computed tomography scan of the neck and thoracic scan revealed a lobulated cystic lesion measure about $10.7 \times 9.8 \times 9.2$ cm with poor enhancement after intravenous contrast injection involving the right later posterior chest wall and extensions to the axilla and right side of the neck (C1 level).

with rare aggregates of lymphocytes (Figure 4 A and B).

Follow-up and outcomes

The parents were advised to bring their child for a periodic check-up to monitor the condition. During the 6-month follow-up, the physical examination revealed no recurrent lesion masses or any complications.

Discussion

CH is a congenital malformation of the lymphatic system in which 75% of these malformations occur in the neck, 20% in the axilla, and 5% in other parts of the body.⁵ The main cause of CH is the obstruction between the lymphatic vessels and the jugular venous system. The size of CH is varied from a few millimeters to several centimeters in diameter and can be loculated or septated. There are many published papers on cystic hygroma, but only a few reports have been published about giant CH in the cervico-axillo-thoracic area.⁵ Axillo-thoracic CH may be diagnosed during a routine antenatal ultrasound. Very few had been reported as diagnosed prenatally. Additionally, few cases have been reported of shoulder dystocia caused by axillary lymphangioma diagnosed after delivery, for instance, McCoy et al.⁶

limb-body wall complex, body stalk anomaly, simple cysts, cystic hygroma, ectopia cordis, branchial cleft cysts, hemangiomas, lymphoceles, teratomas, Maffucci syndrome, Klippel Trénaunay syndrome, and amniotic band syndrome are the

differential diagnosis of prenatal CH in axilla and/or anterior chest wall.⁷ The prognosis for CH is grim if the karyotype is abnormal, or if ascites and pleural fluid are present, or if bilateral pleural effusions are seen.⁵

Previously published articles have suggested that prenatal diagnosis of CH in early pregnancy and septated CH were associated with a poor prognosis. While the prognosis of non-septated CH and late pregnancy detection had a good prognosis,^{8, 9} Romero et al. reported a 68% incidence of abnormal karyotype, mainly Turner's syndrome. To this end, prenatal diagnosis, especially when CH is located in the neck of the fetus, would necessitate an analysis of fetal karyotype by amniocentesis or cordocentesis. However, in our case, it was impossible due to the low-income of the family and the lack of laboratory investigations.⁵

The main presentation of CH apparent at birth is a painless mass, such as our case. The other presentations are related to the complications or effects of CH, such as respiratory distress, fever, a sudden increase in size, feeding difficulty, and infection.³ Ultrasonography of the CH usually features a multicystic lesion with internal septations and no blood flow on color Doppler ultrasonography. CT scan and magnetic resonance imaging (MRI) can be used to find the border of the lesion better. A CT scan demonstrates a multicystic, non-invasive, and homogeneous density associated with low attenuation. These modalities are helpful in identifying the exact

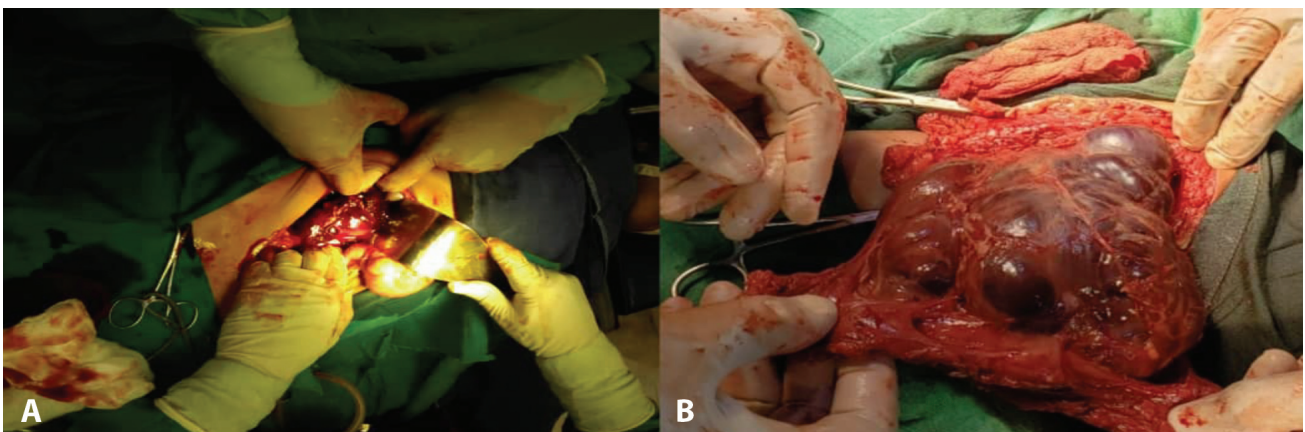


Figure 3. (A and B) These figures represent the macroscopic view of the surgical specimen during operation.

location of the lesion and their association with nerves or blood vessels, particularly when surgical management is planned.³ The treatment of choice is complete surgical excision; however, several studies strongly suggest sclerosant agents' therapy. The other treatment modalities include aspirations, drainage, laser excision, radiation, cauterization, and radio-frequency ablation, which have variable results and outcomes.⁵ After incomplete surgical excision, recurrences may develop. Their treatment can cause nerve damage when an extensive surgical dissection is necessary to remove huge lesions. There are several treatment options and lesions recurrence rate should always be taken into account in the choice of treatment.³ There is no exact definition of a huge CH. However, Atalar et al. reported a giant fetal axillo-thoracic CH. The characteristics of this lesions was multiseptated cystic mass measuring about 12 cm in diameter, involving the left side, the left axilla, the lateral chest wall, and the left humerus, which was treated through intralesional OK-432 injections.⁵ On the contrary, Song et al. suggested that surgical excision is the treatment of choice when lesions are large. They surgically treated an 8 × 6 cm-sized CH located in the left lateral chest wall.¹ Another article described a large CH measured 14 × 11 cm, managed with surgical excision.¹⁰ All of which were in accordance with our case.

Conclusion

CH is a congenital malformation of the lymphatic system that can be treated in the

pediatric population. The best treatment option varies based on the case. In our case, complete surgical excision was the selective treatment for this lesion.

Patient Perspective

The patient's parents mentioned that "the baby needed to be visited by a doctor. When the doctor visited our baby, he referred us to a good surgeon who performed all the radiologic investigations. He told us that our baby needs surgery. The doctor explained things well and explained complications that may happen during surgery. However, we had anxiety about the outcome of surgery because the mass was huge and cosmetic issues in the future could be a serious problem. Thus, we consulted other physicians and received the same explanation. We knew that the operation must be carried out and that the success rate is acceptable. On the other hand, we also understood that the tumor might have nerve involvement in the neck, leading to swallowing and speech problems. In the end, we decide to accept the surgery. After surgery, we were delighted with the surgery outcome".

Informed Consent

The patient's parents gave their written informed consent for participation in our study.

Conflict of Interest

None declared.

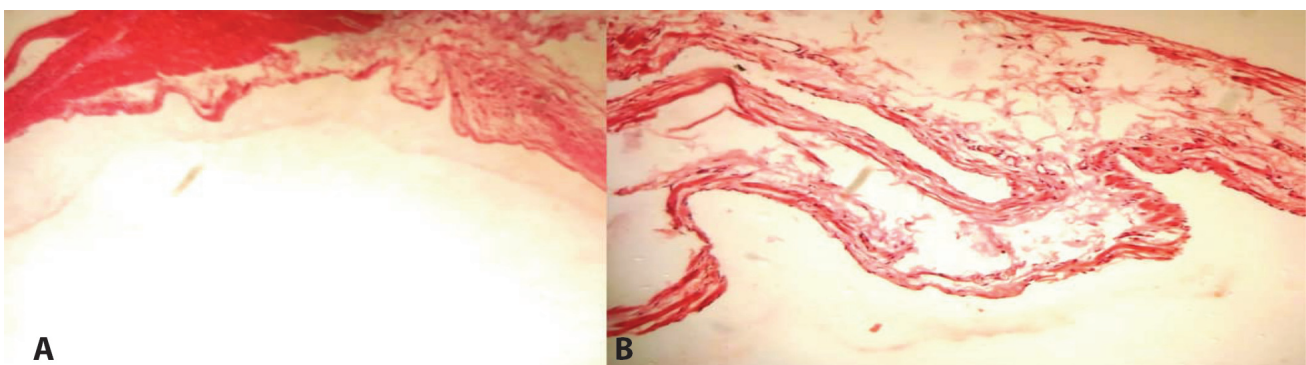


Figure 4. (A and B): Histological examination demonstrated large, irregular vascular spaces mostly denuded and partially lined by flattened, bland endothelial cells with fibroblastic or collagenous stroma.

References

1. Song TB, Kim CH, Kim SM, Kim YH, Byun JS, Kim EK. Fetal axillary cystic hygroma detected by prenatal ultrasonography: a case report. *J Korean Med Sci.* 2002;17(3):400-2. doi: 10.3346/jkms.2002.17.3.400.
2. Nistor C, Bluoss C, Mota N, Mota C, Davidescu M, Horvat T. Cervico-mediastinal lymphangioma. *Pneumologia.* 2009;58(2):108-12.
3. Mirza B, Ijaz L, Saleem M, Sharif M, Sheikh A. Cystic hygroma: an overview. *J Cutan Aesthet Surg.* 2010;3(3):139-44. doi: 10.4103/0974-2077.74488.
4. Kaur N, Gupta A, Singh N. Giant cystic hygroma of the neck with spontaneous rupture. *J Indian Assoc Pediatr Surg.* 2007;12(3):154. doi: 10.4103/0971-9261.34959.
5. Atalar MH, Cetin A, Kelkit S, Buyukayhan D. Giant fetal axillo-thoracic cystic hygroma associated with ipsilateral foot anomalies. *Pediatr Int.* 2006;48(6):634-7. doi: 10.1111/j.1442-200X.2006.02263.x.
6. McCoy MC, Kuller JA, Chescheir NC, Coulson CC, Katz VL, Nakayama DK. Prenatal diagnosis and management of massive bilateral axillary cystic lymphangioma. *Obstet Gynecol.* 1995;85(5):853-6. doi: 10.1016/0029-7844(94)00312-2.
7. Chen CP. Prenatal imaging of the fetal anterior chest wall cystic hygroma by magnetic resonance imaging. *Prenat Diagn.* 2003;23(13):1099-100.
8. Langer JC, Fitzgerald PG, Desa D, Filly RA, Golbus MS, Adzick NS, et al. Cervical cystic hygroma in the fetus: clinical spectrum and outcome. *J Pediatr Surg.* 1990;25(1):58-62. doi: 10.1016/s0022-3468(05)80164-2.
9. Temizkan O, Abike F, Ayyvacı H, Demirag E, Görücü Y, Isik E. Fetal axillary cystic hygroma: a case report and review. *Rare Tumors.* 2011;3(4):e39. doi:10.4081/rt.2011.e39.
10. Masood SN, Masood MF. Case report of fetal axillo-thoraco-abdominal cystic hygroma. *Arch Gynecol Obstet.* 2010;281(1):111-5. doi:10.1007/s00404-009-1068-2.