

# Complications of Radiotherapy after Immediate Breast Reconstruction with Implant: Risk Factors and Management - Our Institute's Experience

Heba G. El-Sheredy\*<sup>†</sup>, Rabie Ramadan\*\*, Yasser Hamed\*\*

\*Cancer Management and Research Department, Medical Research Institute, Alexandria University, Alexandria, Egypt

\*\*Department of Surgery, Medical Research Institute, Alexandria University, Alexandria, Egypt

## Abstract

**Background:** Breast cancer is the most frequent malignant tumor in women worldwide. In recent years, defined reconstruction principles along with numerous surgical techniques with volume replacement have been published. Autologous breast reconstruction is more natural but leaves donor site morbidity. It provides the opportunity to restore the breast mound without the need for scars. This study aims to evaluate the complications of radiotherapy after immediate breast reconstruction with implants in breast cancer patients who submitted to skin sparing mastectomy and nipple sparing mastectomy by taking into consideration the risk factors and management at our institution.

**Methods:** The current study prospectively included patients with invasive breast cancer admitted between January and June 2013 who were scheduled for skin sparing mastectomy or nipple sparing mastectomy and axillary dissection followed by immediate breast reconstruction with implant. Patients received adjuvant chemotherapy followed by conventional fractionated radiation. Complications were classified as either minor or major. The minor complications included capsular contracture (Baker 1-2), seroma, minor skin infection and skin dehiscence without exposure of the implant. Major complications included capsular contracture (Baker 3-4), severe infection and major wound dehiscence with implant exposure. Capsular contracture was scored according to the modified Baker classification.

**Results:** The study included 38 patients. Of these, 28 had skin sparing mastectomy while 10 underwent nipple sparing mastectomy. The overall complication rate was 71%. We observed minor complications in 18 patients while 9 patients had major complications. Complications occurred with a median time of 13 months following radiotherapy completion. All minor complications were managed conservatively whereas all major complications required repeat surgery. No loco-regional recurrences occurred during the follow up period.

**Conclusion:** We determined that age >40 years, smoking, diabetes, dose to prosthesis  $\geq 45$  Gy, and prosthetic volume exposed to the radiation dose of >75% were risk factors for the development of post-radiation complications in an immediately reconstructed breast with implant after skin sparing mastectomy and nipple sparing mastectomy. Adequate selection of patients to exclude those who have significant risk to develop complications will lower the complication rate, improve surgical techniques, allow better quality of implants, and limit tissue damage after radiotherapy.

**Keywords:** Immediate reconstruction, Breast cancer, Adjuvant radiotherapy, Complications, Capsular contracture

### Corresponding Author:

Heba G. El-Sheredy, MD  
Cancer Management and  
Research Department, Medical  
Research Institute, Alexandria  
University, Alexandria, Egypt  
Email: Heba.gaber99@yahoo.com



## Introduction

Breast cancer is the most frequent malignant tumor in women worldwide. The incidence and mortality rates vary among countries. In recent years, these rates have steadily increased worldwide, particularly in developing countries such as Egypt. This is largely attributed to the westernization of the community, including delay in the time of the first pregnancy, decreased breast feeding and a move towards Western diets high in calories.<sup>1</sup>

In Egypt, breast cancer is estimated to be the most common cancer among women, representing 33.5% of newly diagnosed cancer cases. It is also the leading cause of cancer related mortality, accounting for 29.1% of all cancer deaths among Egyptian women.<sup>2</sup> These estimates are confirmed in many regional Egyptian cancer registries.<sup>3,4</sup> In recent years, breast reconstruction can be safely provided to most women with early-stage breast cancer, replacing mastectomy as the predominant treatment. Breast conservation is important when fulfilling the two criteria oncological safety and cosmesis which are the cornerstones of modern breast surgery.<sup>5</sup>

Oncoplastic surgery combines the principles of surgical oncology with those of plastic and reconstructive surgery. The introduction of oncoplastic techniques in the management of breast cancer have improved cosmetic results, increasing the technical alternatives available to general surgeons who specialize in breast cancer surgery.<sup>6</sup>

In previous years, reconstruction principles have been defined. Numerous surgical techniques with volume displacement and volume replacement have been published with different indications, incision lines and suggested rotation techniques.<sup>7</sup>

In volume replacement, myocutaneous and myosubcutaneous autologous flaps and implants are commonly used to replace the amount of tissue resected.<sup>7</sup> Autologous breast reconstruction is more natural but increases donor site morbidity. Many patients are discouraged about the long operation and extended recovery.<sup>8</sup>

Implant based reconstruction which is popular in Europe can be undertaken as a single “direct to implant” procedure, or more commonly as “expander/implant” successive procedures. It provides the opportunity to restore the breast mound without the need for donor scars. Patients possibly prefer implants because they may be less painful.<sup>9</sup>

Many institutions are comfortable with implant reconstructions. Surgeons who perform breast reconstruction may prefer implants as they are easier to perform, faster and require a shorter learning curve than autologous reconstructions.<sup>10</sup> However; implants are not free from complications. Studies from Europe have reported a tolerable rate of capsular contractions, exposures and infections. Repeat surgery does not seem to be a problem. Sometimes the repeat surgery is a “normal” happening with implants and patients may accept the probability without undue anxiety.<sup>11</sup>

Randomized clinical trials in patients with early-stage breast cancer have demonstrated that following breast-conserving surgery, adjuvant whole breast irradiation (WBI) lowers the relative risk of ipsilateral breast tumor recurrence (IBTR) by approximately 70% at 5 years and produces a 5% absolute improvement in 15-year overall survival.<sup>12</sup> An additional dose escalation to the tumor bed as a boost reduces the local relapse rate in selected patients.<sup>13</sup> Following mastectomy, radiotherapy is indicated to lower the rates of local recurrence in breast cancer patients. Node positive patients are most likely to require radiotherapy.<sup>14</sup>

This study aimed to evaluate the complications of radiotherapy after immediate breast reconstruction with implant in breast cancer patients that underwent skin sparing mastectomy (SSM) and nipple sparing mastectomy (NSM) at our institution. The risk factors and management of these complications were evaluated.

## Patients and Methods

The current study prospectively included patients with pathologically proven invasive breast

cancer admitted to the Department of Surgery at the Medical Research Institute Hospital, Alexandria University in the period between January 2013 and June 2013. Patients received either SSM or NSM and axillary dissection followed by immediate breast reconstruction with an implant.

The study included patients with multicentric breast cancer, invasive breast cancer with diffuse microcalcifications, and invasive breast cancer with a positive family history. The study patients were scheduled to receive post-operative radiotherapy as part of their adjuvant therapy. Patients who received neoadjuvant chemotherapy (NAC), those with inflammatory or metastatic breast cancer, patients with skin or chest wall involvement or ductal carcinoma in situ (DCIS) were excluded.

Preoperative evaluation of the studied patients included physical examination as well as bilateral mammogram and ultrasonography of both breasts and axillae. The diagnosis of breast cancer was made by fine needle aspiration (FNA) or core-needle biopsy of the breast tumor. The planned procedure was discussed with patients and we documented their approval.

Surgical technique included SSM or NSM and axillary dissection. The choice of SSM or NSM depended on the tumor size, location, the distance from the areola, and the pathological assessment of the retro-areolar disc by frozen section. Full axillary lymph node dissection (ALND) was performed for all studied patients.

The process of reconstruction occurred at the time of the surgery (immediate reconstruction). Patients had an implant immediately positioned in the subpectoral/subfacial pocket. We used silicone high viscosity gel filled implants of the smooth round type or anatomically structured implants. All patients with expected remarkable discrepancy between the two breasts post- excision were offered simultaneous reduction mammoplasty of the contralateral breast in order to improve the symmetry.

All specimens were subjected to pathological and immunohistochemical examination that included estrogen receptor (ER), progesterone

**Table 1.** Distribution of studied patients according to clinicopathological characteristics.

Characteristics	Breast cancer patients (N=38)
<b>Age</b>	
Range (y)	25-61
Median	43
<b>Smoking status</b>	
Non-smoker	30 (79%)
Smoker	8 (21%)
<b>Diabetic state</b>	
Non-diabetic	31 (81.6%)
Diabetic	7 (18.4%)
<b>Histological type</b>	
Invasive ductal	26 (68.4%)
Invasive lobular	5 (13.2%)
Mixed	7 (18.4%)
<b>Tumor stage</b>	
I	4 (10.6%)
II	26 (68.4%)
III	8 (21%)
<b>Histological grade</b>	
I	6 (15.8%)
II	24 (63.2%)
III	8 (21%)
<b>Lymph node metastasis</b>	
Yes	25 (65.8%)
No	13 (43.2%)
<b>Type of surgery</b>	
SSM	28 (73.7%)
NSM	10 (26.3%)
<b>ER/PR status</b>	
Negative	10 (26.3%)
Positive	28 (73.7%)
<b>Her-2/neu status</b>	
Negative	30 (79%)
Positive	8 (21%)

IDC: Invasive ductal; ILC: Invasive lobular; SSM: Skin sparing mastectomy; NSM: Nipple sparing mastectomy; ER: Estrogen receptor; PR: Progesterone receptor; Her-2: Human epidermal growth factor receptor 2

receptor (PR) and human epidermal growth factor receptor 2 (Her-2). Adjuvant chemotherapy regimens according to institutional protocols included 3-6 anthracyclines-based regimens with or without the addition of taxanes. Target therapy was added for those patients with Her-2 positive disease. Endocrine treatment was received according to hormonal receptor status.

All patients were treated with conventional fractionated (CF) radiation schemes that began after completion of chemotherapy. Radiotherapy was carried with 4-6 MV photon beams to the reconstructed breast/chest wall using tangential

fields. The total dose of radiotherapy was 45-50 Gy/18-25 fractions (2-2.5Gy/fraction) with or without a subsequent radiation boost to the tumor bed. In cases with axillary node involvement, patients were treated with a supraclavicular field with or without posterior axillary boost given in selected cases.

Postoperative clinical follow-up occurred immediately after surgery and then every three months. The follow up continued for two years after the completion of the radiotherapy course. Follow up examination included palpation of the reconstructed breast and axilla. Mammograms and ultrasonography were done according to the standard protocol.

Complications were systematically retrieved at each clinical exam. These complications were classified as minor or major. Minor complications included capsular contracture (Baker 1-2), seroma, minor skin infection, and skin dehiscence without exposure of the implant. Major complications included capsular contracture (Baker 3-4), severe infection, and major wound dehiscence with implant exposure. Capsular contracture was scored according to the modified Baker classification.<sup>15</sup>

### Statistical analysis

Statistical analyses were conducted using the Statistical Package for the Social Sciences (SPSS version 20, Chicago, IL, USA) software. Quantitative data were expressed in terms of mean and standard deviation whereas qualitative data were expressed as numbers and percentages. Means were compared using the student's t-test, whereas qualitative data were compared using the chi-square test. The median follow-up was estimated by the inversed Kaplan-Meier method. Risk factors for complications were analyzed by univariate and multivariate logistic regression tests. In all statistical tests, a level of significance of 0.05 was used, below which the results were considered to be statistically significant.

### Results

The current study included 38 patients, of whom 28 (73.7%) underwent SSM, whereas 10

**Table 2.** Post-radiotherapy complications.

Type of complication	N (%)
<b>Minor</b>	<b>18 (66.7)</b>
• Capsular contracture (Baker 1-2)	4 (14.8)
• Seroma	5 (18.6)
• Minor skin infection	6 (22.2)
• Skin dehiscence without exposure of the implant	3 (11.1)
<b>Major</b>	<b>9 (33.3)</b>
• Capsular contracture (Baker 3-4)	3 (11.1)
• Severe infection	2 (7.4)
• Major wound dehiscence with implant exposure	4 (14.8)
Total	27 (100)

(26.3%) had NSM. The median age of patients was 43 years. There were 8 (21%) patients who smoked. A total of 18.4% of the patients (n=7) were diabetics. Clinicopathological characteristics of the studied patients are summarized in table 1.

The overall complication rate was 71% (27 patients) from which 18 (66.7%) had minor complications whereas 9 (33.3%) exhibited major complications. Complications occurred with a median time of 13 months following completion of radiotherapy (range: 4-22 months). Table 2 summarizes the different complications.

We studied the risk factors in order to evaluate their association with development of post-radiation complications in the immediately reconstructed breast with implant. These risk factors included clinicopathological characteristics of age, smoking, diabetes, disease stage, tumor grade, her-2/neu status, hormonal receptors status, type and volume of prosthesis. The evaluated radiation dosimetric characteristics included dose to prosthesis and prosthetic volume exposed to the radiation dose.

There was a statistically significant incidence of complications with age >40 years ( $P=0.002$ ), smoking ( $P=0.003$ ), diabetes ( $P=0.04$ ), dose to prosthesis  $\geq 45$  Gy ( $P=0.007$ ), and prosthetic volume exposed to the radiation dose >75% ( $P=0.009$ ). Tumor stage ( $P=0.42$ ), tumor grade ( $P=0.96$ ), her-2/neu status ( $P=0.58$ ), hormonal receptor status ( $P=0.62$ ), type of prosthesis ( $P=0.16$ ) and volume of prosthesis ( $P=0.35$ ) had no statistically significant association with the

development of post-radiation complications. The risk factors correlated with development of post-radiation complications are summarized in table 3.

All the minor complications (n=18) had conservative management while all cases with major complications (n=9) needed additional surgery for management. The management of major complications included capsulectomy with removal of the implant with implant exchange (2 cases), capsulectomy with removal of the implant and de-epithelialized transverse rectus abdominis myocutaneous flap (TRAM) in 2 cases, excision of all radiated skin and correction by TRAM (1 case), removal of the implant with excision of all radiated skin without reconstruction (2 cases), and capsulectomy with removal of the implant and lipofilling (2 cases). The case by case management of major complications is summarized in table 4.

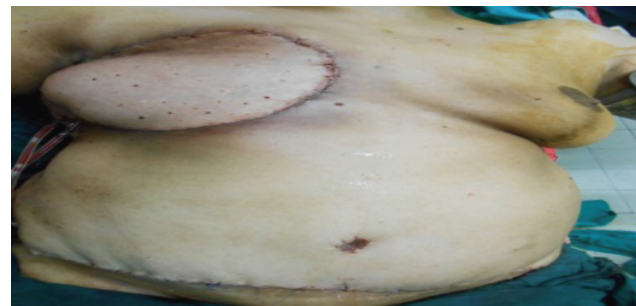
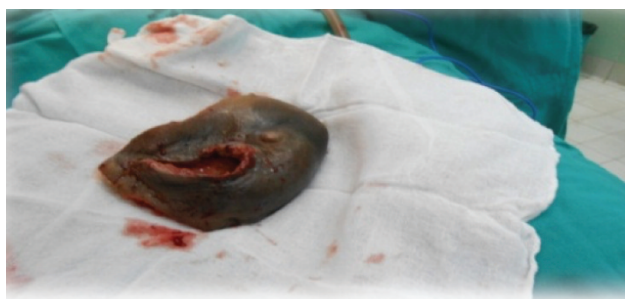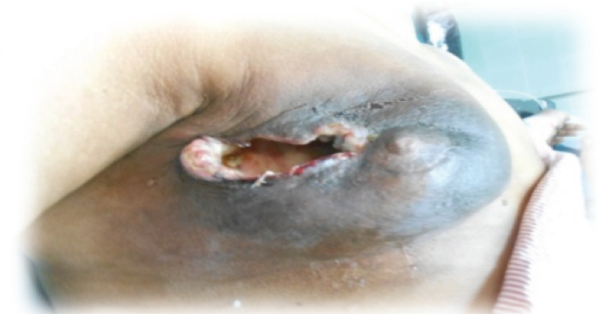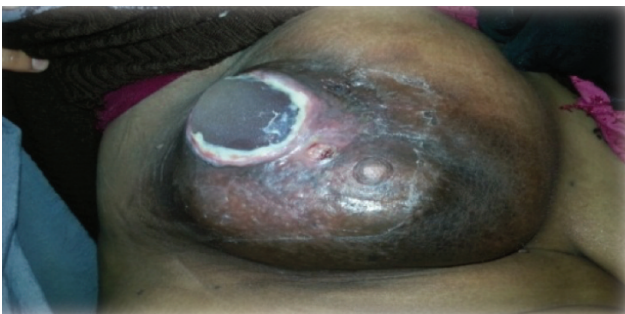No loco-regional recurrences occurred during the follow up period. Figures 1-3 show examples of complications that have occurred and their management in the study patients.

## Discussion

Oncoplastic breast surgery allows for a wider resection of the tumor with tumor-free resection

margins without risking major local defects or deformity. Good aesthetic results can be achieved due to the advantage of immediate reconstruction of the partial mastectomy defect.<sup>6</sup> Immediate breast reconstruction is often recommended for psychosocial benefits, but obviously this needs to be weighed against the judgment of the patient and surgeon, and individual oncologic needs including additional surgery and adjuvant radiotherapy.<sup>16</sup> Numerous surgical techniques with tissue displacement and tissue replacement have been published with different indications, incision lines and suggested rotation techniques.

Radiotherapy is an essential component of modern breast cancer therapy. The indications for postoperative radiotherapy have expanded to include what was previously thought as intermediate risk for local recurrence. Current guidelines imply the use of postoperative radiotherapy for 1-3 positive nodes after mastectomy.<sup>17</sup> Many reports suggest that radiotherapy adversely affects reconstruction outcomes, even with autologous reconstruction. Some reports refrain from immediate reconstruction due to the loss of cosmesis after radiotherapy.<sup>18</sup> We do not believe that autologous



**Figure 1.** Female patient with left breast cancer treated by nipple sparing mastectomy (NSM) and implant reconstruction. At 17 months after adjuvant radiotherapy, she developed severe capsular contraction and exposure of the implant. The area was treated by excision of all radiated skin and correction by transverse rectus abdominis myocutaneous flap (TRAM).

**Table 3.** Risk factors associated with the development of complications.

Risk factor	No. of patients having this risk factor	No. of patients having this risk factor and developing complications	Type of complication		P-value
			Minor	Major	
<b>Age (y)</b>					
≤40	18/38	8/27	6/18	2/9	0.002
>40	20/38	19/27	12/18	7/9	
<b>Smoking</b>	8/38	7/27	2/18	5/9	0.003
<b>Diabetes</b>	7/38	5/27	3/18	2/9	0.04
<b>Tumor stage</b>					
I	4/38	2/27	2/18	0/9	0.42
II	26/38	22/27	15/18	7/9	
III	8/38	3/27	1/18	2/9	
<b>Tumor grade</b>					
I	6/38	3/27	1/18	2/9	0.96
II	24/38	19/27	15/18	4/9	
III	8/38	5/27	2/18	3/9	
<b>ER/PR status</b>					
Negative	10/38	6/27	3/18	4/9	0.58
Positive	28/38	21/27	15/18	6/9	
<b>Her-2/neu status</b>					
Negative	30/38	23/27	16/18	7/9	0.62
Positive	8/38	4/27	2/18	2/9	
<b>Prosthetic volume (cc)</b>					
≤300	16/38	9/27	6/18	3/9	0.35
>300	22/38	18/27	12/18	6/9	
<b>Type of prosthesis</b>					
Smooth round type	23/38	18/27	10/18	8/9	0.16
Anatomical structured	15/38	9/27	18/18	1/9	
<b>Dosimetry characteristics</b>					
<b>Dose to prosthesis</b>					
<45 Gy	16/38	7/27	5/18	2/9	0.007
≥45 Gy	22/38	20/27	13/18	7/9	
<b>Prosthetic volume exposed to radiotherapy</b>					
≤75%	19/38	5/27	3/18	2/9	0.009
>75%	19/38	22/27	15/18	7/9	

ER: Estrogen receptor; PR: Progesterone receptor; Her-2: Human epidermal growth factor receptor 2.

reconstruction is an appealing option for women who require mastectomy in our society. Most of our patients would not choose that option when offered. The complexity of this option is counter-productive.

The majority of our patients prefer the simple mastectomy technique rather than complex, long autologous procedures. Most would not prefer to undergo delayed reconstruction for the same reasons. The field of implant-based reconstruction has continually undergone changes. These changes include the advent of dual chambers, anatomic and

cohesive variations, texture modifications, and ever-evolving proprietary manipulation. As a result, implant-based reconstruction data are difficult to standardize over any prolonged period of time. Similarly, size of the implant, initial volume, final volume, and rapidity of expansion are tailored to meet patient goals and expectations, and can never be fully standardized. The development of skin-sparing and, more recently, nipple-sparing techniques also adds a distinct element to the gamut of variability.<sup>19</sup>

In the current study, all the patients underwent

**Table 4.** Case by case management of major complications.

Major complication	No.	Management
Capsular contracture (Baker 3-4)	3	Capsulectomy, then excision of all radiated skin and correction by TRAM. Capsulectomy with replacement of implant by de-epithelialized TRAM. Capsulectomy with removal of the implant with implant exchange.
Severe infection	2	Removal of the implant with excision of all skin without reconstruction. Removal of the implant with excision of all skin with delayed lipofilling.
Major wound dehiscence with implant exposure	4	Removal of implant with delayed correction by lipofilling. Removal of implant and replacement by de-epithelialized TRAM. Removal of the implant with excision of all skin without reconstruction. Capsulectomy with removal of the implant with implant exchange.
<b>Total</b>	<b>9</b>	

TRAM: Transverse rectus abdominis myocutaneous flap

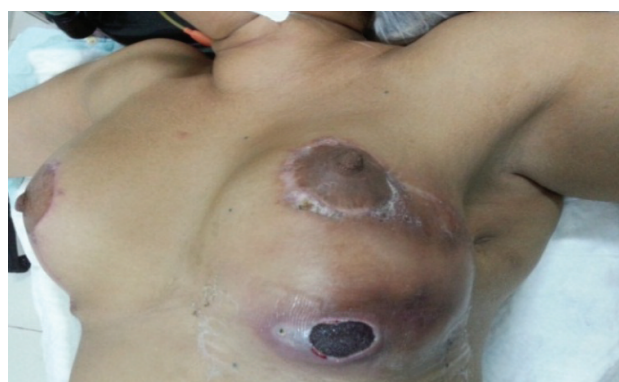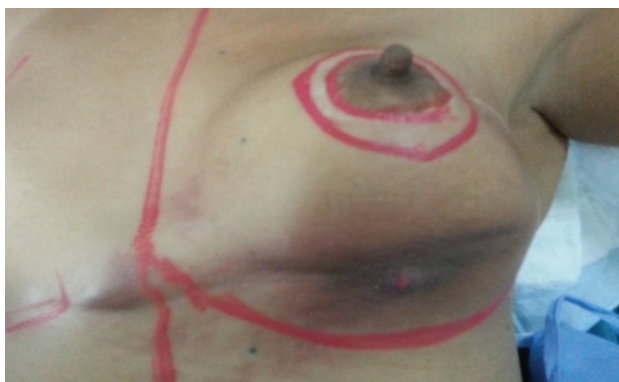
volume replacement techniques with implants. All patients were treated with conventional fractionated radiation after completion of chemotherapy. The overall complication rate of the implant-based reconstruction was 71%, with a repeat surgery rate of 33.3%. This percentage was higher than reported by Rosen et al.<sup>20</sup> that had a complication rate of 23% and Hughes et al.<sup>19</sup> that had a complication rate of 10%. It was also higher than the rate reported in a large study conducted by Bailey et al. that included 165 cases with immediate reconstructions that resulted in 22% implant and 15% expander loss, and an overall complication rate of 57%.<sup>21</sup> This variation, as explained by Tran et al. and Veronesi et al. might reflect not only differences in the implants themselves, but also improvements in the surgical techniques achieved over the last 30 years.<sup>22,23</sup>

In the current study, the high rate of

complications might be due to radiotherapy administration techniques and devices, lack of intra-operative radiotherapy techniques, and lack of oncoplastic surgical experience at the time of the current study. Recently, our surgical techniques have become more refined. The same advancement in the radiotherapy administration techniques and devices has been achieved.

There are two major concerns regarding implant reconstruction following SSM and NSM. First, most breast reconstructions occur in the anterior chest skin. Therefore SSM and NSM may increase the risk of recurrence.<sup>16</sup> The breast surgeon must balance the risk of skin necrosis in the residual skin flap to the risk of recurrence if breast tissue is left behind in the SSM and NSM flap.

Secondly, one would expect breast irradiation to be associated with higher postoperative



**Figure 2.** A 52-year-old female with left breast cancer treated by skin sparing mastectomy (SSM) and implant reconstruction. After adjuvant radiotherapy she developed capsular contraction (Baker 3). The patient underwent a capsulectomy with replacement of the implant by de-epithelialized transverse rectus abdominis myocutaneous flap (TRAM).

complication that can adversely affect the aesthetic outcome of an immediate breast reconstruction.<sup>24</sup> Several studies have shown that radiation therapy is associated with an unacceptably high rate of capsular contracture and rupture of the implant envelope or capsule that required an additional flap to restore breast shape and symmetry.<sup>24,25</sup> A study by Spear SL et al, comprising of 40 consecutive patients undergoing staged expander/implant placement and radiotherapy, reported complications to be more common in the irradiated group (36%) than in the control group (7%). The infection rate was also higher at 4% in the irradiated group as compared to the control group. Capsular contracture rate was 21% in the irradiated group vs. 0% in the control group. Finally, 32% of irradiated breasts with implants ultimately needed the addition of a flap.<sup>26</sup>

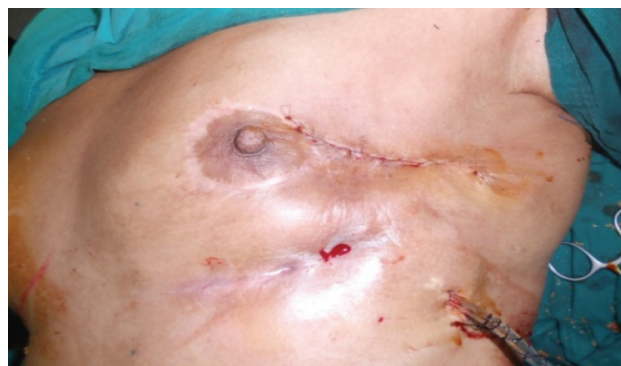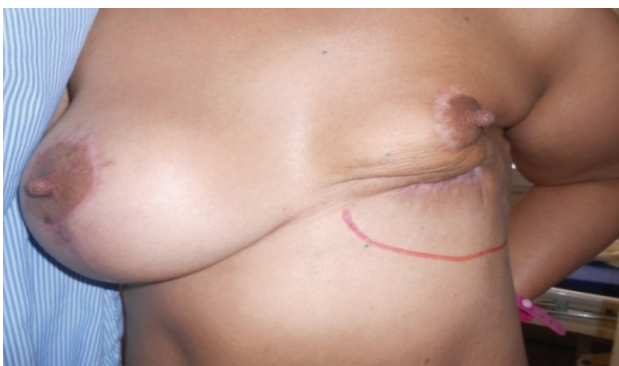Several studies reported a major complication rate of approximately 20% in patients who underwent immediate implants following SSM, NSM plus adjuvant radiotherapy.<sup>27-29</sup> These results matched the results of the current study, which had a major complication rate of 33.3% of all complicating cases and 23.7% of all study cases. Another study suggested that careful selection of patients could result in a decreased complication rate,<sup>30</sup> which was the same as the results of our study where we recommended exclusion of patients who have significant risk factors in order to lower the complication rate.

Hughes et al.<sup>19</sup> reported an overall complication rate of the implant-based reconstruction of 15%,

with a repeat surgery rate of 10%. This study concluded that none of the patients had greater than Baker grade 2 capsular contracture and the overwhelming majority were classified as grade I. This differed from our results which concluded that 7 cases had capsular contracture (4 cases had grade 1 and 2 while 3 cases had grade 3 and 4). We think this difference might be due to radiotherapy administration techniques and devices. On the other hand, our results supported the results of a study by Behranwala et al. which observed capsule formation in 13/92 (14.1%) of reconstructed breasts that underwent no radiation therapy and in 17/44 (38.6%) reconstructed breasts with radiation therapy. On univariate analysis, radiation therapy was the only variable related to capsule formation ( $P<0.001$ ).<sup>31</sup>

This study concluded that age  $>40$  years ( $P=0.002$ ), smoking ( $P=0.003$ ), diabetes ( $P=0.04$ ), dose to prosthesis  $\geq 45$  Gy ( $P=0.007$ ), and prosthetic volume exposed to the radiation dose  $>75\%$  ( $P=0.009$ ) had statistically significant associations with the incidence of post-radiation complications. On the other hand, tumor stage ( $P=0.42$ ), tumor grade ( $P=0.96$ ), Her-2/neu status ( $P=0.58$ ), hormonal status ( $P=0.62$ ), type of prosthesis ( $P=0.16$ ), and volume of prosthesis ( $P=0.35$ ) had no statistically significant associations with the development of post-radiation complications.

The study conducted by Bailey et al, had identified some significant risk factors associated with complications after breast reconstruction. These factors included smoking at time of surgery,



**Figure 3.** A 57-year-old female patient with a history of smoking, diagnosed with cancer of the left breast was treated by nipple sparing mastectomy (NSM). After adjuvant radiotherapy, the patient had exposure of the implant. The implant was removed and she had delayed correction by lipofilling.



using immediate gel implant, failure to achieve complete muscle coverage of the implant, initial implant of 400 ml volume or more and patient's age. On the hand they concluded that type of chemotherapy, history of previous smoking and clinical stage had no statistically significant associations with the development of post-reconstruction complications.<sup>21</sup>

In this study the follow up continued for two years after completion of radiotherapy. We found that no loco-regional recurrences occurred during the follow up period. This was similar to a number of studies that reported no increases in the local recurrence rate in cases that underwent implant reconstruction following SSM and NSM.<sup>16, 32</sup>

### Conclusion

Age >40 years, smoking, diabetes, dose to prosthesis  $\geq 45$  Gy, and prosthetic volume exposed to a radiation dose >75% were risk factors for the development of post-radiation complications in an immediately reconstructed breast with an implant after SSM and NSM. We had a complication rate and reoperation rate higher than reported in the literature; this might be due to radiotherapy administration techniques and devices, as well as the lack of intra-operative radiotherapy techniques. We have recommended adequate selection of patients to exclude those with significant risk factors in order to lower the complication rate and improve the radiotherapy results. This will help to limit damage to surrounding tissue, improve surgical techniques, or allow better quality of implants. Due to the short period of the study and the low volume of patients studied, we have recommended that a larger scale study, longer period of time, and multicentric surveys be conducted to confirm the current study findings.

### Acknowledgements

All authors have contributed significantly to this work.

### Conflicts of Interest:

No conflict of interest is declared.

### References

1. Parkin DM, Fernández LM. Use of statistics to assess the global burden of breast cancer. *Breast J.* 2006;12 Suppl 1:S70-80.
2. Ibrahim AS, Khaled HM, Mikhail NN, Baraka H, Kamel H. Cancer incidence in Egypt: results of the national population-based cancer registry program. *J Cancer Epidemiol.* 2014;2014: 437971.
3. Dey S, Soliman AS, Hablas A, Seifeldin IA, Ismail K, Ramadan M, et al. Urban–rural differences in breast cancer incidence in Egypt (1999–2006). *Breast.* 2010;19(5):417-23.
4. Hirko KA, Soliman AS, Hablas A, Seifeldin IA, Ramadan M, Banerjee M, et al. Trends in breast cancer incidence rates by age and stage at diagnosis in gharbiah, Egypt, over 10 years (1999–2008). *J Cancer Epidemiol.* 2013;2013:916394.
5. Veronesi U, Stafyla V, Petit JY, Veronesi P. Conservative mastectomy: extending the idea of breast conservation. *Lancet Oncol.* 2012;13(7):307-311.
6. Clough KB, Lewis JS, Couturaud B, Fitoussi A, Nos C, Falcou MC. Oncoplastic techniques allow extensive resections for breast-conserving therapy of breast carcinomas. *Ann Surg.* 2003;237 (1):26-34.
7. Berry MG, Fitoussi AD, Curnier B, Couturaud B, Salmon RJ. Oncoplastic breast surgery: a review and systematic approach. *J Plast Reconstr Aesthet Surg.* 2010;63(8):1233-43.
8. Khafagy M, Fakhr I, Hamed A, Youssef O. Pedicled dermoglandular flap reconstruction following breast conserving surgery. *J Egypt Natl Canc Inst.* 2012;24(2): 91-6.
9. Lebovic GS. Oncoplastic surgery: a creative approach to breast cancer management. *Surg Oncol Clin N Am.* 2010;19(3):567-80.
10. Kaviani A, Sodagari N, Sheikhabaei S, Eslami V, Hafezi-Nejad N, Safavi A, et al. From radical mastectomy to breast-conserving therapy and oncoplastic breast surgery: a narrative review comparing oncological result, cosmetic outcome, quality of life, and health economy. *ISRN Oncol.* 2013;2013:742462.
11. Acea-Nebriil B. Conservative oncoplastic surgery in breast cancer: Indications and limitations to its application. *Cir Esp.* 2005;78(1):8-12.
12. Clarke M, Collins R, Darby S, Davies C, Elphinstone P, Evans V, et al. Effects of radiotherapy and of differences in the extent of surgery for early breast cancer on local recurrence and 15-year survival: an overview of the randomised trials. *Lancet.* 2005; 366(9503):2087-106.
13. Bartelink H, Horiot JC, Poortmans PM, Struikmans H, Van den Bogaert W, Fourquet A, et al. Impact of a higher radiation dose on local control and survival in breast-conserving therapy of early breast cancer: 10-year results of the randomized boost versus no boost

- EORTC 22881-10882 trial. *J Clin Oncol.* 2007;25(22):3259-265.
14. Goldhirsch A, Winer EP, Coates AS, Gelber RD, Piccart-Gebhart M, Thürlimann B, et al. Panel members. Personalizing the treatment of women with early breast cancer: highlights of the St Gallen International Expert Consensus on the Primary Therapy of Early Breast Cancer 2013. *Ann Oncol.* 2013;24(9):2206-23.
  15. Spear SL, Baker JL Jr. Classification of capsular contracture after prosthetic breast reconstruction. *Plast Reconstr Surg.* 1995;96(5):1119-23.
  16. Rozen WM, Ashton MW, Taylor GI. Defining the role for autologous breast reconstruction after mastectomy: social and oncologic implications. *Clin Breast Cancer.* 2008;8(2):134-42.
  17. Su YL, Li SH, Chen YY, Chen HC, Tang Y, Huang CH, et al. Post-mastectomy radiotherapy benefits subgroups of breast cancer patients with T1-2 tumor and 1-3 axillary lymph node(s) metastasis. *Radiol Oncol.* 2014;48(3):314-22.
  18. Slavin SA, Love SM, Sadowsky NL. Reconstruction of the radiated partial mastectomy defect with autogenous tissues. *Plast Reconstr Surg.* 1992;90(5):854-65.
  19. Hughes K, Brown C, Perez V, Ting JW, Rozen WM, Whitaker IS, et al. The effect of radiotherapy on implant-based breast reconstruction in the setting of skin-sparing mastectomy: clinical series and review of complications. *Anticancer Res.* 2012;32(2):553-7.
  20. Rosen PB, Jabs AD, Kister SJ, Hugo NE. Clinical experience with immediate breast reconstruction using tissue expansion or transverse rectus abdominis musculocutaneous flaps. *Ann Plast Surg.* 1990;25(4):249-57.
  21. Bailey MH, Smith JW, Casas L, Johnson P, Serra E, de la Fuente R, et al. Immediate breast reconstruction: reducing the risks. *Plast Reconstr Surg.* 1989;83(5):845-51.
  22. Tran T, Tran T, Miles D, Hill M, Lum SS. The impact of radiation on surgical outcomes of immediate breast reconstruction. *Am Surg.* 2011;77(10):1349-52.
  23. Veronesi P, Ballardini B, De Lorenzi F, Magnoni F, Lissidini G, Caldarella P, et al. Immediate breast reconstruction after mastectomy. *Breast.* 2011;20(3):104-7.
  24. Kronowitz SJ, Hunt K, Kuerer H, Babiera G, McNeese M, Buchholz T, et al. Delayed-Immediate Breast Reconstruction. *Plast Reconstr Surg.* 2004;113(6):1617-28.
  25. Kronowitz SJ, Robb GL. Breast reconstruction with postmastectomy radiation therapy: Current issues. *Plast Reconstr Surg.* 2004;114(4):950-60.
  26. Spear SL, Onyewu C. Staged breast reconstruction with saline-filled implants in the irradiated breast: recent trends and therapeutic implications. *Plast Reconstr Surg.* 2000;105(3):930-42.
  27. Nava MB, Cortinovis U, Ottolenghi J, Riggio E, Pennati A, Catanuto G, et al. Skin-reducing mastectomy. *Plast Reconstr Surg.* 2006;118(3):603-10; discussion 611-3.
  28. Baildam AD. Skin-sparing mastectomy. *Eur J Cancer.* 2011;47 Suppl 3:S342-3.
  29. Eskenazi LB. New options for immediate reconstruction: achieving optimal results with adjustable implants in a single stage. *Plast Reconstr Surg.* 2007;119(1):28-37.
  30. della Rovere GQ, Nava M, Bonomi R, Catanuto G, Benson JR. Skin-reducing mastectomy with breast reconstruction and sub-pectoral implants. *J Plast Reconstr Aesthet Surg.* 2008;61(11):1303-8.
  31. Behranwala KA, Dua RS, Ross GM, Ward A, A'hern R, Gui GP. The influence of radiotherapy on capsule formation and aesthetic outcome after immediate breast reconstruction using biodimensional anatomical expander implants. *J Plast Reconstr Aesthet Surg.* 2006;59(10):1043-51.