

Struma Ovarii Associated with Pseudo-Meigs' Syndrome: A Rare Presentation of an Infrequent Tumor

Sonia Chhabra, Namita Bhutani*, Sunita Singh, Mansi Aggarwal, Rajeev Sen

Department of Pathology, Post Graduate Institute of Medical Sciences (PGIMS), Rohtak, Haryana, India

Abstract

Struma ovarii is an uncommon highly specialized ovarian teratoma that accounts for less than 5% of mature teratomas. It is composed predominantly of mature thyroid tissue. Thyroid tissue is observed in 5%-15% of teratomas; however, to qualify as a struma ovarii tumor, the thyroid proportion must comprise more than 50% of the overall tissue. The combination of pseudo Meigs'syndrome and elevation of CA 125 with struma ovarii is a rare condition that can mimic ovarian malignancy. The majority of strumas are benign, however occasionally malignant transformation may be seen. We have reported a case of benign struma ovarii that presented with the clinical features of advanced ovarian carcinoma: complex pelvic mass, gross ascites, bilateral pleural effusion, and markedly elevated serum CA 125 levels. The patient underwent total abdominal hysterectomy and bilateral salpingo oophorectomy. Ascites and pleural effusion resolved completely, and the CA 125 levels have returned to normal following surgical excision. Patients with pseudo-Meigs' syndrome may present a diagnostic problem as they masquerade as carcinoma with malignant effusions. In addition, the coexistence of struma ovarii and pseudo-Meigs' syndrome is a very rare event. We emphasize by this report that, despite its rarity, a differential diagnosis of struma ovarii should be included for an ovarian mass.

Keywords: Struma ovarii, Ovarian neoplasms, Postmenopausal women, Pseudo-Meigs' syndrome, Monodermal teratoma

Introduction

Monodermal teratoma is a rare ovarian tumor that shows the presence of only a single type of cellular component. When present in >50% of only thyroid tissue as a major cellular component, it is known

as a struma ovarii.¹ Struma ovarii is the most common type of monodermal teratoma and accounts for 2.7% of all ovarian teratomas.² Mostly these are benign tumors, however, very rarely the malignant variant may occur that represents 0.01% of all ovarian tumors and 5%-

♦Corresponding Author:

Namita Bhutani, MD
252, Kailash Hill, New Delhi
110065, India
Tel: +91-9873101393
Fax: +91-1262-211308
Email: namitabhutani89@gmail.com



37% of all struma ovarii.³ The peak age incidence of struma is in the fifth decade, but cases have been reported in older post-menopausal women and uncommonly occur in pre-pubertal girls.⁴ The pathophysiology has not been clearly defined. The concomitant presence of pseudo-Meigs' syndrome with struma ovarii is a rare occurrence. When coexisting with pseudo Meigs' syndrome and elevation of CA 125, struma ovarii is highly suspected as an ovarian malignancy. The diagnosis of struma ovarii can only be made by histopathology analysis.⁵ Preoperative diagnosis is difficult because ultrasonography (US), computer tomography (CT) and nuclear magnetic resonance (NMR) are not specific enough. With these techniques, we can only see an adnexal mass that consists of solid and cystic parts.⁶ Only preoperative scintigraphy with iodine (I-131) can show active thyroid tissue. In difficult cases, immunohistochemical stains for thyroid transcription factor and/or thyroglobulin will confirm the diagnosis of struma ovarii.⁷

The present article focused on a patient that presented with struma ovarii. The patient was initially thought to have an ovarian malignancy prior to surgery based on clinical examination, radiological findings, and raised CA 125 level. Nevertheless, this syndrome must be considered in otherwise healthy postmenopausal women, who present with both new or recurrent hydrothorax and ascites as it might masquerade an ovarian malignancy.⁸

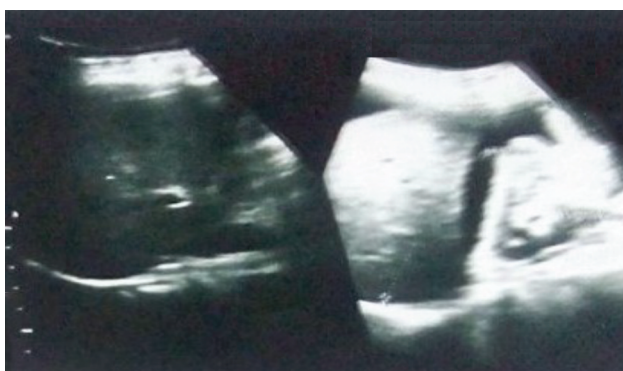

Figure 1A. Ultrasonography of abdomen and pelvis revealing a solid- cystic mass in left ovary with ascites.

Case Report

A 60-year-old postmenopausal female (gravida 6, para 4) presented to the gynecology outpatient with complaints of pain and abdominal distention for the previous one month. She also complained of increasing breathlessness of a ten-day duration. Abdominal examination revealed the presence of ascites; per vaginal examination, there was fullness in the left fornix. Ultrasonography of the abdomen and pelvis indicated a bulky left, heteroechoic ovarian mass that measured 9.4×9.0 cm with solid and cystic components. The features were suggestive of ovarian malignancy with ascites (Figure 1A). Chest x- ray depicted a massive pleural effusion (Figure 1B). Serum CA 125 level was 425U/ml (normal:<35 U/ml). AFP and CEA levels were within normal limits, as were the liver function tests.

Cytological examination of the ascitic and pleural fluid revealed the presence of reactive hyperplastic mesothelial cells, however malignant cells were not seen. Hence, the diagnosis of non-inflammatory serous effusion was suggested. Ultrasound guided fine needle aspiration from the ovarian mass showed degenerated cells with indistinct cytomorphological details in an amorphous background.

The patient was scheduled for an exploratory laparotomy with a vertical supraumbilical midline incision for diagnostic and therapeutic purposes. She had ascites and 1000 ml of straw colored

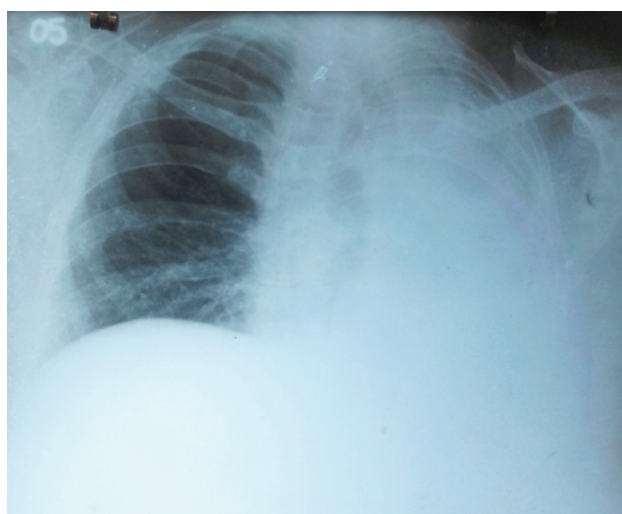


Figure 1B. Chest x-ray showing massive pleural effusion.

fluid was drained upon entrance into the peritoneal cavity. A 20×10 cm mixed cystic solid neoplasm arose from the left ovary. We received a specimen of hysterectomy with bilateral salpingo-oophorectomy. The left ovarian mass was partially cystic, solid in consistency, and measured 17×10.5×9 cm. On the cut surface, we observed a multicystic appearance with a few solid areas (Figure 2A, B). The cysts contained thick brownish colloid-like fluid. The specimen was extensively sampled.

Microscopic observation of the tumor indicated a lobular growth pattern composed of thyroid follicles that resembled normal thyroid tissue. The cells were cuboidal to columnar and displayed a prominent component of cells with oxyphilic cytoplasm. The follicles contained dense colloid. The nuclei were typically round to oval with minimal cytologic atypia and rare mitotic figures. The intervening stroma was scant (Figure 3A, B). It was confirmed to be colloid on periodic acid-Schiff (PAS) staining (Figure 4A, B). There were no visible features suggestive of malignancy such as invasion of the stroma, blood vessels, and capsule. Immunohistochemistry (IHC) analyses showed positive TTF-1 and thyroglobulin in normal thyroid follicles (Figure 5A, B). Hence, a diagnosis of monodermal teratoma struma ovarii was made. We considered the clinical presentation of the patient (hydrothorax, ascites, and a benign ovarian tumor other than a fibroma) and determined that this was a rare association of pseudo-Meigs' syndrome with struma ovarii.

The patient recovered uneventfully and was discharged on day 7 post operatively. Recovery

was rapid with no evidence of re-accumulation of the pleural effusion or ascites. At the 6-week follow up, the patient was clinically well with no evidence of disease on physical examination and a normal CA 125 level (8.0 U/ml).

Discussion

The coexistence of a pelvic tumor, hydrothorax, and ascites has been known since the late 19th century. Meigs and Cass described the features of the disease in 1937. This disease was named "Meigs' syndrome" by Roads in the same year.⁹ Today, Meigs' syndrome is defined as a triad of benign ovarian fibroma, hydrothorax, and ascites which resolves spontaneously after resection of the ovarian tumor. Whereas, pseudo-Meigs' syndrome is the co-existence of hydrothorax, ascites, and other ovarian or pelvic tumors. The association of pseudo-Meigs' syndrome with struma ovarii is a rare condition. Thus far only 10 to 11 cases have been reported in the English literature.²

The etiology of fluid accumulation in pseudo-Meigs' syndrome is unclear. The most probable pathogenesis of peritoneal and pleural effusions is ascribed to irritation of the peritoneum/pleura by the tumor, obstruction of the lymphatics, toxins, and release of inflammatory products, hypoalbuminemia, as well as discrepancies between the arterial supply and the venous and lymphatic drainage. These effusions are derived from a transudative process and regress spontaneously after removal of the neoplasm.¹⁰ However, detection of malignant cells in ascitic/pleural fluid is a marker of metastatic disease and a sign of poor prognosis. Benign effusions of pseudo-Meigs'

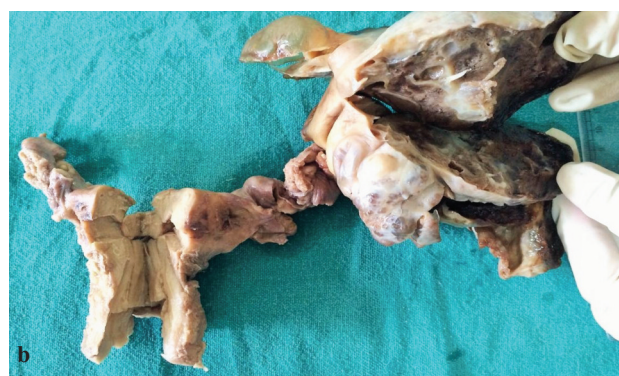
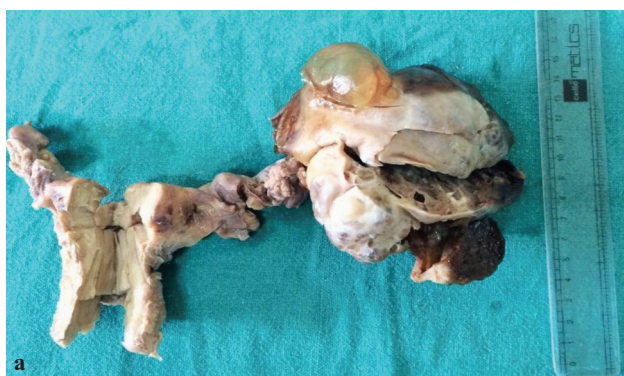
Figure 2. Grossly the tumor is solid and cystic with greenish brown fluid filled areas.

syndrome affect neither the disease stage nor patient prognosis.² Ascites may be present in up to one-third of the cases of struma ovarii. Struma ovarii rarely present as pseudo-Meigs' syndrome in approximately 5% of the cases. Struma ovarii may also be associated with other ovarian neoplasms such as Brenner tumor, serous cystadenoma, mucinous cystadenoma, and melanoma.⁴

Struma ovarii is a special type of monodermal teratoma, defined as a mature teratoma composed either exclusively or predominantly of thyroid tissue.¹ In the early 20th century, Pick first recognized that struma ovarii was composed of thyroid tissue and has suggested that ovarian goitres are actually teratomas in which thyroidal elements have overgrown the other tissues.¹¹ In 1933, Plaut showed that the thyroid tissue in struma ovarii was morphologically, biochemically, and pharmacologically identical to the cervical thyroid gland.¹² Struma ovarii has been reported to be the most common type of monodermal teratoma, accounting for nearly 3% of all ovarian teratomas.¹ It is defined as an ovarian teratoma composed predominantly (over 50%) or entirely of thyroid tissue or forms a macroscopically recognisable component of mature cystic teratoma.¹ Struma ovarii is the most common type of ovarian tumour associated with peripheral steroid cell formation.¹³ It occurs most commonly around the fifth decade of life. It is necessary to differentiate struma ovarii from the 10% of teratomas that contain an occasional focus of thyroid tissue. The tumor usually occurs as a

pelvic mass that may be palpable on physical examination.

Ultrasound usually shows a complex appearance with multiple cystic and solid areas that reflect the gross pathology. Nevertheless, Doppler flow may aid in the preoperative diagnosis of struma ovarii. Blood flow signals, detected from the center of the echoic lesion, and low resistance to flow may be more common in struma ovarii. Magnetic resonance imaging is more specific, with cystic spaces that show both high and low signal intensities on T1- and T2-weighted images which arise from the gelatinous colloid. Only preoperative scintigraphy with radioactive iodine (I131) of the minor pelvis can show active thyroid tissue. The use of US, CT, and MR imaging features of ovarian teratomas can aid in differentiation and diagnosis.⁶

The struma ovarii on gross appearance usually has a brown, solid, gelatinous sectioned surface with colloid filled cysts that are characteristic. The average reported size of the tumor is 10 cm in the largest dimension, mostly unilateral, with only 9.1% bilateral, a right side predominance, and elevated CA 125 levels. The signs and symptoms caused by struma ovarii can be due to the presence of the pelvic mass. Patients may present with clinical hyperthyroidism, ascites, pleural effusion, or no symptoms. The tumor may be functional in about 8% of cases and possibly associated with an enlarged thyroid gland in 10%-15% of patients.⁸ Surgical removal of the struma in such cases usually results in the resolution of symptoms.

On microscopic examination, it is composed of

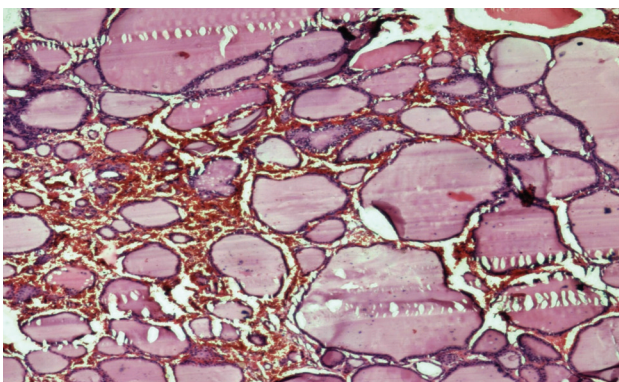


Figure 3A. Photomicrograph depicting colloid filled follicles of varying size (H&E, 40×).

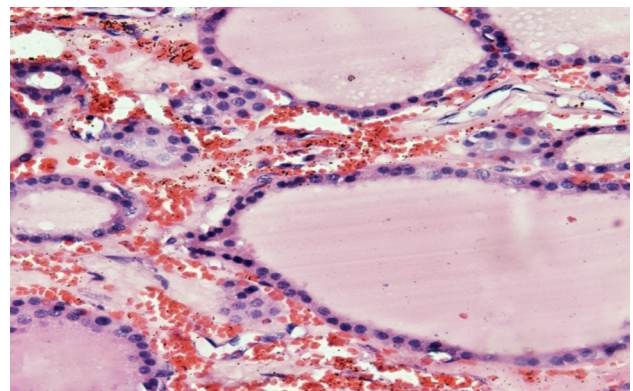


Figure 3b. Struma ovarii (H&E, 100×).

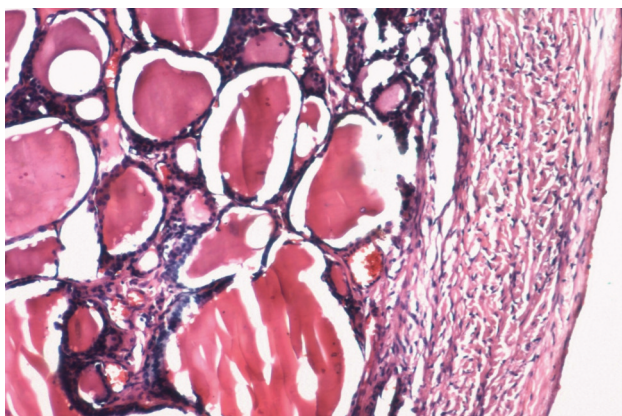


Figure 4A. PAS positive colloid in follicles (40×).

mature thyroid follicles filled with eosinophilic colloid and lined by cuboidal or columnar cells with uniform rounded nuclei. Degenerative changes such as fibrosis, calcification and aggregates of hemosiderin-laden macrophages may be present.¹⁴ Histopathology is the confirmatory tool of diagnosis in all cases. In difficult cases, immunohistochemical stains for thyroid transcription factor and/or thyroglobulin may be decisive in establishing the thyroid nature of the epithelial lining.⁷ Our institute is primarily a surgical center without molecular methods of diagnosis. Hence, this study has been mainly restricted to immunohistochemical analysis. Extensive grossing is required to rule out any other component like neural, cartilage, or skin with adnexal tissue before labelling any ovarian tumor as a monodermal teratoma.¹⁵

Malignant transformation of the struma ovarii is rare and accounts for 0.01% of all ovarian tumors. Struma ovarii may also harbor histological changes identical to thyroid adenomas or be admixed with a carcinoid (strumal carcinoid). The morphology of the thyroid tumors within the

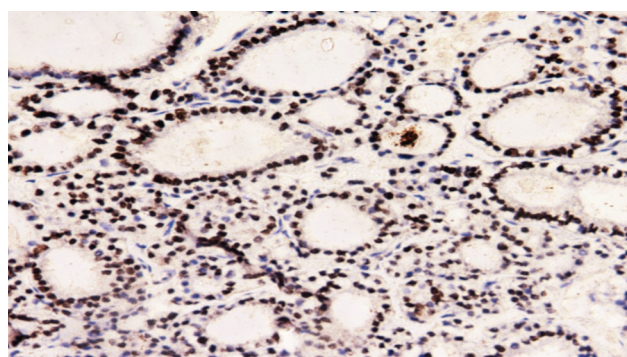


Figure 5A. On IHC, TTF-1 positive (40×).

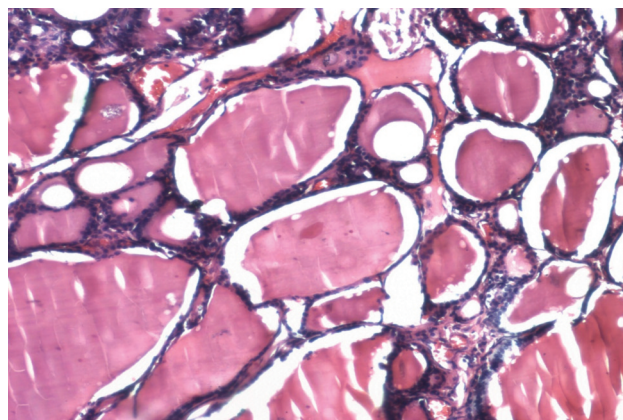


Figure 4B. PAS positive colloid in follicles (40×).

struma is similar to the ectopic thyroid. The thyroid tissue undergoes malignant change predominantly to a papillary carcinoma.⁸

Serum tumor markers are useful in determining potential malignancy. CA 125 is a classical tumor marker effective in the surveillance of treated epithelial ovarian cancers. However, CA 125 has poor specificity in the diagnosis of epithelial ovarian cancers, as its elevation may also be associated with other malignancies and benign, physiological states that include pregnancy, endometriosis, and menstruation.¹⁶ Elevated CA 125 accompanied by Meigs' syndrome is a rare clinical condition that has been reported in only 27 cases. The exact reason for the elevated CA 125 in Meigs' and pseudo Meigs' syndrome remains unclear. A possible explanation proposed by Mui et al. is the irritation and subsequent inflammation of pleura and peritoneum produced by the presence of free fluid in these spaces.⁵

Definitive therapy depends on the extent of the disease and future childbearing wishes of the patient. Simple salpingo-oophorectomy is the therapy of choice for the vast majority of patients,

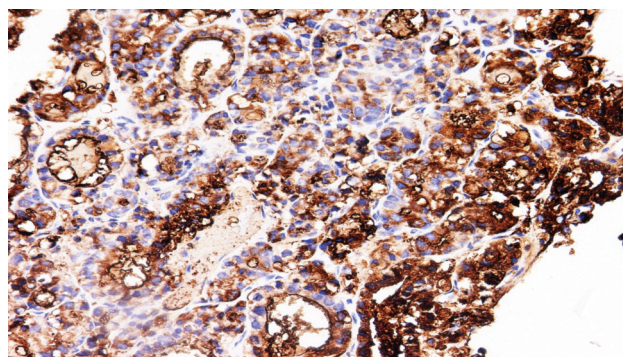


Figure 5B. On IHC, thyroglobulin positive (40×).

since most cases are unilateral and benign. Total hysterectomy with bilateral salpingo-oophorectomy is indicated for bilateral tumors or in postmenopausal patients. In cases of malignant transformation, a combination of complete tumor resection, total thyroidectomy, and adjuvant ablation is usually mandatory since evidence exists that struma ovarii behaves like its thyroid counterparts. Careful postoperative monitoring for any signs of hypothyroidism is required, as it may be the only functional thyroid tissue in the patient.¹⁷ Although elevated levels of thyroglobulin have been demonstrated in both benign and malignant struma ovarii, after surgery it can be an important tumor marker predictive of recurrence. An increase in serum thyroglobulin levels should alert the clinician to disease recurrence. In case of a definite preoperative diagnosis, laparoscopic surgery can be implemented, but the surgeon must be careful not to rupture the tumor intra-abdominally in order to avoid dissemination, which could lead to malignancy. Laparoscopic approach involves either oophorectomy, which is recommended, or enucleation of the tumor as a fertility-preserving procedure. When laparoscopy is performed and malignant struma ovarii is confirmed postoperatively, a second staging procedure should be performed either as a laparotomy or laparoscopically. Prognosis is good after treatment.¹⁸

A postmenopausal female that presents with a pelvic mass, ascites, pleural effusions, and elevated CA 125 levels generally is highly indicative of a malignant process. A number of unique features have been identified in this patient. The rapid onset of symptoms, sinister ultrasound findings (marked ascites, a large solid, cystic mass in the left adnexa), and a significantly elevated CA 125 level were highly suspicious for an ovarian malignancy. Although rare, struma ovarii accompanied by pseudo Meigs' syndrome and elevated serum CA 125 should be considered in the differential diagnosis of ovarian neoplasms.

Conclusion

Although it has been more than 100 years

since the first description of struma ovarii, a number of aspects remain enigmatic. This report emphasizes that there are benign gynecological conditions that may show clinical, ultrasonographic, and biochemical signs suggestive of malignancy. The association of pseudo-Meigs' syndrome with struma ovarii is very rare. We seek to emphasize by this report that, despite its rarity, a differential diagnosis of struma ovarii should be included for an ovarian mass accompanied by pseudo Meigs' syndrome and elevated serum CA 125 levels.

Conflict of Interest

No conflict of interest is declared.

References

1. Szyfelbein WM, Young RH, Scully RE. Struma ovarii simulating ovarian tumors of other types. A report of 30 cases. *Am J Surg Pathol.* 1995;19(1):21-9.
2. Jiang W, Lu X, Zhu ZL, Liu XS, Xu CJ. Struma ovarii associated with pseudo-Meigs' syndrome and elevated serum CA 125: a case report and review of the literature. *J Ovarian Res.* 2010;3:18.
3. Zakhem A, Aftimos G, Kreidy R, Salem P. Malignant struma ovarii: report of two cases and selected review of the literature. *J Surg Oncol.* 1990;43(1):61-5.
4. Scully RE, Young RH, Clement PB. Tumors of the ovary, maldeveloped gonads, fallopian tube, and broad ligament. *Atlas of tumor pathology.* 3(23); Washington, DC Armed Forces Institute of Pathology.
5. Mui MP, Tam KF, Tam FK, Ngan HY. Coexistence of struma ovarii with marked ascites and elevated CA-125 levels: case report and literature review. *Arch Gynecol Obstet.* 2009;279(5):753-7.
6. Matsumoto F, Yoshioka H, Hamada T, Ishida O, Noda K. Struma ovarii: CT and MR findings. *J Comput Assist Tomogr.* 1990;14(2):310-2.
7. McCluggage WG, Young RH. Immunohistochemistry as a diagnostic aid in the evaluation of ovarian tumors. *Semin Diagn Pathol.* 2005;22(1):3-32.
8. Papanikolaou Ch, Fortounis K, Ainalis S, Biba K, Papanikolaou A, Hatzitheoxaris G. Pseudo-Meigs syndrome: a case report. *The Internet Journal of Pathology.* 2005;4(2):1-5.
9. Loizzi V, Cormio G, Resta L, Fattizzi N, Vicino M, Selvaggi L. Pseudo-Meigs syndrome and elevated CA125 associated with struma ovarii. *Gynecol Oncol.* 2005;97(1):282-4.
10. Amant F, Gabriel C, Timmerman D, Vergote I. Pseudo-Meigs' syndrome caused by a hydropic degenerating uterine leiomyoma with elevated CA 125. *Gynecol*

- Oncol.* 2001;83(1):153-7.
11. Roth LM, Talerma A. The enigma of struma ovarii. *Pathology.* 2007;39(1):139-46.
 12. Plaut A. Ovarian struma: A morphologic, pharmacologic, and biologic examination. *Am J Obstet Gynecol.* 1933;25:351-60.
 13. Rutgers JL, Scully RE. Functioning ovarian tumors with peripheral steroid cell proliferation: a report of twenty-four cases. *Int J Gynecol Pathol.* 1986;5(4):319-37.
 14. Zannoni GF, Gallotta V, Legge F, Tarquini E, Scambia G, Ferrandina G. Pseudo-Meigs' syndrome associated with malignant struma ovarii: a case report. *Gynecol Oncol.* 2004;94(1):226-8.
 15. Rana V, Srinivas V, Bandyopadhyay S, Ghosh SK, Singh Y. Bilateral benign non functional struma ovarii with Pseudo-Meigs' syndrome. *Indian J Pathol Microbiol.* 2009;52(1):94-6.
 16. Jacobs I, Bast RC Jr. The CA 125 tumour-associated antigen: a review of the literature. *Hum Reprod.* 1989;4(1):1-12.
 17. Dardik RB, Dardik M, Westra W, Montz FJ. Malignant struma ovarii: two case reports and a review of the literature. *Gynecol Oncol.* 1999;73(3):447-51.
 18. Nurliza Binti Md Nor, Kusumoto T, Inoue S, Nakamura K, Seki N, Hongo A, et al. Three cases of struma ovarii underwent laparoscopic surgery with definite preoperative diagnosis. *Acta Med Okayama.* 2013;67(3):191-5.