

Case Report

Middle East Journal of Cancer; April 2018; 9(2): 159-164

Eosinophil-rich Variant of Follicular Dendritic Sarcoma of Cervical Lymph Node: An Extremely Rare Entity

Rajeev Sen*, Sumiti Gupta*, Shivani Malik**, Sunita Singh*, Rajnish Kalra*, Vipul Bansal**

*Department of Pathology, Pt B D Sharma UHS, Rohtak, Haryana, India

**Department of Radiotherapy, Pt B D Sharma UHS, Rohtak, Haryana, India

Abstract

Follicular dendritic cell neoplasms are extremely rare. Information regarding the accurate treatment and prognosis is limited owing to their rarity; thus, this tumor encompasses a domain to be brought into focus. Clinical and pathological diagnoses warrant a high index of suspicion as this entity is not considered in routine clinical practice. Histopathologically it mimics various other neoplasms which lead to higher chances of misdiagnosis at initial evaluation. Use of follicular dendritic cell immunohistochemical markers CD 21 and CD 35 helps in rendering a definitive diagnosis.

Keywords: Follicular, Dendritic sarcoma, Eosinophil

Introduction

Follicular dendritic cell sarcoma is an uncommon tumor of antigen presenting cells in B cell follicles of lymphoid organs. Follicular dendritic cells (FDCs) or dendritic reticulum cells are located in the germinal center and play an important role in germinal center reaction regulation. A hyperplastic proliferation of these FDCs can be found in some reactive, as well as neoplastic conditions of lymphatic tissues that include lymphofollicular hyperplasia, and different lymphomas of non-Hodgkin's and Hodgkin's types.¹ Follicular dendritic cell tumor is a

rare neoplasm that presents in both sexes and mainly in adults.² The existence of a primary neoplasm of the FDCs was first recognized in 1986 by Monda et al.³ In recent years, there has been an increasing interest in this specific type of neoplasm due to the availability of specific antibodies that confirm the follicular dendritic cell lineage.

Case Report

A 57-year-old male presented with a progressively enlarging, painless, right cervical swelling for 1.5 years. On examination, the patient had a hard, immobile, non-tender right

♦Corresponding Author:
Shivani Malik, MD, DNB
Department of Pathology, Pt B
D Sharma UHS, Rohtak,
Haryana, India
Tel: +9992935860
Email: shivani.dr04@gmail.com



Received: May 6, 2017; Accepted: October 14, 2017

cervical mass (11×11×8 cm) that extended to the postauricular region. A CT scan revealed a tumor mass that encased the major vessels on the right side of the neck (Figure 1). A fine needle aspiration of the mass was performed. The smears revealed numerous coalescent clusters of spindle cells that assumed an epithelioid appearance. However, Ziehl-Neelsen staining for AFB with 20% H₂SO₄ was non-contributory. A diagnosis of granulomatous inflammation was rendered. The patient was prescribed anti-tubercular drugs with no observed response after 2 months. A Tru-Cut biopsy of the mass revealed fibrocollagenous tissue infiltrated by chronic inflammatory cells and did not prove useful. The patient underwent an excision biopsy and an encapsulated mass of 3.5×2.5×1 cm was received by the Pathology Department. The examined microsections revealed nodular proliferation of dendritic spindle shaped cells obscured by a variable proportion of lymphocytes and numerous eosinophils. The large number of eosinophils obscured the underlying cell morphology. Based on histomorphology, the differential diagnosis included follicular dendritic cell tumor, undifferentiated carcinoma, thymic carcinoma, and nodular sclerosis type Hodgkin's lymphoma (Figures 2, 3). Various immunohistochemical stains applied to reach a definitive diagnosis included vimentin, CD 21, CD 35, CD 10, CD 20, CD 5, CD 15, CD 30, desmin, smooth muscle actin, S-100, and cytokeratin. The tumor

cells revealed strong positivity for vimentin and CD 35, (Figures 4 A, B) and negative expressions of cytokeratin, CD 15, CD 30, desmin, SMA, and S-100. CD 5 and CD 20 were observed in interspersed lymphoid cells. A final diagnosis of eosinophil rich variant of follicular dendritic tumor was given based on immunohistochemistry. Surgery could not be performed as the tumor encased major vessels of the neck. The patient received involved field radiation therapy at 20 gray/5 fractions in 5 days which resulted in significant tumor reduction. Subsequently, he received 6 cycles of a cyclophosphamide, doxorubicin, vincristine, and prednisone-based chemotherapy regimen, each cycle at three weeks interval. The patient had no evidence of disease at 20-month regular follow up.

Discussion

A follicular dendritic cell tumor is an extremely rare neoplasm of nodal and extranodal tissue often misdiagnosed on initial evaluation, which leads to delay in appropriate treatment. Wang et al.⁴ reported the lymph node as the most common site - involving chiefly cervical, axillary, and mediastinal lymph nodes. The lymphoid tissue is present in extranodal sites in an organized constitutive or acquired form. Follicular dendritic neoplasms have been documented throughout the body in the pancreas, tonsils, peritoneum, palate, pharynx, stomach, small intestine, colon,

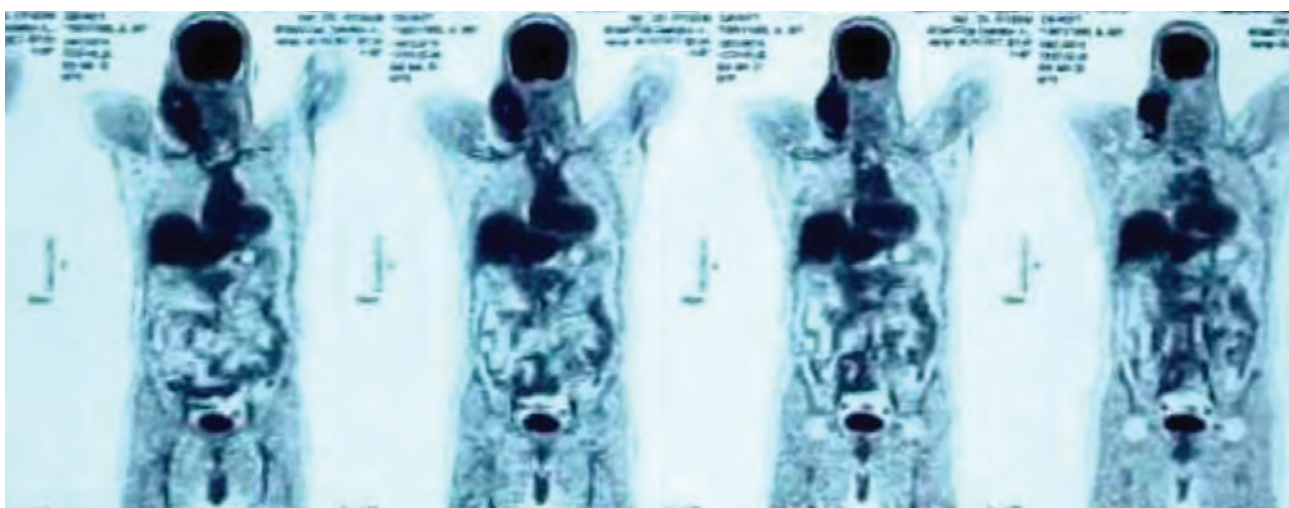


Figure 1. CT scan shows a mass in the right cervical region.

mesentery, thyroid, liver, and spleen. Castleman's disease has been found in association with FDC sarcomas (FDCS) in a minority of cases, which suggests that it may represent a precursor lesion.⁵ A possible role for p53 in the transformation process has been proposed.⁶ There were cytogenetic abnormalities described in one case of FDCS in the spleen, which displayed multiple clonal unbalanced chromosomal translocations and loss of Xp.⁷

The clinical presentation of FDCS includes a painless mass. It is important that medical professionals are aware of these tumors. Medical professionals should have the capability to recognize these tumors as they show clinical and histological similarities to a wide range of other tumors and tumor-like lesions. Usually, this entity is not considered in routine clinical practice and can be missed on immunohistochemical studies,

as the markers for FDCs are not included among the routine antibody panel for the investigation of poorly-differentiated neoplasms.

The most common histological feature includes presence of oval to spindle cells with elongated nuclei, delicate, dispersed chromatin, and pale eosinophilic cytoplasm. Presence of multinucleated giant cells, lymphocytes and plasma cells are other histological findings. We have presented a case of follicular dendritic tumor of cervical lymph node in which the tumor showed heavy infiltration obscured by numerous eosinophils, which gave it the appearance of an inflammatory pseudotumor. Close scrutiny of the tissue among the eosinophils revealed scattered atypical spindle cells with indistinct cell borders, large vesicular nuclei, and distinct nucleoli. Immunostain analysis of the atypical cells showed they were positive for FDC markers CD21 and

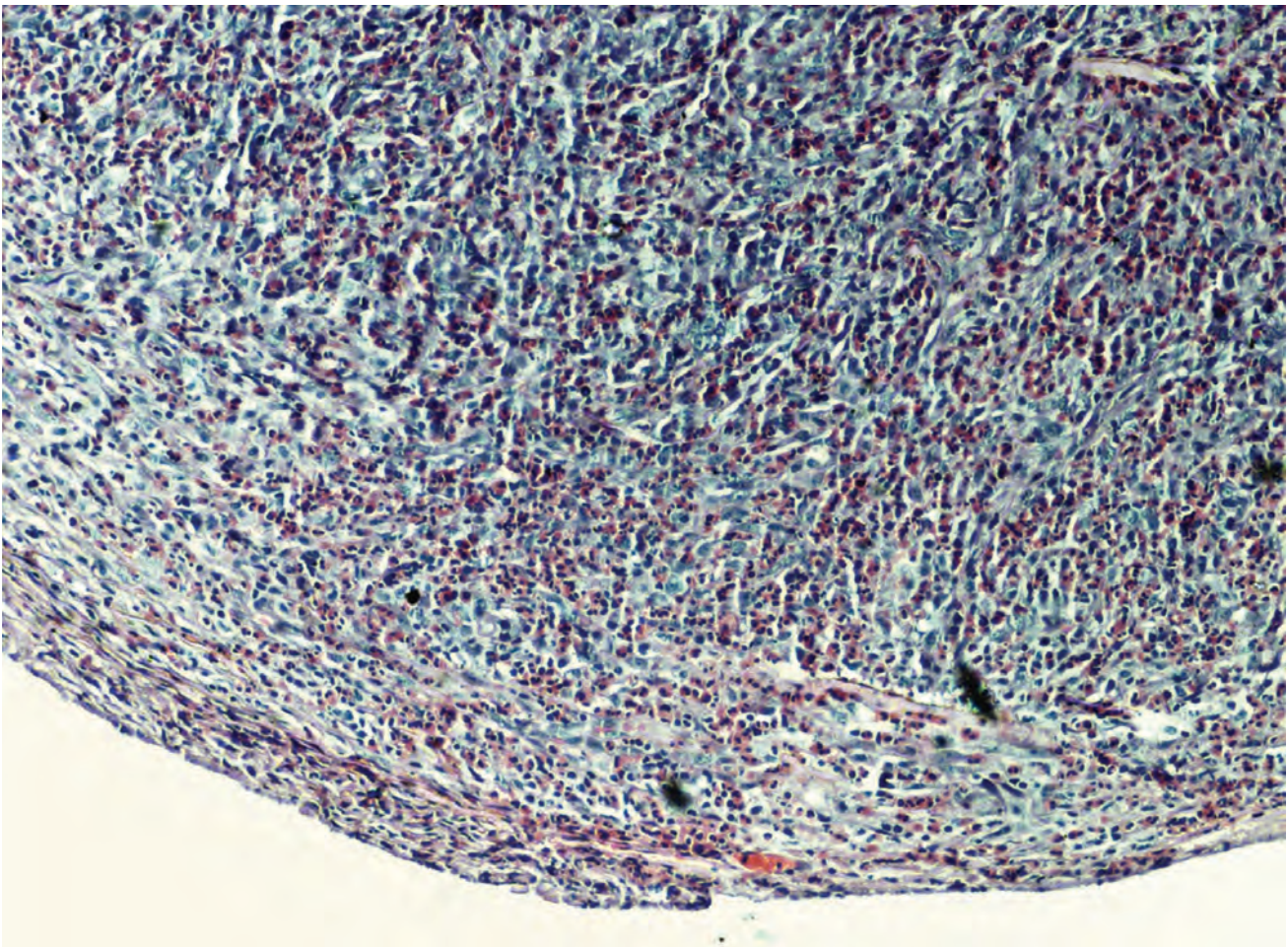


Figure 2. Shows an encapsulated tissue with large numbers of eosinophils which have obscured the underlying cell morphology. (Magnification: 10×, H&E).

CD35. Li et al.⁸ reported 6 diagnostically challenging cases in which the neoplastic component was overshadowed by granulomas or eosinophils as was in our case. The presence of extensive coalescent epithelioid granulomas in 3 splenic tumors and 3 liver tumors raised the possibilities of an infective process or sarcoidosis. In another liver tumor, the massive infiltrate of eosinophils accompanied by geographic eosinophilic abscesses suggested parasitic infestation or a so-called eosinophilic granuloma of the liver. One of the cases showed concurrent involvement of the liver and spleen.⁸ The literature has suggested that follicular dendritic cell tumors may produce an inflammatory pseudotumor-like histological picture in the liver and spleen, which presents a diagnostic difficulty. The current case report documents a case of pseudotumor-like eosinophil rich variant of a follicular dendritic cell tumor in a cervical lymph node.

This neoplasm, despite its rarity, is also under recognized. However, currently, the availability of immunohistochemical markers specific for FDCs has increased this tumor recognition. Although CD21 and CD35 are the most widely used markers, other useful positive non-specific markers include vimentin, CD23, CD68, S-100 protein, fascin, Ki-M4p, and Ki-FDC1. Follicular dendritic cell tumor typically does not express CD1a, desmin, and CD45 which allows for its differential diagnosis with interdigitating dendritic cell tumors, Langerhans cell tumors, and histiocytic and lymphoid neoplasms.

Follicular dendritic cell tumor has the potential for recurrence and metastasis. Cases with metastases to the lungs, chest wall, lymph nodes, liver, and brain have been documented. Treatment modalities include surgical intervention in addition to radiotherapy and chemotherapy.

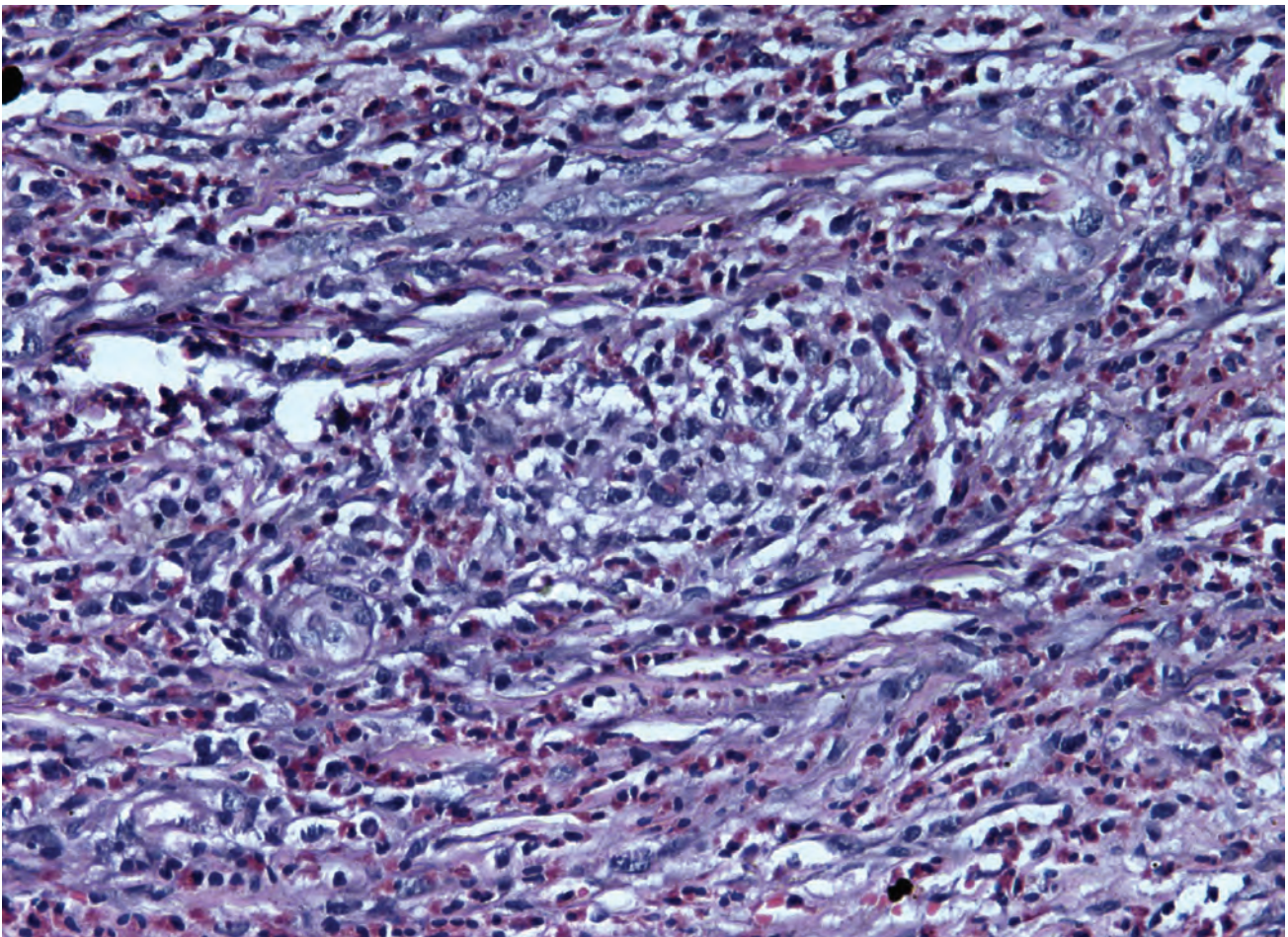


Figure 3. High power view shows large numbers of eosinophils along with spindle cells. (Magnification: 40×, H & E).

Conflict of interest

No conflict of interest is declared.

References

1. Perez-Ordóñez B, Rosai J. Follicular dendritic cell tumor: review of the entity. *Semin Diagn Pathol.* 1998;15(2):144-54.
2. Biddle DA, Ro JY, Yoon GS, Yong YW, Ayala AG, Ordóñez NG, et al. Extranodal follicular dendritic cell sarcoma of the head and neck region: three new cases, with a review of the literature. *Mod Pathol.* 2002;15(1):50-8.
3. Monda L, Warnke R, Rosai J. A primary lymph node malignancy with features suggestive of dendritic reticulum cell differentiation. A report of 4 cases. *Am J Pathol.* 1986;122(3):562-72.
4. Wang H, Su Z, Hu Z, Wen J, Liu B. Follicular dendritic cell sarcoma: a report of six cases and a review of the Chinese literature. *Diagn Pathol.* 2010;5:67.
5. Chan JK, Tsang WY, Ng CS. Follicular dendritic cell tumor and vascular neoplasm complicating hyaline-vascular Castleman's disease. *Am J Surg Pathol.* 1994;18(5):517-25.
6. Chan AC, Chan KW, Chan JK, Au WY, Ho WK, Ng WM. Development of follicular dendritic cell sarcoma in hyaline-vascular Castleman's disease of the nasopharynx: tracing its evolution by sequential

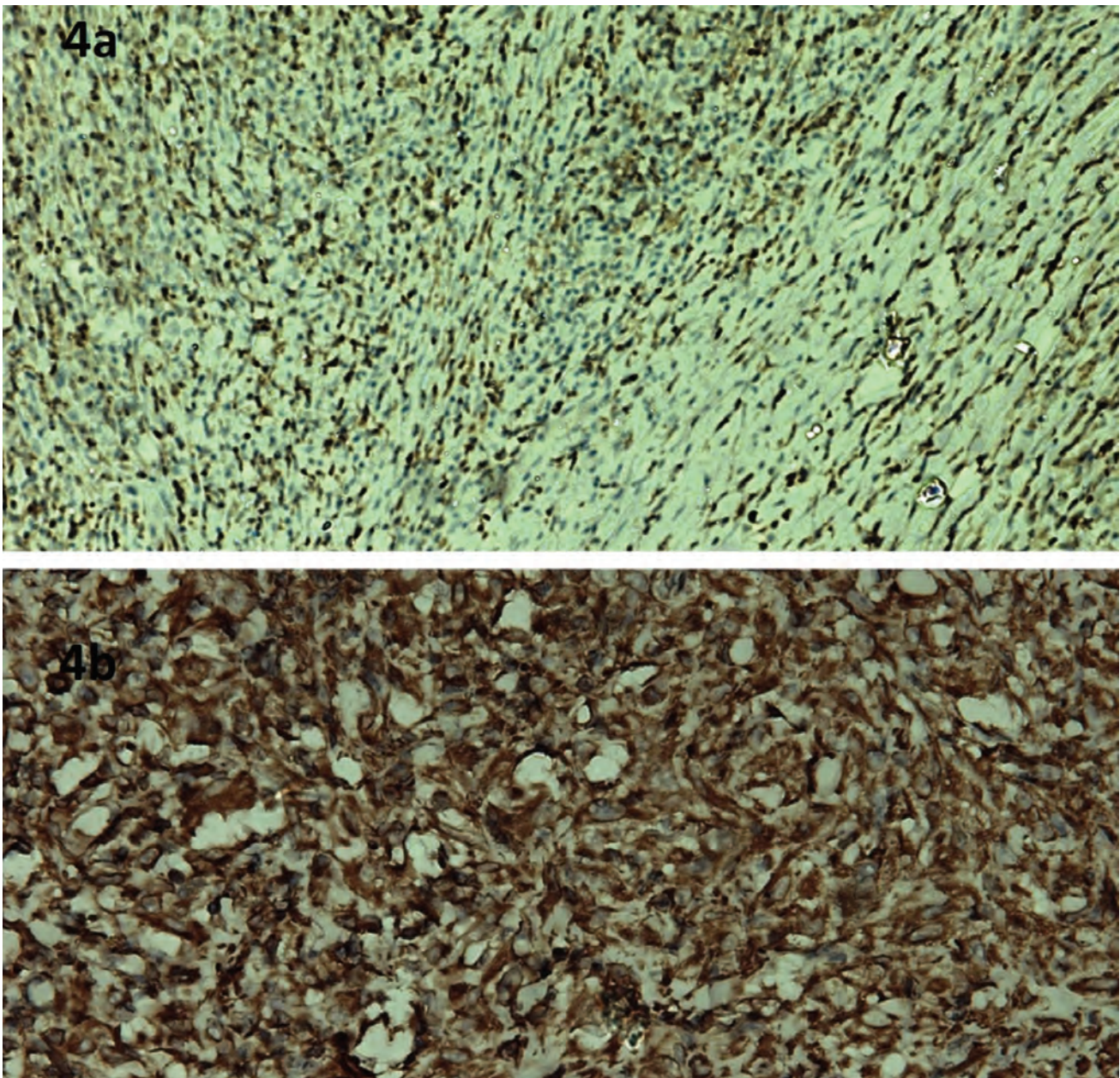


Figure 4. (A) Diffuse vimentin positivity in spindle shaped cells at 20× magnification. (B) CD 35 positivity in spindle shaped cells at 10× magnification.

- biopsies. *Histopathology*. 2001;38(6):510-8.
7. Sander B, Middel P, Gunawan B, Schulten HJ, Baum F, Golas MM, et al. Follicular dendritic cell sarcoma of the spleen. *Hum Pathol*. 2007;38(4):668-72.
 8. Li XQ, Cheuk W, Lam PW, Wang Z, Loong F, Yeong ML, et al. Inflammatory pseudotumor-like follicular dendritic cell tumor of liver and spleen: granulomatous and eosinophil-rich variants mimicking inflammatory or infective lesions. *Am J Surg Pathol*. 2014;38(5):646-53.