

## Simultaneous Occurrence of Advanced Neuroblastoma and Acute Lymphoblastic Leukemia: A Case Report

Mohammad Pedram\*<sup>†</sup>, Majid Vafaie\*\*<sup>†</sup>, Kaveh Jaseb\*\*<sup>†</sup>, Kiavash Fekri\*\*<sup>†</sup>  
Sabahat Haghi\*\*<sup>†</sup>

\*Thalassemia & Hemoglobinopathy Research Center, Ahvaz Jondishapur University of Medical Sciences, Ahvaz, Iran

\*\*Shafa Hospital, Ahvaz Jondishapur University of Medical Sciences, Ahvaz, Iran

### Abstract

Neuroblastoma is the most common extracranial solid tumor in children. The co-occurrence of neuroblastoma and acute lymphoblastic leukemia is rare. We report a rare case of advanced-stage neuroblastoma in a 3.5-year-old girl that was accompanied by acute lymphoblastic leukemia following treatment. Her leukemia may have been due to chemotherapy (secondary leukemia) or may have been de novo.

**Keywords:** Neuroblastoma, Secondary leukemia, Acute lymphoblastic leukemia

### Introduction

Secondary leukemia, a well-recognized late complication of antineoplastic therapy, typically manifests as acute myeloid leukemia (AML).<sup>1</sup> Secondary acute lymphoblastic leukemia (SALL), a rare disease, is defined as acute lymphoblastic leukemia (ALL) that occurs after another malignancy irrespective of whether patients have received prior therapy. Therapy-related AML, or secondary leukemia, is a well-recognized entity included in the World Health Organization classification.<sup>2</sup> In one recent review, ALL represented only 5% to 10% of secondary leukemias.<sup>3</sup>

Here we present a case of neuroblastoma associated with ALL.

### Case Report

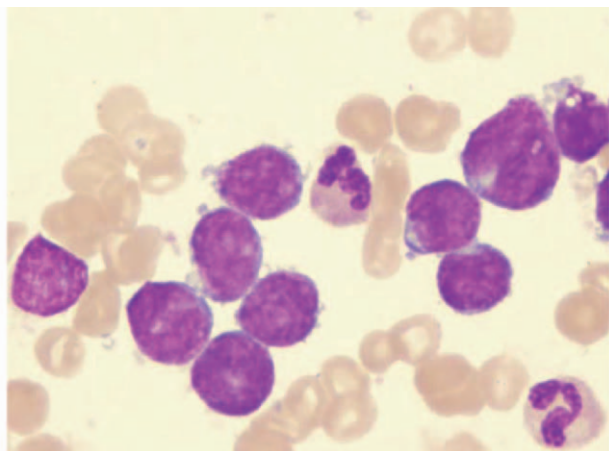
In December 2008, a 3.5-year-old girl was admitted to our hospital due to constipation and abdominal bulging. At that time abdominal and pelvic sonography could not evaluate the upper pole of the left kidney due to the presence of a heterogeneous mixed-echo soft tissue structure measuring 86×65 mm. The computed tomography scan showed a massive noncalcified tumor in the upper pole of the left kidney that crossed the midline.

A biopsy was performed and the

<sup>†</sup>Corresponding Author:  
Mohammad Pedram, MD,  
Thalassemia & Hemoglobinopathy  
Research Center, Shafa  
Hospital, Ahvaz Jondishapur  
University of Medical Sciences,  
Ahvaz, Iran  
Tel: +98-916 313 2796  
Email:  
m\_pedram\_2007@yahoo.com

pathological diagnosis was undifferentiated neuroblastoma with poor stroma, mitosis and karyorrhexis index MKI >200, unfavorable Shimada histopathology and N-*myc* amplification (22 copies). There was lymph node invasion by neoplastic cells. Unfortunately, no computed tomography images were available at the time of writing. However, the diagnosis of neuroblastoma appeared to be likely because of immunohistochemical studies and imaging findings at the time of diagnosis.

Immunohistochemical findings were positive for synaptophysin, neuro-specific esterase and chromogranin A. The bone marrow was normal. Because of these findings, she was considered to be at high risk, and chemotherapy was initiated. The chemotherapy regimen consisted of vincristin, etoposide, cisplatin and cyclophosphamide. Second-look surgery was done after five courses of chemotherapy, which showed good response. However, a meta-iodobenzylguanidine scan after treatment was completed revealed multiple abnormal collections of radioisotope in the right supra-renal fossa that strongly suggested recurrent tumor. The patient subsequently received two courses of ifosfamide, carboplatin and etoposide and was referred to a bone marrow transplant center. Because of the lack of an appropriate donor, we initiated the CCG-3891 protocol (Children's Cancer Group protocol for high-risk neuroblastoma), which consisted of adriamycin, cyclophosphamide, cisplatin and etoposide for continued therapy.



**Figure 1.** Bone marrow aspirate showing many lymphoblasts with a high nuclear / cytoplasmic ratio (Wright-Giemsa staining)

During a routine follow-up visit in April 2010, she was found to be febrile and pale. Laboratory analyses showed a leukocyte count of  $7 \times 10^9 \mu/L$ , hemoglobin 4 gr/dL and platelet count  $6000 \times 10^9 \mu/L$ . Peripheral blood smear and bone marrow aspirate showed many lymphoblasts with a high nuclear/cytoplasmic ratio, compatible with ALL (L1 morphology) (Fig. 1). Immunophenotype was consistent with B- precursor ALL positive for CD19 (79%), HLA-DR (80%) and CD10 (78%). The child was treated with combination chemotherapy that consisted of adriamycin, vincristin, cyclophosphamide, prednisolone, L-asparaginase and intrathecal therapy. On May 10, 2010, during chemotherapy, the patient died from overwhelming sepsis. She received a total dose of etoposide of about 3000 mg/ m<sup>2</sup>.

## Discussion

Neuroblastoma, an embryonal tumor, is the most common and deadly solid tumor of childhood.<sup>4-6,12</sup> These tumors have a heterogeneous clinical presentation and course.<sup>4-6,12</sup> Some tumors progress rapidly to a fatal outcome, and in other instances the tumors may regress spontaneously in infants.<sup>4-6,12</sup> The treatment modalities for neuroblastoma are surgery, chemotherapy and radiotherapy.<sup>4-6,10-13</sup> Chemotherapy is the predominant modality of management in intermediate and high-risk neuroblastoma, and is also used in low-risk patients with symptomatic involvement of vital organs.<sup>5,6</sup> In children with high-risk neuroblastoma, the long-term survival rate is less than 40% even with multimodal intensive therapy, including hematopoietic stem cell transplantation.<sup>4,5,10,12</sup>

Many treatment protocols are available for induction chemotherapy lasting 5 to 7 months.<sup>5</sup> One of the induction chemotherapy regimens currently in use consists of cyclophosphamide, etoposide, adriamycin and cisplatin, which are the active agents in the CCG-3891 regimen.<sup>4,5</sup> The intensity of therapy required to successfully treat high-risk neuroblastoma necessitates careful

consideration of the possible serious late sequelae,<sup>12</sup> and we recommend that bone marrow aspiration be performed periodically in these patients.

Secondary myelodysplasia and AML have been associated with certain chemotherapeutic agents such as alkylating agents and topoisomerase II inhibitors.<sup>4,5</sup> The pathogenesis for secondary ALL are not well defined. However, the development of secondary ALL is related to DNA topoisomerase II inhibitors. Alkylating agents and topoisomerase II inhibitors have been associated with secondary AML.<sup>4-6,11-13</sup> In most patients treated with alkylating agents, secondary AML is preceded by myelodysplastic syndrome (MDS) and is correlated with the total dose of alkylating agents, with a latency period of 3.5 to 5.5 years.<sup>4,5</sup> Topoisomerase II inhibitor-associated leukemia does not have an MDS phase and presents acutely.<sup>4,5,9</sup>

Providing appropriate health care for cancer survivors is emerging as one of the major challenges in medicine.<sup>4</sup> Currently the overall five year survival rate in childhood cancers is 75%–80%.<sup>4,5</sup> Late effects are defined as any physical or psychological outcome that develops or persists beyond 5 years from the diagnosis of cancer. Up to two thirds of childhood cancer survivors are likely to experience at least one late effect, with one fourth of all survivors experiencing severe or life-threatening side effects.<sup>4,5</sup> Perhaps the most common serious late adverse effect is the occurrence of secondary cancers in patients successfully cured of a first malignancy. The risk appears to be cumulative, increasing by about 0.5% per year and resulting in an approximately 12% incidence 25 years after treatment.

Childhood cancer survivors have 10 to 20 times the lifetime risk of second malignant neoplasms compared with age-matched controls. Secondary malignant neoplasms are the most common cause of death in long-time survivors after recurrence of the primary cancer.<sup>5</sup> Shinsaku et al. reported one case of ALL and one case of mediastinal lymphoblastic lymphoma that

developed after treatment for neuroblastoma. Additionally, Telma et al. reported 4-year-old boy with a diagnosis of stage IV neuroblastoma who was treated with six cycles of cyclophosphamide, doxorubicin, cisplatin and etoposide for 12 months. The patient attained partial remission and presented with a diagnosis of active myelomonocytic leukemia, which was confirmed by immunophenotyping.<sup>8</sup> After 2 months of treatment, the child died with both malignancies active simultaneously.<sup>8</sup>

In a recent review of secondary ALL by Hunger et al., two out of three patients with neuroblastoma had received epipodophyllotoxins. Importantly, one of the two patients tested had the t(4;11)(q21;q23) chromosomal abnormality.<sup>3</sup> Pui et al. identified three cases of secondary ALL with t(4;11) who had received epipodophyllotoxins for their primary malignancy.<sup>9</sup> The prognosis of secondary ALL appears to be dismal<sup>1,4,5</sup> and very few long-term survivors have been reported.<sup>5</sup> The pathogenesis of secondary lymphoid malignancy in patients with neuroblastoma is uncertain.<sup>1</sup> Allogenic hematopoietic stem cell transplantation is the treatment of choice.<sup>4,5</sup> Our case is unique because SALL is a rare event. The cause of ALL in our case was uncertain and might have been related to previous treatment with epipodophyllotoxins and cyclophosphamide or host susceptibility, or may have been a chance occurrence.

## Conclusion

According to earlier studies, a neoplasm appearing at least 2 years after a first tumor is defined as secondary.<sup>4-6,11-16</sup> So the occurrence of two tumors in interval less than 2 years can be regarded as simultaneous presence. In our patient, ALL was diagnosed about 14 months after the onset of neuroblastoma. Compared to other cases in the literature, the cause of SALL in our patient is less certain and may be related to previous treatment with epipodophyllotoxins and cyclophosphamide, or the presence of the t abnormality.<sup>4,11</sup> Unfortunately, no cytogenetic study was done in our patient. It should be emphasized that the

CCG-3891 protocol includes etoposide and cyclophosphamide, which are associated with leukemogenic effects, and the most common therapy-related leukemia is AML.<sup>4-6</sup>

## References

1. Imashuku S, Hibi S, Kosaka K, Tabata Y, Naya M, Honjo M, et al. Secondary lymphoid malignancy in two children with neuroblastoma. *Med Pediatr Oncol* 1996;27:54-6.
2. Harris NL, Jaffe ES, Diebold J, Flandrin G, Muller-Hermelink HK, Vardiman J, et al. World Health Organization classification of neoplastic disease of hematopoietic and lymphoid tissue: Report of Clinical Advisory Committee meeting – Airlic House, Virginia, November 1997. *J Clin Oncol* 1999;17:3835-49.
3. Hunger SP, Sklar J, Link MP. Acute lymphoblastic leukemia occurring as a second malignant neoplasm in childhood: Report of three cases and review of the literature. *J Clin Oncol* 1992;10:156-63.
4. Bnatia S, Blatt J, Meadows AT. Late effects of childhood cancer and its treatment. In: Pizzo PA, Poplak DG, eds. Principles and practice of pediatric oncology, 5th ed. Philadelphia: Lippincott, Williams & Wilkins, 2006:1490-514.
5. Render A MD. Evaluation, investigation and management of late effects of child hood cancer. In: Philip Lanzkowsky Manual of Pediatric Hematology and Oncology. 4th ed. Philadelphia: Lippincott, Williams & Wilkins, 2005:749-74.
6. Bleyer A. Principles of treatment. In: Behrman RE, Kligman RM, Jenson HB, eds. Nelson Textbook of Pediatrics, 18th ed. Philadelphia: WB Sanders, 2007:2115-6.
7. Santos–Machado TM, Zerbini M, Cristofani LM, Azevedo PM, Almeida MT, Maluf PT JR, et al. Simultaneous occurrence of advanced neuroblastoma and acute myeloid leukemia. *Pediatr Hematol Oncol* 2001;18(2):129-35.
8. Pui C-H. Acute leukemia with the T (4:11) (q21;q23). *Leuk Lymphoma* 1992;7:173-9.
9. Leone G, Pagano L, Ben-Yehuda D, Voso MT. Therapy related leukemia and myelodysplasia: Susceptibility and incidence. *Hematology J* 2007;92(10):1389-98.
10. Weiss B, Vora A, Huberty J, Hawkins RA, Matthay K K. Secondary myelodysplastic syndrome and leukemia following I-metaiodobenzylguanidin therapy for relapsed neuroblastoma. *J Pediatr Hematol Oncol* 2003;25(7):543-7.
11. Alcasabas P, Dettore DO, Ozgonenel B, Bhambhani K, Rauindranath Y, Savasn S. Vacuolated neuroblastoma cells mimicking FAB L3 lymphoblastic in bone marrow aspirates. Brief Report. *Pediatr Blood Cancer* 2007 Feb;48(2):227-9.
12. Hiyama E, Kamei N, Kamimatsu A. Molecular markers in neuroblastoma. *Iranian journal of blood and cancer* 2010;2(2):49-59.
13. Uderzo C, Rajnoldi AC, Schirò R, di Lelio A, Jankovic M, Conter V, et al. Neuroblastoma during acute lymphoblastic leukemia in remission. *Cancer* 1988 Oct 1;62(7):1359-63.