

# A Comparative Study of Automated Breast Ultrasound and Magnetic Resonance Imaging for Local Breast Cancer Staging in Malaysia

Marlina Tanty Ramli Hamid\*, MRad, Shamsiah Abdul Hamid\*, MRad,  
Nazimah Ab Mumin\*\*, PhD, Kartini Rahmat\*\*, MRad

\*Department of Radiology, Faculty of Medicine University, Teknologi MARA, Sungai Buloh, Selangor, Malaysia

\*\*Department of Biomedical Imaging, University Malaya Research Imaging Centre, Kuala Lumpur, Malaysia

Please cite this article as: Ramli Hamid MT, Abdul Hamid S, Ab Mumin N, Rahmat K. A comparative study of automated breast ultrasound and magnetic resonance imaging for local breast cancer staging in Malaysia. Middle East J Cancer. 2026; 17(2): 135-43. doi: 10.30476/mejc.2025.104422.2180.

Received: October 11, 2024;  
Accepted: February 15, 2025

## Abstract

**Background:** Accurate local staging is crucial for breast cancer treatment planning. This study aimed to compare the measurements of tumour size and distance from the nipple using automated breast ultrasound (ABUS) and magnetic resonance imaging (MRI) in a Malaysian cohort.

**Method:** A retrospective study was conducted on 36 women (49 breast lesions) who underwent both MRI and ABUS. Two breast radiologists independently assessed the anonymized images. Tumour size and distance from the nipple were measured and compared between modalities. Statistical analysis was performed using SPSS version 25.0, by employing student's t-test and kappa analysis, with a significance level of  $P < 0.001$ .

**Results:** The mean tumour size was 27.2 mm on ABUS and 28.3 mm on MRI, with a statistically significant difference ( $P < 0.001$ ). MRI also measured a significantly greater distance from the nipple ( $P < 0.001$ ). Inter-reader agreement was excellent for breast density assessment but not for lesion description.

**Conclusion:** ABUS and MRI demonstrate comparable performance in preoperative breast cancer staging, although MRI tends to give a larger tumour size and distance measurement from the nipple. Both modalities can contribute to local staging, aiding treatment decisions.

**Keywords:** Breast neoplasms, Magnetic resonance imaging, Neoplasm size, Neoplasm staging, Ultrasonography

### Corresponding Author:

Nazimah Ab Mumin, MD  
Department of Radiology,  
Faculty of Medicine University  
Teknologi MARA, Selangor,  
Malaysia  
Email: Nazimah\_mumin@uitm.edu.my



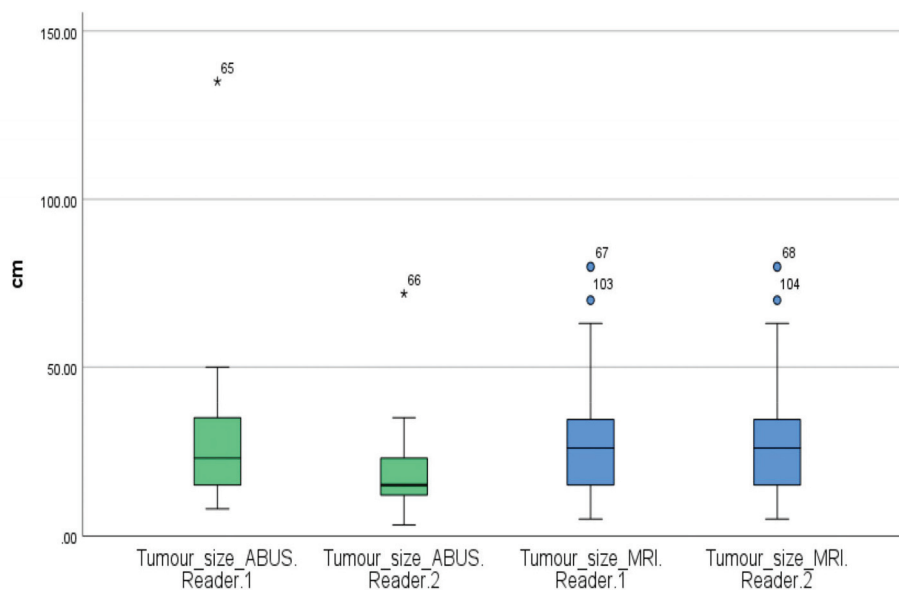
## Introduction

Breast cancer remains the most commonly diagnosed malignancy and the leading cause of cancer-related mortality among women worldwide, including in Malaysia.<sup>1, 2</sup> Early detection and accurate staging are crucial for optimizing treatment strategies and improving patient outcomes. The American Joint Committee on Cancer tumour-node-metastasis staging system provides a standardized framework for breast cancer staging, influencing surgical decisions, systemic therapy selection, and prognosis assessment Malaysia.<sup>3, 4</sup>

Mammography remains the cornerstone of breast cancer screening, but its sensitivity is significantly reduced in women with dense breasts, leading to an increased reliance on supplementary imaging techniques such as ultrasound and magnetic resonance imaging (MRI). MRI is widely regarded as the most sensitive imaging modality for detecting and staging breast cancer, particularly for assessing multifocal, multicentric and contralateral disease.<sup>5-8</sup> However, its high cost, limited accessibility and contraindications in certain patient populations necessitate the evaluation of alternative imaging modalities.

Automated breast ultrasound (ABUS) has emerged as a promising adjunct imaging technique that overcomes many limitations of handheld ultrasound, offering operator-independent, standardized, and reproducible imaging.<sup>9-12</sup> Previous studies suggest that ABUS can improve cancer detection in women with dense breasts and may have a role in preoperative tumour assessment.<sup>13-15</sup> However, limited data exist regarding its comparative accuracy against MRI in tumour size measurement and distance from the nipple, both of which are critical parameters in surgical planning and oncological decision-making.

This study aimed to evaluate the comparative performance of ABUS and MRI in local breast cancer staging within a Malaysian cohort. By analysing tumour size and lesion distance from the nipple, this study sought to determine whether ABUS can serve as a reliable alternative or complementary modality to MRI in breast cancer staging. A better understanding of comparative strengths and limitations of these modalities will contribute to more informed imaging selection in clinical practice, particularly in resource-limited settings.



**Figure 1.** Comparison of tumour size measurements in ABUS and MRI as assessed by Readers 1 and 2. The figure illustrates the differences in tumour size measurements between the two modalities, showing that MRI consistently reported larger tumour sizes compared with ABUS.

ABUS: Automated breast ultrasound; MRI: Magnetic resonance imaging

## Methodology

### Study Design

This study was performed in line with the principles of the Declaration of Helsinki. Approval was granted by the Ethics Committee of University Malaya Medical Centre (Medical Research Ethics ID: 2021927-10610) and the requirement for obtaining informed consent was waived due to the retrospective nature of the study.

This single-center retrospective study included treatment-naive breast cancer patients who underwent both MRI and ABUS between January 2020 till December 2021. Patient demographics, menopausal status, breast density, and histopathological findings were extracted from electronic medical records. The inclusion criteria were: female patients between 18-60 years with biopsy proven diagnosis of breast cancer. The exclusion criteria were: male patients, pregnant or lactating women, and those with breast implants.

### Imaging protocols

Imaging protocols for ABUS and MRI were standardized across all study participants to ensure consistency and reproducibility. ABUS examinations were performed on the same day as digital breast tomosynthesis and handheld ultrasound, with the patient lying supine. The

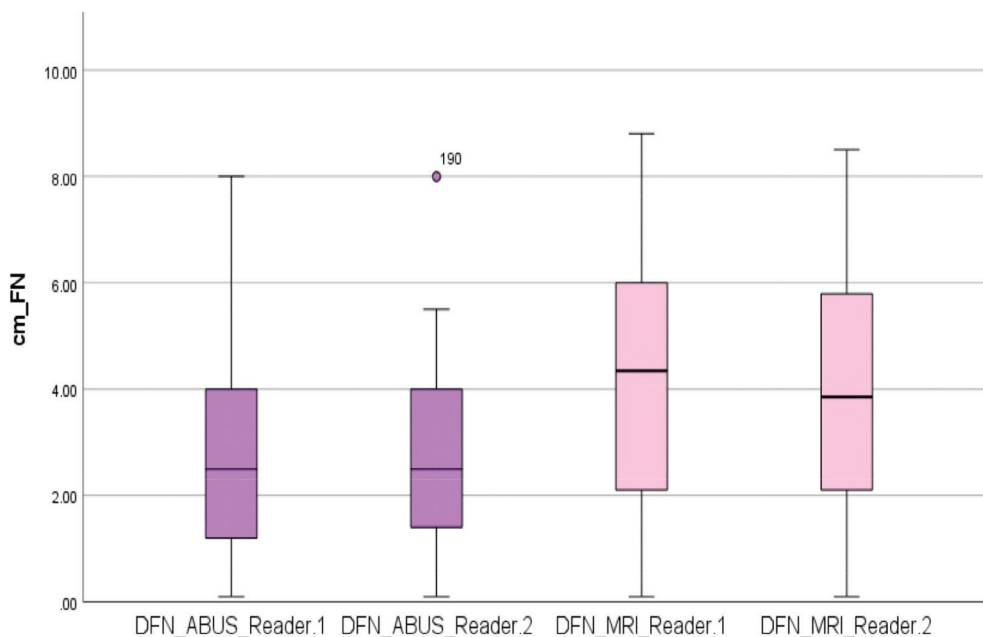
**Table 1.** Patient demographics and histopathological findings of 49 malignant breast lesions. (The summary of the mean age, ethnicity distribution, menopausal status and HPE results, including invasive carcinoma subtypes and ductal carcinoma in situ grades).

General characteristics	n = 36 (%)
<b>Age, years</b>	
Mean age. SD	51.43 ± 12.51
Commonest age range	40 - 49
<b>Ethnicity</b>	
Malay	16 (44.45)
Chinese	13 (36.11)
Indian	7 (19.44)
<b>Menopausal status</b>	
Pre-menopause	20 (55.56)
Post-menopause	16 (44.44)
<b>HPE for malignant lesions</b>	
<b>Invasive carcinoma</b>	<b>41 (83.67)</b>
Invasive ductal carcinoma NST	29
Invasive lobular carcinoma	7
Invasive mucinous carcinoma	4
Invasive papillary carcinoma	1
<b>Ductal carcinoma in-situ</b>	<b>8 (16.33)</b>
Low grade	3
Intermediate grade	4
High grade	1

SD: Standard deviation; n: Number, HPE: Histopathological examination; NST: No special type

General Electric Invenia system was used to acquire axial and coronal reconstruction images.

MRI was typically conducted within two weeks of ABUS to minimize interval changes in lesion



**Figure 2.** Comparison of the distance of the lesion from the nipple (DFN) in ABUS and MRI as assessed by Readers 1 and 2. The figure highlights the differences in measurements, with MRI generally measuring greater distances from the lesion to the nipple than ABUS. ABUS: Automated breast ultrasound; MRI: Magnetic resonance imaging

characteristics. MRI was performed with the patient in the prone position on a 3T Siemens Magnetom Prisma scanner (Siemens Healthcare, Erlangen, Germany) using a dedicated 8-channel breast coil. The imaging protocol included T2-weighted, STIR, diffusion-weighted imaging (DWI/ADC), and dynamic contrast-enhanced sequences. Intravenous administration of 0.1 mg/kg gadoterate meglumine (Dotarem, Guerbet, Roissy CdG Cedex, France) at a rate of 2 mL/s, followed by 20 ml of saline, was used.

Biopsies were generally performed after MRI to ensure that imaging findings were not influenced by procedural artefacts. However, in cases where an urgent biopsy was necessary due to clinical concerns or long MRI scheduling delays, MRI was performed more than two weeks post-biopsy. This timing variation was considered in the interpretation of lesion characteristics and measurement comparisons.

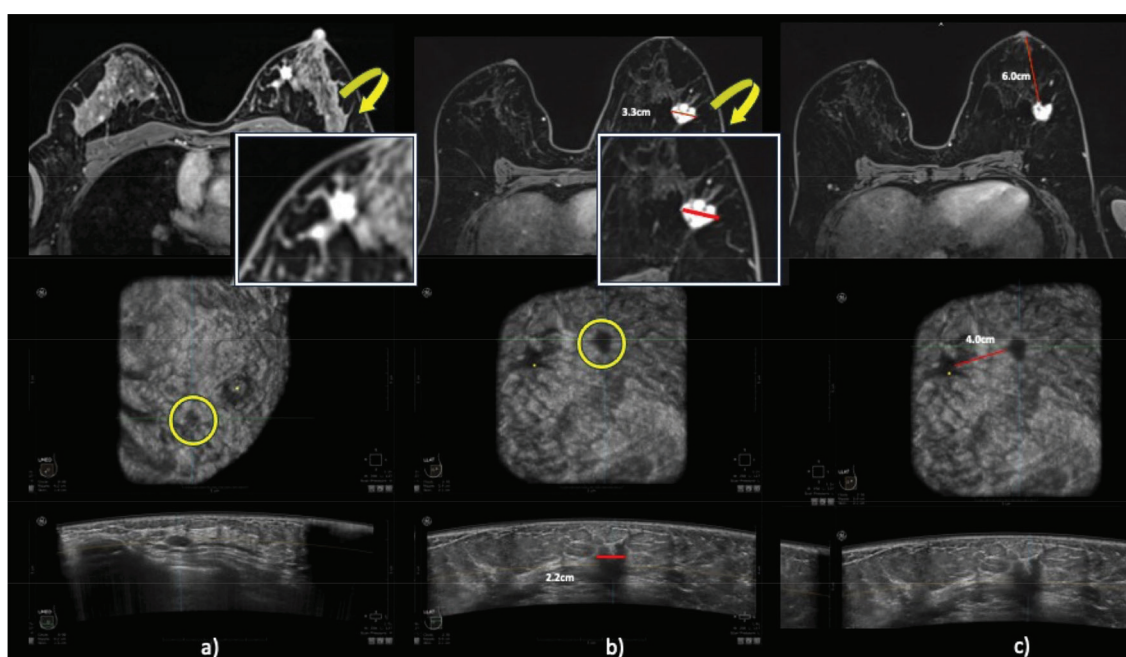
#### Image analysis

The MRI and ABUS images were independently anonymised and read by two board-certified breast radiologists of 5 and 10 years of

experience in a research setting from 1<sup>st</sup> February 2023 to 31<sup>st</sup> October 2023. The readers were blinded to the diagnosis, history, and prior examination results and findings. All cases were read in two stages, MRI followed by ABUS, with least 4 weeks apart between the two readings to reduce recall bias. Any disagreements were resolved by a third, most senior radiologist with 20 years of experience. Lesion characteristics, including location, tumour size, morphology, and distance from nipple, were documented in a study proforma for comparative analysis. Readers were also asked to note the primary cancer site, size and characters, and any other suspicious and non-suspicious lesions noted in the ipsilateral and contralateral breast.

#### Data collection and analysis

Data collection was done in an Excel spreadsheet. Statistical analysis was performed using SPSS version 25.0. Descriptive analysis was performed, where the numerical variables expressed either as mean with standard deviation or median with interquartile range based on normality of the data. Kappa analysis was



**Figure 3.** Representative cases demonstrating discrepancies between ABUS and MRI in lesion characterization and measurements. (a) A 45-year-old female with a palpable lump in the left periareolar region. The lesion, confirmed as invasive lobular carcinoma on HPE, appears irregular on MRI but is more well-defined and oval on ABUS. (b and C) A 56-Year-old female with a palpable left breast lump. HPE confirmed invasive ductal carcinoma. Image (b) shows the widest lesion diameter measured as 3.3 cm on MRI and 2.2 cm on ABUS. Image (c) illustrates the distance of the lesion edge from the nipple, measured as 6.0 cm on MRI and 4.0 cm on ABUS. ABUS: Automated breast ultrasound; MRI: Magnetic resonance imaging; HPE: Histopathological examination

**Table 2.** Lesion descriptors on ABUS and MRI, as assessed by Readers 1 and 2. (The frequency and percentage distributions for lesion shape (oval, round, irregular) based on each imaging modality, illustrating variations in reader interpretation and modality-specific characteristics)

SHAPE_MRI	Frequency		Percent		Valid percent		Cumulative percent	
	R1	R2	R1	R2	R1	R2	R1	R2
Valid								
Oval	1	1	2.00	2.00	2.10	2.10	2.10	2.10
Round	1	3	2.00	6.10	2.10	6.30	4.20	8.30
Irregular	46	44	93.90	89.80	95.10	91.70	100.00	100.00
Total	48	48	98.00	98.00	100.00	100.00		
Missing	1	1	2.00	2.00				
Total	49	49	100.00	100.00				
SHAPE_ABUS	Frequency		Percent		Valid percent		Cumulative percent	
	R1	R2	R1	R2	R1	R2	R1	R2
Valid								
Oval	7	2	14.30	4.10	14.30	4.10	14.30	4.1
Round	1	6	2.00	12.20	2.10	12.20	16.30	16.30
Irregular	41	41	83.70	83.70	83.70	83.70	100.00	100.00
Total	49	49	100.00	100.00	100.00	100.00		

ABUS: Automated breast ultrasound; MRI: Magnetic resonance imaging

performed to measure inter-rater agreement. In all tests,  $P$ -values  $< 0.001$  were considered statistically significant. Student's t-test was used to compare tumour size and distance from the nipple measurements between ABUS and MRI.

## Results

### Patient characteristics

The cohort comprised 36 women with a mean age of 51.4 years, including 36.11% ( $n = 13$ ) Chinese, 44.45% ( $n = 16$ ) Malay, and 19.44% ( $n = 7$ ) Indian. The majority (55.56%) were premenopausal with 59.25% exhibiting heterogeneously dense or dense breast parenchyma on MRI. Overall, 49 malignant breast lesions were assessed.

### Histopathological results

Histopathological analysis showed 83.3% ( $n = 30$ ) of the lesions were invasive carcinomas, predominantly invasive ductal carcinoma. The remaining 16.7% ( $n = 6$ ) were ductal carcinoma in situ. Table 1 summarizes patient demographics and histopathological findings of the lesions.

### Imaging (MRI and ABUS) findings

#### Tumour size

The mean tumour size measured 27.2 mm (SD: 19.6) on ABUS and 28.3 mm (standard deviation (SD): 17.3) on MRI, indicating a statistically significant larger size on MRI ( $P < 0.001$ ). The distribution of these measurements is depicted in figure 1.

#### Distance from the nipple

Measurements from Reader 1 indicated an

average distance from the nipple of 2.8 mm (SD: 0.28) for ABUS and 4.1 mm (SD: 0.37) for MRI. Reader 2 found similar trends, with means of 2.9 mm (SD: 0.26) for ABUS and 3.8 mm (SD: 0.35) for MRI. Despite MRI measurements generally being greater, the differences were not statistically significant ( $P = 0.158$ ). Figure 2 illustrates these distribution patterns.

### Inter-reader and inter-modality agreement

#### Breast density

There was perfect agreement between the readers for breast composition assessment in ABUS (kappa = 1.0) and almost perfect agreement of breast density in MRI (kappa = 0.91).

#### Tumour location

The kappa values for the agreement on tumour location were moderate (kappa = 0.53) for Reader 1 and substantial (kappa = 0.62) for Reader 2 between MRI and ABUS.

#### Lesion description

There was no significant agreement between readers or modalities in describing lesion characteristics such as shape (oval, round, irregular) and margins (well-defined, irregular, spiculated). The results are outlined in table 2.

Figure 3. shows example cases from the study population.

## Discussion

Our study found that MRI consistently measured larger tumour sizes than ABUS, and the distance from the nipple was also greater on

MRI compared with ABUS. These differences were statistically significant, emphasizing that MRI tends to provide larger tumour size estimations. Additionally, inter-reader agreement for breast density was excellent, reinforcing the reliability of both modalities in breast composition assessment. However, there was moderate to substantial agreement regarding tumour location, and significant discrepancies were noted in lesion characterization across both imaging techniques.

Breast MRI remains the gold standard for local staging due to its superior soft tissue contrast and high sensitivity in detecting both invasive and in situ malignancies.<sup>5-7, 16-18</sup> However, its high cost, limited accessibility, and longer examination times often restrict its use in resource-constrained settings. ABUS has emerged as a promising solution in this context.<sup>15, 19</sup> As a standardized and operator-independent imaging modality, it serves as an effective alternative, particularly for preoperative staging in women with dense breasts. Our study reinforces its efficacy, demonstrating that ABUS successfully detected all lesions identified by MRI. These findings contribute to the growing body of evidence supporting its clinical viability in tumour assessment and surgical planning.<sup>20, 21</sup> Notably, ABUS proves to be a reliable staging tool, with the potential for integration into standard diagnostic protocols, especially in scenarios where MRI is impractical or contraindicated.

Our study showed discrepancies in tumour size measurements between ABUS and MRI, with MRI consistently reporting larger sizes which is consistent with prior findings.<sup>22-24</sup> The discrepancy in tumour size measurements may be attributed to the ability of MRI to capture peritumoral oedema and infiltrative tumour borders, resulting in a larger perceived tumour size. This finding has critical surgical implications, as the underestimation of tumour size on ABUS could lead to insufficient surgical margins, potentially increasing the risk of local recurrence. Thus, in borderline cases where tumour size is crucial for breast-conserving surgery eligibility, MRI remains the preferred modality for precise tumour delineation.

Another key finding was the difference in lesion-to-nipple distance measurements between ABUS and MRI, with MRI reporting greater distances. This discrepancy can be explained by the different patient positioning during imaging—prone positioning in MRI stretches the breast tissue, leading to an increased distance measurement compared with supine positioning in ABUS.<sup>21, 25</sup> While these differences may not always impact surgical planning, they highlight the importance of considering patient positioning when interpreting imaging findings and planning procedures such as nipple-sparing mastectomy.

Our study also demonstrated excellent inter-reader agreement for breast density assessment on both ABUS and MRI, confirming the reliability of these modalities in evaluating this crucial breast cancer risk factor. This finding is consistent with findings by Moon et al., where there was high correlation in whole breast volume and breast percentage density between MRI and ABUS.<sup>26, 27</sup> This consistency is vital, as breast density has been strongly linked to the risk of developing breast cancer and can influence the choice of imaging strategies.

Inter-reader agreement for tumour location was moderate to substantial, reinforcing the reliability of ABUS for spatial tumour assessment. However, there was notable variability in lesion descriptors such as shape and margins between ABUS and MRI, reflecting inherent modality-based differences in lesion characterization. This variability underscores the need for improved standardization in ABUS interpretation and reporting, which could be facilitated by AI-assisted image analysis and structured reporting templates.

Our study supports the potential of ABUS as an adjunctive imaging tool in breast cancer staging, particularly in settings where MRI is not readily available. However, its limitations in tumour size estimation and lesion morphology assessment suggest that it should not replace MRI in complex or high-risk cases. Future research should focus on refining ABUS technology, integrating it with AI-based image analysis, and exploring its role in longitudinal monitoring of treatment response.

Overall, while MRI remains the preferred modality for comprehensive breast cancer staging, ABUS presents a viable alternative in specific clinical scenarios. Its accessibility, cost-effectiveness, and operator independence make it an attractive option, particularly in resource-limited settings. Clinicians should consider a multimodal approach, using both ABUS and MRI judiciously to optimize patient outcomes in breast cancer management.

The retrospective design and relatively small sample size of our study may limit the generalizability of the findings, as the sample volume was insufficient to allow broad applicability of the results. Additionally, the single-center setting may introduce institutional biases, and the absence of long-term follow-up data further restricts the scope of our conclusions. Future prospective, multi-center studies with larger cohorts are necessary to validate our findings, enhance statistical power, and assess the long-term impact of imaging modality on treatment outcomes and disease recurrence.

## Conclusion

In summary, our findings highlight the potential of ABUS as a useful tool for breast cancer staging, while also underscoring its limitations in tumour size measurement and lesion characterization. Although MRI remains the gold standard for preoperative staging, particularly in complex cases requiring precise tumour delineation for surgical planning, ABUS can serve as a valuable adjunct tool, especially in settings where MRI is not readily accessible or feasible. The integration of ABUS into clinical practice could enhance early detection and staging strategies, particularly for patients with dense breast tissue. Further research is warranted to explore the optimal integration of ABUS and MRI in breast cancer staging and to develop standardized reporting criteria for ABUS to enhance its diagnostic accuracy and clinical utility.

## Authors' Contributions

M.T.R.H, S.A.H, N.A.M, K.R: Study design;

data acquisition; data analysis and interpretation; drafting and critical reviewing of the manuscript. All authors read and approved the final manuscript version and agreed with all parts of the work in ensuring that any queries about the accuracy or integrity of any component of the work are appropriately investigated and handled.

## Funding

The research was funded by University Teknologi MARA Research Grant Scheme: 600/TNCPI-5/3/DDF (MEDIC) (003/2021), 600/TNCPI-5/3/DDJ(HUITM)(003/2021), 600/RMC-LESTARI SDG-T5/3 and supported by GE Precision Healthcare LLC.

## Conflict of Interest

None declared.

## References

1. Htay MNN, Donnelly M, Schliemann D, Loh SY, Dahlui M, Somasundaram S, et al. Breast cancer screening in Malaysia: A policy review. *Asian Pac J Cancer Prev.* 2021;22(6):1685-93. doi: 10.31557/APJCP.2021.22.6.1685. PMID: 34181322; PMCID: PMC8418850.
2. Ferlay J, Colombet M, Soerjomataram I, Parkin DM, Piñeros M, Znaor A. Cancer statistics for the year 2020: An overview. *Int J Cancer.* 2021. doi: 10.1002/ijc.33588. Epub ahead of print. PMID: 33818764.
3. Zhu H, Doğan BE. American Joint Committee on cancer's staging system for breast cancer, Eighth edition: Summary for clinicians. *Eur J Breast Health.* 2021;17(3):234-8. doi: 10.4274/ejbh.galenos.2021.2021-4-3. PMID: 34263150; PMCID: PMC8246053.
4. Teichgraber DC, Guirguis MS, Whitman GJ. Breast cancer staging: updates in the AJCC cancer staging manual, 8<sup>th</sup> edition, and current challenges for radiologists, from the AJR special series on cancer staging. *AJR Am J Roentgenol.* 2021;217(2):278-90. doi: 10.2214/AJR.20.25223. PMID: 33594908.
5. Washington I, Palm RF, White J, Rosenberg SA, Ataya D. The role of MRI in breast cancer and breast conservation therapy. *Cancers (Basel).* 2024;16(11):2122. doi: 10.3390/cancers16112122. PMID: 38893241; PMCID: PMC11171236.
6. Eisen A, Fletcher GG, Fienberg S, George R, Holloway C, Kulkarni S, et al. Breast magnetic resonance imaging for preoperative evaluation of breast cancer: A systematic review and meta-analysis. *Can Assoc Radiol J.* 2024;75(1):118-35. doi: 10.1177/08465371231184769. PMID: 37593787.

7. Thompson JL, Wright GP. The role of breast MRI in newly diagnosed breast cancer: An evidence-based review. *Am J Surg*. 2021;221(3):525-8. doi: 10.1016/j.amjsurg.2020.12.018.PMID: 33339617.
8. Rahmat K, Mumin NA, Hamid MTR, Hamid SA, Ng WL. MRI breast: Current imaging trends, clinical applications, and future research directions. *Curr Med Imaging*. 2022;18(13):1347-61. doi: 10.2174/1573405618666220415130131. PMID: 35430976.
9. Girometti R, Tomkova L, Cereser L, Zuiani C. Breast cancer staging: Combined digital breast tomosynthesis and automated breast ultrasound versus magnetic resonance imaging. *Eur J Radiol*. 2018;107:188-95. doi: 10.1016/j.ejrad.2018.09.002.PMID: 30292265.
10. Schmachtenberg C, Fischer T, Hamm B, Bick U. Diagnostic performance of automated breast volume scanning (ABVS) compared to handheld ultrasonography with breast MRI as the gold standard. *Acad Radiol*. 2017;24(8):954-61. doi: 10.1016/j.acra.2017.01.021.PMID: 28336007.
11. Vourtsis A, Kachulis A. The performance of 3D ABUS versus HHUS in the visualisation and BI-RADS characterisation of breast lesions in a large cohort of 1,886 women. *Eur Radiol*. 2018;28(2):592-601. doi: 10.1007/s00330-017-5011-9.PMID: 28828640.
12. Jia M, Lin X, Zhou X, Yan H, Chen Y, Liu P, et al. Diagnostic performance of automated breast ultrasound and handheld ultrasound in women with dense breasts. *Breast Cancer Res Treat*. 2020;181(3):589-97. doi: 10.1007/s10549-020-05625-2.PMID: 32338323.
13. Giger ML, Inciardi MF, Edwards A, Papaioannou J, Drukker K, Jiang Y, et al. Automated breast ultrasound in breast cancer screening of women with dense breasts: Reader study of mammography-negative and mammography-positive cancers. *AJR Am J Roentgenol*. 2016;206(6):1341-50. doi: 10.2214/AJR.15.15367. PMID: 27043979.
14. Rahmat K, Ab Mumin N, Ng WL, Mohd Taib NA, Chan WY, Ramli Hamid MT. Automated breast ultrasound provides comparable diagnostic performance in opportunistic screening and diagnostic assessment. *Ultrasound Med Biol*. 2024;50(1):112-8. doi: 10.1016/j.ultrasmedbio.2023.09.011.PMID: 37839984.
15. Łuczyńska E, Pawlak M, Popiela T, Rudnicki W. The role of ABUS in the diagnosis of breast cancer. *J Ultrason*. 2022;22(89):76-85. doi: 10.15557/JoU.2022.0014. PMID: 35811591; PMCID: PMC9231518.
16. Mann RM, Balleyguier C, Baltzer PA, Bick U, Colin C, Cornford E. Breast MRI: EUSOBI recommendations for women's information. *Eur Radiol*. 2015;25(12):3669-78. doi: 10.1007/s00330-015-3807-z. PMID:26002130; PMCID: PMC4636525.
17. Wang SY, Long JB, Killelea BK, Evans SB, Roberts KB, Silber A, et al. Preoperative breast magnetic resonance imaging and contralateral breast cancer occurrence among older women with breast cancer. *J Clin Oncol*. 2016; 34(4):321-8. doi: 10.1200/JCO.2015.62.9741.PMID: 26628465; PMCID: PMC4872032.
18. Mann RM, Cho N, Moy L. Breast MRI: State of the art. *Radiology*. 2019;292(3):520-36. doi: 10.1148/radiol.2019182947. PMID: 31361209.
19. Boca Bene I, Ciurea AI, Ciortea CA, Ducea SM. Pros and cons for automated breast ultrasound (ABUS): A narrative review. *J Pers Med*. 2021;11(8): 703. doi: 10.3390/jpm11080703. PMID: 34442347; PMCID: PMC8400952.
20. Wang X, Huo L, He Y, Fan Z, Wang T, Xie Y, et al. Early prediction of pathological outcomes to neoadjuvant chemotherapy in breast cancer patients using automated breast ultrasound. *Chin J Cancer Res*. 2016;28(5):478-85. doi: 10.21147/j.issn.1000-9604.2016.05.02. PMID: 27877006; PMCID: PMC5101221.
21. D'Angelo A, Rinaldi P, Belli P, D'Amico R, Carlino G, Grippo C, et al. Usefulness of automated breast volume scanner (ABVS) for monitoring tumor response to neoadjuvant treatment in breast cancer patients: preliminary results. *Eur Rev Med Pharmacol Sci*. 2019;23(1):225-31. doi: 10.26355/eurev\_201901\_16768. PMID: 30657564.
22. Panico C, Ferrara F, Woitek R, D'Angelo A, Di Paola V, Bufi E, et al. Staging breast cancer with MRI, the T. A key role in the neoadjuvant setting. *Cancers (Basel)*. 2022;14(23):5786. doi: 10.3390/cancers14235786. PMID: 36497265; PMCID: PMC9739275.
23. Lagendijk M, Vos EL, Ramlakhan KP, Verhoef C, Koning AHJ, van Lankeren W, et al. Breast and tumour volume measurements in breast cancer patients using 3-D automated breast volume scanner images. *World J Surg*. 2018;42(7):2087-93. doi: 10.1007/s00268-017-4432-6. PMID: 29299647; PMCID: PMC5990576.
24. Taydaş O, Durhan G, Akpınar MG, Demirkazık FB. Comparison of MRI and US in tumor size evaluation of breast cancer patients receiving neoadjuvant chemotherapy. *Eur J Breast Health*. 2019;15(2):119-24. doi: 10.5152/ejbh.2019.4547. PMID: 31001614; PMCID: PMC6456278.
25. D'Angelo A, Gatta G, Di Grezia G, Mercogliano S, Ferrara F, Trombadori CML et al. Supine versus prone 3D abus accuracy in breast tumor size evaluation. *Tomography*. 2022;8(4):1997-2009. doi: 10.3390/tomography 8040167. PMID: 36006065; PMCID: PMC9413588.
26. Chen JH, Lee YW, Chan SW, Yeh DC, Chang RF. Breast density analysis with automated whole-breast ultrasound: Comparison with 3-D magnetic resonance imaging. *Ultrasound Med Biol*. 2016;42(5):1211-20. doi: 10.1016/j.ultrasmedbio.2015.12.015.PMID:

26831342.

27. Allajbeu I, Hickman SE, Payne N, Moyle P, Taylor K, Sharma N, et al. Automated breast ultrasound: Technical aspects, impact on breast screening, and future perspectives. *Curr Breast Cancer Rep.* 2021; 13(3):141–50.