

## Case Report

**Running Title:** Type 1 Neurofibromatosis Presenting with Melena and Gastric Hemorrhage

Received: June 22, 2024; Accepted: March 05, 2025

### Intervention of Primary Focus of Type 1 Neurofibromatosis Presenting with Melena and Gastric Hemorrhage of Unknown Origin and Nursing Care: A Case Report

Ghobad Abanghah\*, MD, Abdolreza Heidarizadi\*\*, MD, Hamed Tavan\*\*\*♦, MSc

\**Department of Gastroenterology and Hematology, School of Medicine, Ilam University of Medical Sciences, Ilam, Iran*

\*\**Department of Teneral Surgery and Advanced Laparoscopy, Surgical Department Iranian Hospital Dubai, Dubai, United Arab Emirates*

\*\*\**Nursing Department, Faculty of Nursing and Midwifery, Ilam University of Medical Sciences, Ilam, Iran*

#### ♦Corresponding Author

Hamed Tavan, MSc

Clinical Research Development Unit,  
Shahid Mostafa Khomeini Hospital,  
Ilam University of Medical Sciences,  
Ilam, Iran

Tel: +98-9187474221

Fax: +98-8412227134

Email: [hamedtavan@gmail.com](mailto:hamedtavan@gmail.com)

#### Abstract

There are four types of neurofibromatosis, with types 1 and 2 being the most prevalent among them. The disease incidence is 1 in every 3,000 births. In the present study, we reported a patient with neurofibromatosis type 1 presenting with melanoma and gastric hemorrhage of unknown origin. A 37-year-old woman with a history of gastrointestinal bleeding and evidence of multiple retroperitoneal masses in the computed tomography scans of abdominal and pelvic cavities was admitted to our hospital. The masses were successfully removed by surgery.

In cases of bleeding with an unknown cause, especially in patients with neurofibromatosis, the possibility of small intestinal tumors, especially gastrointestinal stromal tumors, should be considered.

**Keywords:** Hemorrhage, Neurofibromatosis, Surgery, Case report, Mortality

#### Introduction

Neurofibromatosis (NF) is a rare genetic disorder characterized by multiple but mostly benign tumors. Gastrointestinal stromal tumor (GIST) is a benign mesenchymal lesion that usually involves the jejunum and ileum. There are four types of NF, the most common of which are types 1 and 2. NF1 or von Recklinghausen's disease is an

autosomal dominant disease caused by a mutation in a gene on chromosome 17. Epidemiologically, it occurs at the rate of 1 in every 3,000 births and is generally diagnosed in adulthood after affecting body systems or organs, especially neuronal and vascular tissues.<sup>1-3</sup> In the present study, a case of NF1 was described in a young woman who presented with melanoma and gastric

bleeding of unknown origin, referring to Shahid Mostafa Khomeini Hospital of Ilam in May, 2020.

## **Case Presentation**

### ***Patient information***

This was the case of a 37-year-old woman with a history of gastrointestinal bleeding (GIB) from one year ago. She was a known case of NF diagnosed in 2009. She was hospitalized in the Shahid Mostafa Khomeini Hospital of Ilam. The patient received 7 units of packed red blood cells during hospitalization. Endoscopy and colonoscopy findings were normal. Two days prior to admission, she noticed bitumen-black stool with a loose and sticky appearance in every defecation. The patient had been experiencing mild and occasional epigastric non-progressive pain confined to a specific location. There was no nausea or vomiting.

### ***Clinical findings***

As mentioned, the patient was a known case of NF1 diagnosed in 2009. She declared a history of bloody stools from one year ago. No history of prior surgery, or cardiac, neurologic, and metabolic diseases was announced. Also, no familial history of gastrointestinal cancers was noted.

### ***Timeline***

The patient had been consuming omeprazole, famotidine, Clidinium-C, naproxen, and Gelofen over the past ten days. No history of alcohol consumption or cigarette smoking was described. The patient had anorexia and fatigue during the past week, but neither dyspnea nor weight loss were recorded. She was awake and conscience to the place and time.

### ***Diagnostic assessment***

The patient's blood pressure was 120/80 mmHg; the pulse rate was 78 bpm; respiratory rate was 12, and oxygen saturation was 98%.

In the clinical examination, generalized coffee-milk colored skin spots ranging from

2 to 8 cm in diameter were noticed. Petechiae, purpura, and ecchymosis were not observed. The conjunctiva was pale, but no scleral icterus was observed. Mucus layers were normal.

### ***Therapeutic intervention***

The patient's complaints included melena for the past two days, mild epigastric pain from one week ago, rectoragia during the past year, and generalized coffee-milk colored skin spots. She had been consuming naproxen and gelofenduring for the past 10 days. Table 1 shows the patient's diagnostic and laboratory tests results.

The patient received 6 units of packed red blood cells during hospitalization. Also, she underwent serum therapy. Endoscopy, colonoscopy, and angiography were performed during hospitalization, which rendered normal findings. Nuclear radionuclide scan using Technetium-99 was performed to rule out Meckel's diverticulum. On the computed tomography (CT) scans of the abdominal and pelvic cavities, multiple retroperitoneal masses were observed. Biopsies were obtained from these masses following surgical resection.

There were at least 3 retroperitoneal hypo-attenuated areas along with a number of internal necrotic foci, which one of them had internal calcification within the abdominal cavity among bowel loops (dimensions of about 51 × 40 mm, 54 × 37 mm, and 48 × 35 mm). Several small para-aortic lymph nodes were also noticed.

Immunohistochemistry was performed to diagnose stromal tumors, which revealed the following results:

- 1-CD117: positive in tumor cells.
- 2-SMA: focal positivity in tumor cells.
- 3-CD34: positive in tumor cells.
- 4-S100: negative in tumor cells.
- 5- Ki67: positive in 1% of tumor cells.

This pattern supported the diagnosis of low-grade GIST, the smooth muscle type.

Figure 1 (A and B) shows surgically removed masses.

### ***Procedures***

#### ***Laparoscopic diagnosis and surgery***

Pre op DX: lower GI bleeding of unknown origin

Post op DX: multiple hyper vascular masses in the jejunum

A summary of significant diagnostic and therapeutic events

1) Jejunal hyper vascular non-adhesive masses of different sizes were observed, and no other abnormalities were seen in the abdominal and pelvic cavities.

3) Segmental resection and anastomoses were noticed.

4) No intra-operative complication was observed.

5) Disposition - PACU/WARD

6) The bleeding was managed, and the patient was discharged with no complications.

Spiral CT scan of abdomen and pelvic with and without IV and oral contrast with coronal reconstruction: multiple axial images through the abdomen and pelvic with and without IV and oral contrast administration demonstrate: liver is normal in size with normal parenchymal density with no evidence of mass or biliary dilatation.

G.B is unremarkable. The visualized pancreas, spleen have normal density and anatomic configuration. Both kidneys excrete simultaneously with no sign of abnormal enhancement.

No hydronephrosis or ureteral dilatation is seen. There are several small paraaortic lymph nodes.

There is no sign of mesenteric stranding. Stomach at least three retroperitoneal hypo attenuation areas with some internal necrotic foci, which one of them has internal calcification in abdominal cavity between bowel loops with enhancement measuring about 51 × 40 mm, 54 × 37 mm and 48 × 35 mm.

According above findings conglomerated lymph nodes in favor of infectious disease such as (T.B), carcinoid tumor or less probably GIST should be in consideration, so tissue evaluation is recommended.

Wall thickening seen in stomach can be due to technical problems, however correlation with endoscopic finding is recommended.

Pelvic CT scan shows normal size of urinary bladder with no sign of wall thickening. Other genital-urinary structures in pelvis show normal density and anatomic configuration.

There is no sign of pelvic wall lymphadenopathy. There are several small sclerotic foci in both femoral heads can due to bone islander. Abdominal masses small paraaortic lymph nodes.

#### ***Surgery report***

The patient was brought to the operation room. After checking surgical safety items, the patient was given prophylactic antibiotics. General anesthesia was induced. Foley catheter was inserted, and in the supine position, the abdomen was prepped and draped in a sterile fashion. An infra umbilical midline incision was created using an open/closed technique. The first port was inserted, and pneumoperitoneum was established. The scope was inserted into the abdominal cavity, and under direct vision, the peritoneal cavity was inspected. Upon the exploration, multiple hyper vascular masses were observed at the mesenteric side of the jejunum. The masses had different sizes without adhesion to other tissues and were extended from 15 cm of the trite ligament with 40 cm in length.

#### ***Follow-up and outcomes***

The other parts of the abdominal and pelvic cavities were intact. Two linear cutting staplers were used to staple the upper and lower segments of the involved area considering 5-cm safe margins. The meso was divided using a 5-mm ligature. Jejunojejunostomy was accomplished using

the Endo GI stapler, and the defect was approximated with absorbable stitches. The masses were collected into an endoscopic bag and sent for pathological examinations. The defect of meso was then approximated. A good hemostasis was preserved during the surgery, and all ports were removed under direct vision after sponge count. The fascia at the infra umbilical area was re-approximated. The patient was extubated and transferred to the post-anesthesia care unit in a stable condition.

#### ***Ethical approval***

The present study has been approved in Ilam University of Medical Sciences, with the code of ethics (IR.MEDILAM.REC.1403.222).

#### **Discussion**

NF1 is a rare disease affecting multiple organs and systems of the body. The disease is associated with aneurysm and the involvement of around 3% of vascular beds.<sup>4</sup> Considering that gastric and duodenal ulcers are the most common causes of GIB, these were initially investigated in our patient. On the other hand, as the patient was a known case of NF, other possible etiologies such as GIST, small bowel ulcers, and adenocarcinoma were also considered. Angiography and CT scans were performed to rule out other rare etiologies, which rendered negative results.

#### ***Nursing care***

Although patients with NF1 can independently receive basic nursing care, this should be under the supervision of a healthcare team, including physicians and nurses.<sup>5-6</sup> The requirements are as follows: physical examination, measuring blood pressure, inspecting for cutaneous lesions (e.g., primary or growing neurofibroma), visual acuity assessment, checking the eyes for evidence of proptosis or strabismus, and examining the spine and limbs for any abnormalities. A neurological assessment

should include a detailed history for headaches, as well as a comprehensive inspection for motor and sensory problems.<sup>7</sup> Caring for cancer patients is an important factor in improving their health.<sup>8</sup>

The most important limitation of this report was the unavailability of endoscopic capsules, endoscopy double-balloons, and single-endoscopy method.

#### **Conclusion**

In cases of bleeding with unknown origin, especially in patients with NF, one should consider small intestine tumors, particularly GIST.

#### **Informed Consent**

Written informed consent was obtained from the patient for publication of this case report. A copy of the written consent is available for review by the Editor-in-Chief of this journal on request.

#### **Funding**

The authors declare that this work was not supported by any grants or funding support.

#### **Authors' Contribution**

Ghobad Abanghah was involved in the study concept, the collection of the data, drafting, literature review, and editing of the manuscript. Abdolreza Heidarizadi was responsible for literature review and revising the manuscript for important intellectual content. Hamed Tavan was responsible of data validation and supervision, and revising the manuscript for important intellectual content. All authors read and approved the final manuscript.

#### **Conflict of Interest**

None declared.

#### **References**

1. Degbelo FDA, Cito G, Guendil B, Christodoulou M, Abbassi Z. Spontaneous

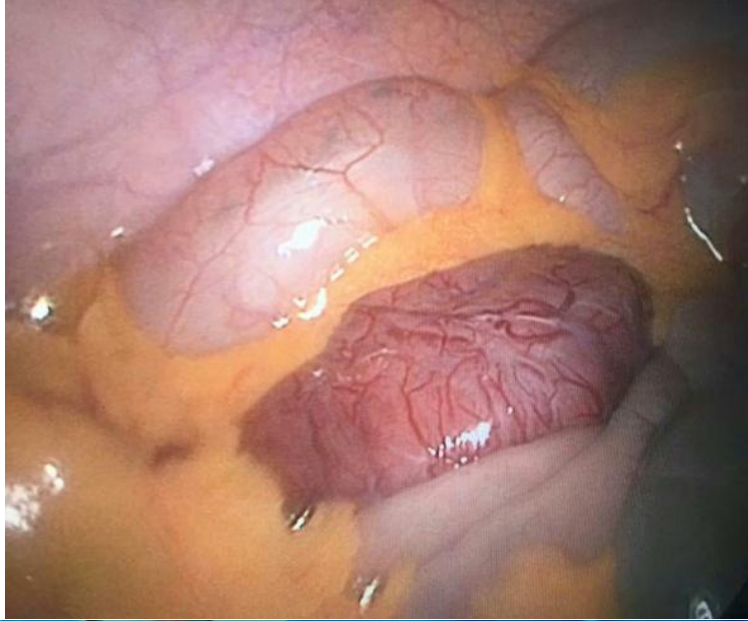
- hemothorax in a patient with von Recklinghausen's disease: A case report and review of the literature. *Am J Case Rep.* 2019;20:674-8. doi: 10.12659/AJCR.915810. PMID: 31076564; PMCID: PMC6543949.
2. Jeong SC, Kim JJ, Choi SY, Kim YH, Kim IS. Successful surgical treatment of massive spontaneous hemothorax due to intrathoracic secondary degeneration of a neurofibroma from mediastinal involvement of type 1 neurofibromatosis. *J Thorac Dis.* 2018 Mar;10(3):E203-E206. doi: 10.21037/jtd.2018.01.170. PMID: 29707374; PMCID: PMC5906240.
3. Neto AF, Ferreira EG Junior, de Melo Freire Golveia Silveira L, Gusmão F, Saad KR, Saad PF. Spontaneous bilateral hemothorax in neurofibromatosis type 1 due to internal thoracic artery aneurysm: Case report. *Int J Surg Case Rep.* 2020;68:36-38. doi: 10.1016/j.ijscr.2020.02.026. PMID: 32113169; PMCID: PMC7044636.
4. Adil A, Koritala T, Munakomi S, Singh AK. Neurofibromatosis type 1. 2023 Aug 13. In: StatPearls [Internet]. Treasure Island (FL): StatPearls Publishing; 2024 Jan-. PMID: 29083628.
5. Rostami F, Babahaji M, Sheikhnejad F, Karimi V. The effect of the continuous care model on the adherence to the medication regimen of patients hospitalized in the psychiatric ward: A quasi-experimental study. *Journal of Nursing Advances in Clinical Sciences.* 2024;1(2):85-90. doi: 10.32598/JNACS.2405.1025
6. Hajwal SK, Ayad ZM, Hanita AT, Hussein MS, Hussein SAA, Hammoud GH, et al. Patients' knowledge of diabetic foot self-care practice: A cross-sectional study. *Journal of Nursing Advances in Clinical Sciences.* 2024;1(4):178-81. doi: 10.32598/JNACS.2407.1044
7. Hsieh DT, Rohena LO. Neurofibromatosis type 1 treatment and management. [Internet] Available at: <https://emedicine.medscape.com/article/1177266-treatment?form=fpf>
8. Shohani M, Tavan H. The validity and reliability of the constructs of pain management-measuring tool for incurable patients. *Iranian Red Crescent Medical Journal (IRCMJ).* 2024;20(9):1-4. doi: 10.5812/ircmj.62353.

Table 1. The patient's laboratory findings

Parameters/ Number of days hospitalized	1	2	3	4	5	6	7	8
<b>WBC</b>	9800	4600	4200	4900	4100	5300	6300	5500
<b>Hemoglobin</b>	9.8	9.8	9	10.8	9.3	8.1	10	8.2
<b>Platelet count</b>	186000	186000	173000	183000	149000	159000	197000	391000
<b>PT</b>	14							
<b>PTT</b>	38							
<b>INR</b>	1.1							
<b>Urea</b>	26							
<b>Cr</b>	0.8							
<b>Na</b>	0.136							
<b>K</b>	3.2							
<b>BS</b>	128							

WBC: White blood count; PT: Prothrombin time; PTT: Partial thromboplastin time; INR: International normalized ratio; Cr: Creatine; Na: Sodium; K: Potassium; BS: Blood sugar

A



B

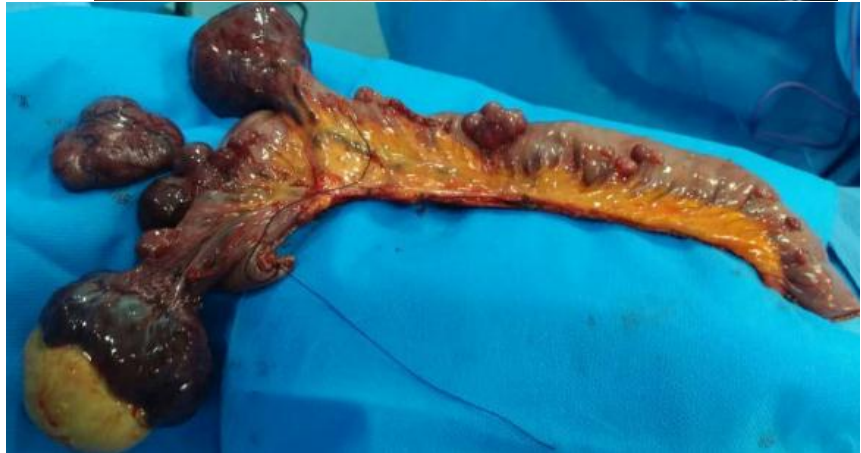

Figure 1. This pattern supported the diagnosis of low-grade GIST, the smooth muscle type. (A) Surgically removed masses from the patient; (B) The masses recovered from the patient after surgery.