

# The Safety and Efficacy of Cold Atmospheric Plasma as a Novel Therapy: An in vivo Study

Atieh Akbari\*, MD, Mahdiyeh Bakhtiyari-Ramezani\*\*, PhD,  
Dorsa Najari\*, MD, Mehdi Aziz Mohamadloo MA, MSc, Afshin Moradi\*\*\*, MD,  
Mahdis Bayat\*, MD, Fereshteh Abbasvandi\*, MD,  
Batoul Khoundabi\*\*\*\*, PhD, Mohammad Esmaeil Akbari\*\*, MD

\*Cancer Research Center, Shahid Beheshti University of Medical Sciences, Tehran, Iran

\*\*Plasma Physics and Nuclear Fusion Research School, Nuclear Science and Technology Research Institute (NSTRI), Tehran, Iran

\*\*\*Department of Pathology, , Shahid Beheshti University of Medical Sciences, Tehran, Iran

\*\*\*\*Iran Helal Institute of Applied-Science and Technology, Red Crescent Society of Iran, Tehran, Iran

## Abstract

**Background:** Cold atmospheric plasma (CAP) may reduce bacteria and aid wound healing through reactive oxygen species. Recent trials support CAP for chronic wounds, but its effectiveness is not well-proven. This study evaluates the efficacy of CAP on wound healing rate.

**Method:** This cross-sectional study was conducted sequentially to investigate the impact of CAP intervention on wound healing in rats over a period from 2022 to 2023. The study was carried out at the Atomic Energy Organization of Iran. A total number of 16 rats were divided into three groups based on the duration of CAP exposure: Group 1 (0 minutes), Group 2 (3 minutes), and Group 3 (5 minutes). Continuous variables were reported as mean  $\pm$  SD. Group differences were analyzed using ANOVA or Kruskal-Wallis. A  $P < 0.05$  was considered statistically significant.

**Results:** Day zero analysis revealed an absence of acute inflammatory response, with neutrophils consistently absent across all groups. Lymphocytes were predominantly absent, with a mild presence observed in most cases. Granulation tissue was mainly absent, and when present, it exhibited minimal extent. Blood vessel count was mostly below 20 per 10 high-power fields, with a slightly higher count in the 5 minute CAP intervention group. Fibroblasts were mostly absent, and when present, they were found in minimal extent. Ulcers, keloids, and hypertrophic scars were largely absent in all cases. Day seven and fourteen analyses revealed no significant differences between the left and right sides of the wounds for most variables.

**Conclusion:** CAP therapy showed promise for acute wound healing in rats, with minimal inflammation and scar formation. Further research is needed to optimize its use.

**Keywords:** Cold plasma, Wound healing, CAP therapy, Reactive oxygen and nitrogen species

Please cite this article as: Akbari A, Bakhtiyari-Ramezani M, Najari D, Mohamadloo MA, Moradi A, Bayat M, et al. The Safety and Efficacy of Cold Atmospheric Plasma as a Novel Therapy: An in vivo Study. Middle East J Cancer. 2025;16(3):288-96. doi: 10.30476/mejc.2024.102257.2079.

Received: April 10, 2024;  
Accepted: November 09, 2024

### \*Corresponding Author:

Mohammad Esmaeil Akbari, MD  
Cancer Research Center, Shahid Beheshti University of Medical Sciences, Tehran, Iran  
Email: profineakbari@gmail.com



## Introduction

Cold atmospheric plasma (CAP), with its basic biological effectiveness, is known as a source of reactive oxygen and nitrogen species, electric fields and electromagnetic radiation. Given the broad-spectrum effects of reactive species on various cell types, there is a great interest in this interdisciplinary research field. CAP has been applied as a novel treatment approach in the biomedical science, due to its promising efficiency including antimicrobial features, anticancer effects and wound healing properties.<sup>1, 2</sup>

Although, a multitude of research have been published on the multivariate clinical applications of CAP, the safety of this therapeutic method is still a major concern.<sup>3, 4</sup> Accordingly, a lot of investigations have been carried out on mammalian cells and tissues such as toxicity and mutagenicity analysis, capability to stimulate different cell lines (e.g. fibroblasts), AFM images of different treated cell lines and evaluations of treated human blood.<sup>5-11</sup> Previous studies demonstrated that there is no side effects or allergic reactions occurred using CAP.<sup>12</sup> In a line of in vitro and in vivo studies, no significant adverse effects have been reported for applying CAP in wound healing.<sup>12,13</sup> However, some still believe that CAP fails to bring clinical benefits to chronic wounds healing.<sup>14</sup>

Results of previous demonstrations indicated that CAP could be an efficient method to reduce the bacterial load, and generates some biologically active reactive species, including reactive oxygen species (ROS), thereby is beneficial to the wound healing process. However, using this novel method is like being on a knife edge for a couple of reasons. First, its antibacterial effects did not seem to last long.<sup>14</sup> Second, possible underlying mechanisms that could be triggered by CAP can led to cell death, which is exactly opposite to what we desire in wound healing. High intensities and treatment times are also a matter of concern for unknown adverse effects. Last but not least, CAP triggers proliferation of inflammatory cytokines levels, which can be both harmful and beneficial.

In this study we aimed to evaluate the clinical

safety and risk aspects in the medical application of CAP based on histological assessment.

## Materials and Methods

### Animals

This experimental, cross-sectional, controlled animal study was conducted to evaluate the effects of Cold Atmospheric Plasma (CAP) on wound healing in Wistar rats. The animal procedures were conducted following the principles of laboratory animal care outlined by the National Institutes of Health (NIH, 1985), and were approved by the Institutional Animal Care and Use Committee. All animal procedures were conducted in accordance with the ethical standards of the Institutional Review Board of Shahid Beheshti University of Medical Sciences, Cancer Research Center (IRB No. IR.SBMU.CRC.REC.1401.038). 18 adult male Wistar rats were selected for the study. Each rat had two full-thickness wounds created, one on the left side and one on the right side of the dorsal skin. The left-side wound served as the control and received no treatment, while the right-side wound was treated with CAP for either 3 or 5 minutes.

### Plasma set-up

In this experiment, the plasma source provided by Plasma Technology Development Company (Tehran, Iran) was used. The plasma source type was a cold atmospheric pressure jet where its carrier gas was helium, and was directly applied to the wound surface. The plasma was generated using a hand-held unit equipped with a gun-like nozzle made of quartz glass, featuring an internal metal electrode and a grounded metal electrode mounted on the outer wall of the quartz tube. The system operated at 8.5 kV and 17 kHz, with a gas flow rate of 3 liters per minute using 99.999% pure helium (He). The plasma jet, was directed at a 20 mm distance from the wound surface, ensuring direct contact between the plasma plumes and the wound. The right-side wounds in the rats were exposed to plasma for either 3 minutes or 5 minutes, depending on the experimental group.

### Study design

The rats were divided into three groups:

- Group G1-Control consisted of six rats, with

the right-side wounds receiving no CAP treatment.

- Group G2 included five rats, with the right-side wounds receiving 3 minutes CAP treatment.
- Group G3 included five rats, with the right-side wounds receiving 5 minutes CAP treatment.

All rats were housed in a sterile environment, and wound photographs were taken on days 1, 3, 5, 7, 9, 11, and 14 post-treatment. On day 7, a biopsy was performed on both wounds, and on day 21, samples were collected from all wounds. The wound samples were subjected to histopathological analysis to assess changes in proliferation index, neovascularization, re-epithelialization, N/C ratio, and any potential cellular alterations, such as wild-type transformation or malignancy. Additionally, the presence of neutrophils, macrophages, lymphocytes, granulation tissue, and scar formation, including hypertrophic scars and keloids, was evaluated.

#### Long-term assessment

Long-term cellular changes were evaluated 3 months after CAP treatment. Biopsy samples were taken from both wounds at this time point to assess the long-term effects of plasma therapy and any cellular alterations. These samples were analyzed using qualitative and semi-quantitative

methods, including histopathological and immuno-histochemical staining, to evaluate the inflammatory response in the skin tissue.

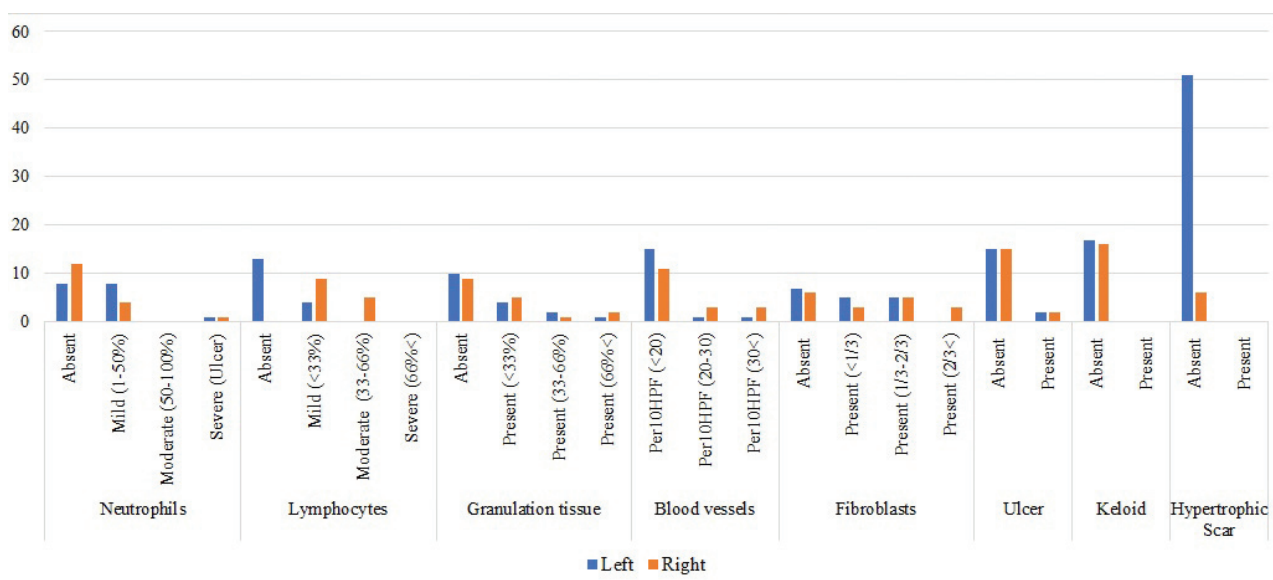
#### Statistical analysis

Statistical analysis was performed using IBM SPSS Statistics version 27.0 (SPSS Inc., Chicago, Illinois). Graphs and figures were created using GraphPad Prism 5.0 (GraphPad Software, Inc.). Continuous variables were presented as mean  $\pm$  standard deviation (SD). For comparison of differences among groups, an ANOVA or Kruskal-Wallis test was applied as appropriate. A two-tailed  $P < 0.05$  was considered statistically significant.

## Results

Effect of CAP therapy on histological variables in rat wound healing: Day zero assessment

This study evaluated the histological impact of CAP intervention on wound healing in rats. To do so, three intervention groups were investigated: G1 (0 minutes), G2 (3 minutes), and G3 (5 minutes). The analysis of Neutrophils revealed a consistent absence across all groups, indicating a lack of acute inflammatory response (Table 1). Lymphocytes were predominantly absent, with mild presence observed in 95% of



**Figure 1.** This figure shows the histological comparison of left and right responses to cold atmospheric plasma therapy in rat wound healing on day 7.

MRI: Magnetic resonance imaging

**Table 1.** Histological assessment of key variables on day zero in response to cold atmospheric plasma therapy in rats

Variables	Levels	Total (n=20)	G1 (n=2)	G2 (n=10)	G3 (n=8)
Neutrophils	Absent	20 (100.00)	2 (100.00)	10 (100.00)	8 (100.00)
	Mild (1-50%)	0 (0.00)	0 (0.00)	0 (0.00)	0 (0.00)
	Moderate (50-100%)	0 (0.00)	0 (0.00)	0 (0.00)	0 (0.00)
	Severe (Ulcer)	0 (0.00)	0 (0.00)	0 (0.00)	0 (0.00)
Lymphocytes	Absent	0 (0.00)	0 (0.00)	0 (0.00)	0 (0.00)
			2	10	
	Mild (<33%)	19 (95.00)	(100.00)	(100.00)	7 (87.5)
	Moderate (33-66%)	1 (5.00)	0 (0.00)	0 (0.00)	1 (12.5)
Granulation tissue					
			2	10	
	Absent	18 (90.00)	(100.00)	(100.00)	6 (75.00)
	Present (<33%)	2 (10.00)	0 (0.00)	0 (0.00)	2 (25.00)
Blood vessels	Present (33-66%)	0 (0.00)	0 (0.00)	0 (0.00)	0 (0.00)
	Present (66%<)	0 (0.00)	0 (0.00)	0 (0.00)	0 (0.00)
Fibroblasts					
			2	10	
	Per10HPF (<20)	19 (95.00)	(100.00)	(100.00)	7 (87.5)
	Per10HPF (20-30)	0 (0.00)	0 (0.00)	0 (0.00)	1 (12.50)
Ulcer	Per10HPF (30<)	1 (5.00)	0 (0.00)	0 (0.00)	0 (0.00)
			2	10	
	Absent	18 (90.00)	(100.00)	(100.00)	6 (75.00)
Keloid	Present (<1/3)	0 (0.00)	0 (0.00)	0 (0.00)	0 (0.00)
	Present (1/3-2/3)	2 (10.00)	0 (0.00)	0 (0.00)	2 (25.00)
	Present (2/3<)	0 (0.00)	0 (0.00)	0 (0.00)	0 (0.00)
Hypertrophic scar			2	10	
	Absent	19 (95.00)	(100.00)	(100.00)	7 (87.5)
Hypertrophic scar	Present	1 (5.00)	0 (0.00)	0 (0.00)	1 (12.50)
Keloid			2	10	
	Absent	20 (100.00)	(100.00)	(100.00)	8 (100.00)
Hypertrophic scar	Present	0 (0.00)	0 (0.00)	0 (0.00)	0 (0.00)
Hypertrophic scar			2	10	
	Absent	20 (100.00)	(100.00)	(100.00)	8 (100.00)
Hypertrophic scar	Present	0 (0.00)	0 (0.00)	0 (0.00)	0 (0.00)

Note: The numbers in parentheses represent the number of mice in each group. The duration of Cold Atmospheric Plasma intervention in minutes for G1, G2, and G3 is 0, 3, and 5 minutes, respectively.

cases, particularly in G3 (87.5%). Granulation tissue was mainly absent (90%), and when present, it exhibited a minimal extent (<33%) in G3. Blood vessel count per 10 high-power fields (Per10HPF) was mostly below 20, with G3 displaying a slightly higher count (87.5%). Fibroblasts were absent in 90% of cases, and when present, they were found in a minimal extent (<1/3) in G2 and G3. Ulcers were largely absent (95%), while keloids and hypertrophic scars were entirely absent in all cases.

#### *Histological evaluation of CAP therapy: Consistent responses in bilateral wound healing on day seven*

In this study evaluating the histological response to CAP therapy in rat wound healing on day seven, no significant differences were

observed between the left and right sides for key variables (Table 2). Neutrophil presence, although higher on the right side (70.59%) compared with the left (47.06%), did not reach statistical significance ( $P = 1.000$ ). Lymphocytes, predominantly absent on the left (76.47%), showed a notable presence on the right (52.94%), with no statistically significant difference ( $P = 1.000$ ). Granulation tissue, blood vessel count per 10 high-power fields (Per10HPF), fibroblast presence, ulcers, keloids, and hypertrophic scars demonstrated no significant left-right difference (Figure 1). The McNemar test results suggest a comparable histological response to CAP therapy between the left and right sides, emphasizing the consistency of the effects of treatment across different regions of the wound.

#### *Histological evaluation of CAP therapy:*

### Consistent responses in bilateral wound healing on day 14

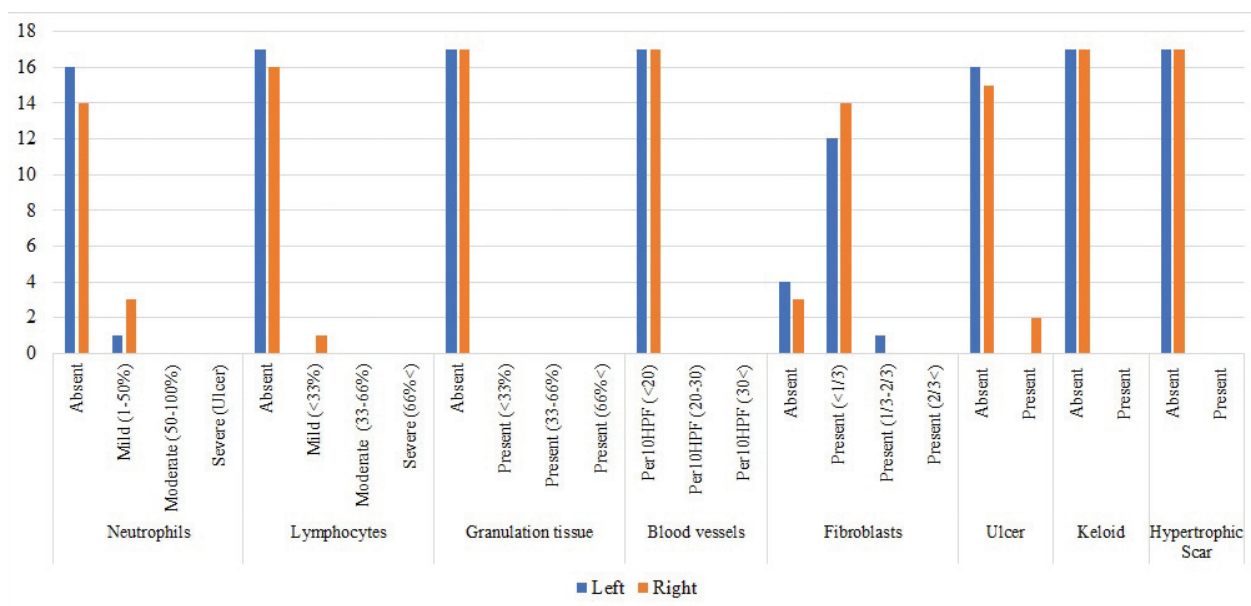
In this investigation of CAP therapy on rat wound healing at day fourteen, a comprehensive histological assessment was conducted to compare responses between the left and right sides (Table 3). The evaluation revealed no statistically significant differences in the distribution of key variables. Neutrophil presence exhibited a higher incidence on the left side (94.12%) compared with the right (82.35%), with unclear significant disparity ( $P$ =Not applicable). Lymphocytes, granulation tissue, and blood vessel count per Per10HPF showed complete consistency between the left and right sides, all registering 100.00% absence or presence (Figure 2). Fibroblast presence exhibited no significant difference ( $P$ =1.000), with similar proportions on both sides. Ulcers, keloids, and hypertrophic scars also demonstrated uniform responses, with no statistically significant differences observed.

### Discussion

CAP therapy was applied to rats to assess its impact on wound healing. Day zero analysis revealed an absence of acute inflammatory response, with neutrophils consistently absent

across all groups. Lymphocytes were predominantly absent, with a mild presence observed in most cases. Granulation tissue was mainly absent, and when present, it exhibited minimal extent. Blood vessel count was mostly below 20 per 10 high-power fields, with a slightly higher count in the 5 minute CAP intervention group. Fibroblasts were mostly absent, and when present, they were found in minimal extent. Ulcers, keloids, and hypertrophic scars were largely absent in all cases. Day seven and fourteen analyses revealed no significant differences between the left and right sides of the wounds for most variables. This suggests consistent effects of CAP therapy across different regions of the wound. There were some minor variations in neutrophil and fibroblast presence, but no statistically significant differences were observed.

Plasma medicine has emerged as an important subject in medical science in recent years. CAP has been shown to have anti-inflammatory, anti-microbial, and anti-neoplastic properties, as well as to help wound healing. However, some earlier studies showed that CAP therapy did not increase wound healing appreciably. The majority of these were chronic wounds rather than acute ones. Before using CAP on humans, it is critical that



**Figure 2.** This figure shows the histological comparison of left and right responses to cold atmospheric plasma therapy in rat wound healing on day 14.



**Table 2.** Histological comparison of left and right responses to CAP therapy in rat wound healing on day 7

Variables	Levels	Left	Right	P-value
Neutrophils	Absent	8 (47.06)	12 (70.59)	1.000
	Mild (1-50%)	8 (47.06)	4 (23.53)	
	Moderate (50-100%)	0 (0.00)	0 (0.00)	
	Severe (Ulcer)	1 (5.88)	1 (5.88)	
Lymphocytes	Absent 13 (76.47)	0 (0.00)	1.000	
	Mild (<33%)	4 (23.53)	9 (52.94)	
	Moderate (33-66%)	0 (0.00)	5 (29.41)	
	Severe (66%<)	0 (0.00)	0 (0.00)	
Granulation tissue	Absent	10 (58.82)	9 (52.94)	NA
	Present (<33%)	4 (23.53)	5 (29.41)	
	Present (33-66%)	2 (11.76)	1 (5.88)	
Blood vessels	Present (66%<)	1 (5.88)	2 (11.76)	NA
	Per10HPF (<20)	15 (88.24)	11 (64.71)	
	Per10HPF (20-30)	1 (5.88)	3 (17.65)	
	Per10HPF (30<)	1 (5.88)	3 (17.65)	
Fibroblasts	Absent	7 (41.18)	6 (35.29)	NA
	Present (<1/3)	5 (29.41)	3 (17.65)	
	Present (1/3-2/3)	5 (29.41)	5 (29.41)	
	Present (2/3<)	0 (0.00)	3 (17.65)	
Ulcer	Absent	15 (88.24)	15 (88.24)	NA
	Present	2 (11.76)	2 (11.76)	
Keloid	Absent	17 (100.00)	16 (100.00)	NA
	Present	0 (0.00)	0 (0.00)	
Hypertrophic scar	Absent	51 (0.00)	16 (100.00)	NA
	Present	0 (0.00)	0 (0.00)	

Note: Exact McNemar test was used to compare the left and right change in response to CAP therapy; CAP: Cold atmospheric plasma

we first determine its effects and safety in vivo.

In the present study, we looked at how this treatment affected angiogenesis, acute phase cells such neutrophils, lymphocytes, fibroblasts, granulation tissue, ulcer, scar or keloid formation in healthy rats.

Except for neutrophil count, none of the aforementioned variables were significantly affected in this study. This can be explained by the fact that CAP therapy can directly or indirectly generate Interleukin-8 (IL-8), a chemoattractant cytokine that attracts and activates neutrophils in inflammatory zones. It has already been proven that UVB irradiation causes an increase in IL-8. The production of interleukin (IL)-8 was significantly increased, as was the development of neutrophil extracellular traps (NETs), which may be advantageous to microbial control, which is thought to be the primary application of CAP. However, the efficacy of these NETs has not yet been confirmed.

In keeping with prior research, no significant relationship between CAP and lymphocyte count was discovered. Ma et al. found no significant

difference in the release of lymphocyte-secreted cytokines in resting peripheral blood mononuclear cells (PBMC), which include monocytes and lymphocytes.<sup>15</sup> On the contrary, Cong et al.<sup>16</sup> examined in 2021 the impact of cold atmospheric Argon plasma on alterations in macrophages in burn injuries. They showed that cold plasma induces M2 macrophages or anti-inflammatory macrophages by its ROS and increases fibroblast migration, which are the leading causes of wound healing promotion. A year later, Jonas et al. looked into how CAP improved growth factors in diabetic wounds that were chronic.<sup>17</sup> Their findings demonstrated that plasma induces wounds to transcend their chronic states by stimulating macrophages involved in the inflammatory response.

There is level 1 evidence in some studies, such as the Tehranian study on surgical scars, that autologous platelet preparations may improve wound healing and scar quality at eight weeks, and mediate a reduction in postoperative pain following a Caesarean section; however, short follow-up in this study does not provide an

**Table 3.** Histological comparison of left and right responses to CAP therapy in rat wound healing on day 14

Variables	Levels	Left	Right	P-value
Neutrophils	Absent	16 (94.12)	14 (82.35)	NA
	Mild (1-50%)	1 (5.88)	3 (17.65)	
	Moderate (50-100%)	0 (0.00)	0 (0.00)	
	Severe (Ulcer)	0 (0.00)	0 (0.00)	
Lymphocytes	Absent	17 (100.00)	16 (94.12)	NA
	Mild (<33%)	0 (0.00)	1 (5.88)	
	Moderate (33-66%)	0 (0.00)	0 (0.00)	
	Severe (66%<)	0 (0.00)	0 (0.00)	
Granulation tissue	Absent	17 (100.00)	17 (100.00)	NA
	Present (<33%)	0 (0.00)	0 (0.00)	
	Present (33-66%)	0 (0.00)	0 (0.00)	
	Present (66%<)	0 (0.00)	0 (0.00)	
	Per10HPF (<20)	17 (100.00)	17 (100.00)	
Blood vessels	Per10HPF (20-30)	0 (0.00)	0 (0.00)	NA
	Per10HPF (30<)	0 (0.00)	0 (0.00)	
Fibroblasts	Absent	4 (23.53)	3 (17.65)	1.000
	Present (<1/3)	12 (70.59)	14 (82.35)	
	Present (1/3-2/3)	1 (5.88)	0 (0.00)	
	Present (2/3<)	0 (0.00)	0 (0.00)	
Ulcer	Absent	16 (94.12)	15 (88.24)	NA
	Present	0 (0.00)	2 (11.76)	
Keloid	Absent	17 (100.00)	17 (100.00)	NA
	Present	0 (0.00)	0 (0.00)	
Hypertrophic scar	Absent	17 (100.00)	17 (100.00)	NA
	Present	0 (0.00)	0 (0.00)	

Note: Exact McNemar test was used to compare the left and right change in response to CAP therapy; CAP: Cold atmospheric plasma; NA: Not applicable

indication of the possible contribution of PRP towards better long term scar quality.<sup>18</sup> Ours, using a CAP on the other hand, had no discernible influence on scar or keloid formation.

In addition, 6 month follow-ups in their study revealed a considerable improvement in texture, color, and scar outlines.

Vascularization is also a component of post-operative recovery and one of the defining characteristics of wound healing in general. Angiogenesis should be promoted in order to improve wound healing. Angiogenesis can be stimulated by a variety of substances including the growth factor, vascular endothelial growth factor (VEGF), fibroblast growth factors (FGF), cytokines, ROS, and nitric oxide (NO). Reports show that CAPs, by their reactive species and UV radiations, can increase growth factors such as FGF-2 and VEGF in diabetic wounds and in this way help angiogenesis and, thereby wound healing.<sup>18,19</sup>

As previously stated, our study found no significant influence on fibroblast count. However, it can be stated that this impact may appear in

subsequent follow-ups. Because an increased number of neutrophils can produce reactive nitrogen species such as nitric oxide, which can improve angiogenesis. Considering that this method is a new treatment, we recommend it to be carried out in studies with a larger number to check its safety.

## Conclusion

This study summarized research on the influence of cold atmospheric pressure plasma on acute wound healing. These investigations are the first steps toward more widespread use of this medication for wound care in patients. In keeping with previous studies, no negative side effects were discovered, and the antiseptic and reproductive effects of this medication are being addressed. However, there are certain concerns that need to be solved before adopting this technology substantially in post operative wound therapy, such as when is the optimal time to treat and which aspects of a wound respond best to CAP.

## Acknowledgements

None declared.

## Funding

None declared.

## Authors' Contribution

A.A: Study design, Drafting and reviewing the manuscript; M.B-R: Study design, Reviewing the manuscript, Providing equipment and plasma device; D.N: Data gathering, drafting the manuscript, reviewing the manuscript ; M.A-L: Data Analysis and interpretation, reviewing the manuscript ; A.M: Data interpretation; reviewing the manuscript M.B: Data gathering, reviewing the manuscript; F.A: Data gathering, reviewing the manuscript; B.Kh: Data Analysis and interpretation, reviewing the manuscript; M-E.A: Study design, Reviewing the manuscript; All authors have read and approved the final manuscript and agree to be accountable for all aspects of the work in ensuring that questions related to the accuracy or integrity of any part of the work are appropriately investigated and resolved.

## Conflict of Interest

None declared.

## References

- Boeckmann L, Schäfer M, Bernhardt T, Semmler ML, Jung O, Ojak G, et al. Cold atmospheric pressure plasma in wound healing and cancer treatment. *Appl Sci*. 2020;10(19):6898. doi: 10.3390/app10196898.
- Garner AL, Mehlhorn TA. A review of cold atmospheric pressure plasmas for trauma and acute care. *Front Phys*. 2021;9:774. doi: 10.3389/fphy.2021.786381.
- Bender C, Partecke LI, Kindel E, Döring F, Lademann J, Heidecke CD, et al. The modified HET-CAM as a model for the assessment of the inflammatory response to tissue tolerable plasma. *Toxicol In Vitro*. 2011;25(2):530-7. doi: 10.1016/j.tiv.2010.11.012.
- Klämpfl TG, Isbary G, Shimizu T, Li YF, Zimmermann JL, Stolz W, et al. Cold atmospheric air plasma sterilization against spores and other microorganisms of clinical interest. *Appl Environ Microbiol*. 2012;78(15):5077-82. doi: 10.1128/AEM.00583-12.
- Lademann O, Kramer A, Richter H, Patzelt A, Meinke MC, Roewert-Huber J, et al. Antisepsis of the follicular reservoir by treatment with tissue-tolerable plasma (TTP). *Laser Phys Lett*. 2011;8(4):313. doi: 10.1002/lapl.201010123.
- Lademann O, Richter H, Meinke MC, Patzelt A, Kramer A, Hinz P, et al. Drug delivery through the skin barrier enhanced by treatment with tissue-tolerable plasma. *Exp Dermatol*. 2011;20(6):488-90. doi: 10.1111/j.1600-0625.2010.01245.x.
- Shimizu T, Zimmermann J, Morfill G. The bactericidal effect of surface micro-discharge plasma under different ambient conditions. *New J Phys*. 2011;13(2):023026. doi: 10.1088/1367-2630/13/2/023026.
- Kalghatgi S, Friedman G, Fridman A, Clyne AM. Endothelial cell proliferation is enhanced by low dose non-thermal plasma through fibroblast growth factor-2 release. *Ann Biomed Eng*. 2010;38(3):748-57. doi: 10.1007/s10439-009-9868-x.
- Nosenko T, Shimizu T, Morfill G. Designing plasmas for chronic wound disinfection. *New J Phys*. 2009;11(11):115013. doi:10.1088/1367-2630/11/11/115013.
- Pompl R, Jamitzky F, Shimizu T, Steffes B, Bunk W, Schmidt HU, et al. The effect of low-temperature plasma on bacteria as observed by repeated AFM imaging. *New J Phys*. 2009;11(11):115023. doi:10.1088/1367-2630/11/11/115023.
- Tipa RS, Kroesen GM. Plasma-stimulated wound healing. *IEEE Trans Plasma Sci*. 2011;39(11):2978-9. doi:10.1109/TPS.2011.2159868.
- Braný D, Dvorská D, Halašová E, Škovierová H. Cold Atmospheric plasma: A powerful tool for modern medicine. *Int J Mol Sci*. 2020;21(8):2932. doi: 10.3390/ijms21082932. PMID: 32331263; PMCID: PMC7215620.
- Boekema B, Stoop M, Vlig M, van Liempt J, Sobota A, Ulrich M, et al. Antibacterial and safety tests of a flexible cold atmospheric plasma device for the stimulation of wound healing. *Appl Microbiol Biotechnol*. 2021;105(5):2057-70. doi: 10.1007/s00253-021-11166-5. PMID: 33587156; PMCID: PMC7906937.
- Assadian O, Ousey KJ, Daeschlein G, Kramer A, Parker C, Tanner J, et al. Effects and safety of atmospheric low-temperature plasma on bacterial reduction in chronic wounds and wound size reduction: A systematic review and meta-analysis. *Int Wound J*. 2019;16(1):103-11. doi: 10.1111/iwj.12999. PMID: 30311743; PMCID: PMC7379569.
- Ma Y, Sun T, Ren K, Min T, Xie X, Wang H, et al. Applications of cold atmospheric plasma in immune-mediated inflammatory diseases via redox homeostasis: evidence and prospects. *Heliyon*. 2023;9(12):e22568. doi: 10.1016/j.heliyon.2023.e22568. PMID: 38107323; PMCID: PMC10724573.
- Dang CP, Weawseetong S, Charoensappakit A, Sae-Khow K, Thong-Aram D, Leelahavanichkul A. Non-thermal atmospheric pressure argon-sourced



- plasma flux promotes wound healing of burn wounds and burn wounds with infection in mice through the anti-inflammatory macrophages. *Appl Sci*. 2021;11:5343. doi:10.3390/app11125343.
17. Hiller J, Stratmann B, Timm J, Costea TC, Tschoepe D. Enhanced growth factor expression in chronic diabetic wounds treated by cold atmospheric plasma. *Diabet Med*. 2022;39(6):e14787. doi: 10.1111/dme.14787. PMID: 35007358.
  18. Tehranian A, Esfehni-Mehr B, Pirjani R, Rezaei N, Sadat Heidary S, Sepidarkish M. Application of Autologous Platelet-Rich Plasma (PRP) on wound healing after caesarean section in high-risk patients. *Iran Red Crescent Med J*. 2016;18(7):e34449. doi: 10.5812/ircmj.34449. PMID: 27660723; PMCID: PMC5027131.
  19. Barjasteh A, Kaushik N, Choi EH, Kaushik NK. Cold atmospheric pressure plasma: A growing paradigm in diabetic wound healing-mechanism and clinical significance. *Int J Mol Sci*. 2023;24(23):16657. doi: 10.3390/ijms242316657. PMID: 38068979; PMCID: PMC10706109.