

Original Article

Running Title: Diffusion Imaging in Rectal Cancer

Received: April 26, 2021; Accepted: September 28, 2021

Role of DW-MRI in Predicting Pathologic Complete Response after Neoadjuvant Chemoradiation in Patients with Rectal Cancer

Ali Yaghobi Joybari^{*}, MD, Fariba Jozian^{*♦}, MD, Sam Alahyari^{**}, MD, Saeed Nasiri^{***}, MD, Majid Samsami^{****}, MD, Saleh Sandoughdaran^{*}, MD

^{*}*Department of Radiation Oncology, Faculty of Medicine, Shahid Beheshti University of Medical Sciences, Tehran, Iran*

^{**}*Faculty of Medicine, Shahid Beheshti University of Medical Sciences, Tehran, Iran*

^{***}*Department of Radiology, Faculty of Medicine, Shahid Beheshti University of Medical Sciences, Tehran, Iran*

^{****}*Department of General Surgery, Shahid Beheshti University of Medical Sciences, Tehran, Iran*

♦Corresponding Author

Fariba Jozian, MD

Department of Radiation Oncology,

Faculty of Medicine,

Shahid Beheshti University of Medical Sciences, Tehran, Iran

Email: f.jozian@gmail.com

Abstract

Background: Following neoadjuvant chemoradiation, 25% of patients with rectal cancer experience pathologic complete response (pCR). With the appropriate imaging method for this group of patients, it would be possible to use less invasive methods. The aim of this study was to assess the ability of diffusion-weighted magnetic resonance imaging to predict pCR after neoadjuvant chemoradiation in patients with rectal cancer.

Method: In this prospective study, 19 patients with rectal cancer were examined. Magnetic resonance imaging of patients with diffusion-weighted imaging was performed in two stages: one week before the start of chemoradiotherapy (CRT) and seven weeks after the end of CRT to evaluate the results of treatment. Apparent diffusion coefficient (ADC) was measured before and after treatment. The percentage of ADC (% Δ ADC) increment was also calculated. The patients were divided into three groups according to the surgical report: complete responders, partial responders, and non-responders. Optimal cut-off point was determined via ROC diagram.

Results: The mean age of the patients was 52.9 (29-73) years. There were no significant associations between pre and postoperative ADC values and pCR. However, % Δ ADC had a significant relationship with complete response to treatment. Based on the ROC chart, the value of 15% was selected as cut-off with 56% specificity and 67% sensitivity. The positive and negative predicting values were 77.8% and 40%, respectively.

Conclusion: The mean % Δ ADC increase seems to be a valid tool to differentiate complete responders from non-responders after CRT in locally advanced rectal cancer.

Keywords: Rectum neoplasms, Chemoradiotherapy, Apparent diffusion coefficient, Diffusion magnetic resonance imaging, Neoadjuvant treatment

Introduction

According to the National Cancer Registry of Iran, colorectal cancer is the fifth most common cancer among men and the third most common cancer among women.¹ In Western countries, such as the United States, rectal cancer accounts for about 25-30% of all colorectal cancers,² but in Iran, about 40-50% of all colorectal cancers originate in the rectum.¹ Age is one of the major risk factors for rectal cancer. In various studies, the peak age of this cancer has been mentioned for about 50 years.³ Surgery is an approved treatment for advanced stages of rectal cancer. Over the past decade, standard treatment for advanced rectal cancer has shifted from postoperative chemotherapy to preoperative chemotherapy and radiotherapy. Neoadjuvant chemoradiotherapy (CRT) have advantages, such as pathologic complete response (pCR), reduction of disease stage, and local control.⁴ It also reduces the need for surgery and increases sphincter preservation.⁵ Pathological improvement has been confirmed in 20%-30% of patients treated with CRT. Given that CRT treatment is a controversial issue, researchers have reported long-term positive outcomes in patients with advanced rectal cancer, who have received a complete clinical response.⁶ To evaluate the response to CRT, accurate imaging techniques are required and magnetic resonance imaging (MRI) is often employed for this purpose.⁷ Common MRI imaging cannot be used to predict a complete response to CRT.⁸ Diffusion-weighted magnetic resonance imaging (DW-MRI) has been applied for diagnosing rectal masses since the 1990s. In recent years, researchers have utilized this technique to determine the effectiveness of CRT treatment in locally advanced rectal cancers.⁹⁻¹⁰ DW-MRI imaging shows cellularity of the evaluated tissue. As a result, this type of imaging plays a very

important role in oncological evaluations and has been proposed as the primary method of evaluation after neoadjuvant treatment. Following neoadjuvant CRT, the morphology of normal intestinal tissue is affected by fibrosis and it will be very difficult to detect residual tumor tissue with conventional MRI in T2 images. Primary therapeutic responses occur at the cellular level with a decrease in the rate of cell proliferation or an increase in apoptosis and a decrease in microvasculature. These indices are identified by an increase in tumor apparent diffusion coefficient (ADC). Therefore, DW-MRI can quantitatively differentiate the remaining tumor from fibrosis.¹¹ According to studies, the prediction of pCR in patients with rectal cancer with CRT treatment with DW-MRI clinical method in Iran has not been determined. To this end, this study was performed.

Materials and Methods

In this diagnostic, prospective study, from May 2016 to October 2017, patients with rectal cancer, who were referred to Imam Hossein Hospital, were examined. Inclusion criteria were rectal carcinoma in pathology, T3-4 stage, lymph node involvement, no previous treatment or surgery, lack of metastasis, and surgery after CRT. Exclusion criteria were pathology other than adenocarcinoma, metastatic patients, recurrent rectal cancer, any contraindications to chemotherapy and radiotherapy, and out-of-center treatment. Neoadjuvant CRT was carried out with a dose of 45 Gy, 23-25 fractions, with 18-10 mv photon, external radiotherapy to the tumor, and loco regional areas, including the internal iliac lymph nodes and presacral with a boost to a maximum of 50.4 Gy to the tumor, and capecitabine 825 mg / m² twice daily simultaneously. After CRT, the patients underwent surgery. MRI of the

patients was performed through DW imaging. MRI with 1.5 Tesla (Magnetom Avanto; Siemens Medical Solutions, Erlangen, Germany) was carried out on T1 weighted and T2 weighted sections and at b-value of $800 \text{ s} / \text{mm}^2$. All the patients received MRI twice: 1-One week before the start of CRT to evaluate tumor stage and disease and lymph node and 2-seven weeks after the end of CRT to check the results of treatment. The patients' imaging was interpreted by an experienced radiologist. After surgery, the patients who had no invasive tumor in the tissue sample were placed in the pCR group and those who had an invasive tumor in the tissue sample were placed in the partial response or no response group. In addition to MRI results (including tumor stage, lymphatic stage, disease stage, ADC number), pathology results and some demographic information, including age and sex of patients, were recorded. The increase in the ADC was calculated from the formula (Average post-CRT ADC - Average pre-CRT ADC value) / Average pre-CRT ADC value.

Ethical statement

The study was performed in accordance with Declaration of Helsinki and was approved by the Ethical Committee of Shahid Beheshti University of Medical Sciences (ethical code: IR.SBMU.MSP.REC.1397.99).

The patients were given a full explanation of the study and a written consent was obtained.

Statistical analysis

All the statistical analyses were performed with SPSS software. Quantitative data description was conducted using mean (standard deviation) and qualitative data by number (percentage). Kolmogorov-Smirnov, Shapiro-Wilk tests, and visual inspection of histograms were employed to investigate the normal distribution of data. T-test was used to compare the pathology and imaging

results and non-parametric data were analyzed through Mann-Whitney U test. We also utilized receiver operating characteristic (ROC) curve applied to examine the ADC number capability in pCR prediction and after determining the appropriate cut-off, the diagnostic coefficients of the ADC number, including sensitivity, specificity, positive predicting value, negative predicting value, and accuracy, were determined. $P < 0.05$ was considered significant.

Results

Initially, 21 patients were included in the study. During the study, one patient was excluded due to a desire to continue treatment at another center and one patient due to metastasis after neoadjuvant treatment. The mean age among the 19 patients (10 males and 9 females) was 52.9 years and ranged from 29 to 73 years. Table 1 shows the clinical and pathologic characteristics of patients. In terms of tumor location, 11 patients had a lower rectum, six patients had a middle rectum, and two patients had an upper rectum tumor. All the patients underwent surgery after CRT. The surgical type was abdominal perineal resection in four patients (21.1%) and low anterior resection in 15 patients (78.9%).

All the patients underwent MRI one week before the start of treatment. Second MRI was performed seven weeks after the end of CRT to evaluate the response to treatment. The response to treatment was evaluated in both radiological and pathological forms. In radiological examinations, four patients (21.1%) had complete response (CR) (Figure 1). After surgery and pathological examinations, it was found that six patients (31.6%) had pCR and 13 patients (68.4%) had a partial response. In one patient, the radiological evaluation and pathology results were the same for CR. No progressive diseases were reported in any of the patients. Circumferential resection margin (CRM) involvement was reported in seven patients (36.8%) following CRT. CRM involvement was negative in all the patients after surgery.

There were no significant relationships between the radiological response and the pathological response of the patients ($P > 0.05$).

Quantitative analysis: Mean ADC levels in pre- and post-CRT DW-MRIs were 0.77×10^{-3} and 0.96×10^{-3} , respectively. In addition, the difference between the two ADCs (Δ ADC) was 33%. Although there was no significant relationship between pre- and post-CRT ADCs and pCR, % Δ ADC had a significant association with complete response to treatment ($P = 0.04$). The mean ADC before CRT, after CRT, and Δ ADC in patients with complete response and partial response are represented in table 2. The mean ADC was generally higher after CRT than the pre-CRT ADC and the rate of increase was higher than of those in patients with partial response.

Appropriate cut-off: The AUC of the ROC curve was reported to be 0.692. Based on the ROC diagram, the value of 15%, with a specificity of %56 and sensitivity of %67, was considered as the appropriate cut-off point. Positive and negative predicting values were 77.8% and 40%, respectively.

Discussion

We investigated the value of using Diffusion Weighted Imaging to examine the response to treatment in patients with rectal cancer. 19 patients with rectal cancer underwent neoadjuvant chemotherapy and then surgery. Although there was no significant relationship between pre- and post-CRT ADCs with pCR, it was observed that there is a significant correlation between Δ ADC and pCR. A cut-off with appropriate predictive values was also determined.

Colorectal cancer is the fourth most common cancer and the third leading cause of cancer death. Rectal cancer is the eighth most common cancer in the world.¹²⁻¹³ In the patients with locally advanced rectal cancer, surgery is the main treatment and extensive

surgery can be avoided if the patients who benefit from minor surgery are identified. Preoperative treatment is now applied as part of standard treatment for these patients, but it may affect the accuracy of staging procedures.¹⁴ Various studies have also been conducted to find the predictors of response to neoadjuvant therapy.¹⁵ Rectal MRI may be valuable in patient care in different circumstances. Before surgery, MRI can assist physicians in three stages (a) selecting patients with rectal cancer who can benefit from neoadjuvant treatment; (b) assisting surgeons to choose the best type of surgery for patients; and (c) recognizing poor prognostic factors, including involvement of the mesorectal fascia, extramural vascular invasion, and mucin content.¹⁶⁻¹⁷ Following neoadjuvant CRT, rectal MRI can assist in (a) the assessment of tumor regression; (b) tailoring surgical planning; (c) detecting a complete clinical response, in which the digital rectal examinations and endoscopic procedures are helpful; and (d) monitoring nonsurgical treatment in patients.¹⁸ Although MRI today is an appropriate way to stage advanced rectal cancers, it is poor at evaluating the response to treatment and it is not easy to distinguish necrotic tissue from living tissue. One of the methods utilized to enhance MRI images accuracy is Diffusion Weighted Imaging.¹⁹ In this method, based on the diffusion of water among the intracellular molecules, a precise image of the tumor is obtained and the difference in water diffusion can show contrast in order to differentiate the tumor from normal tissue. Cancer tissue, due to its higher density, has a higher emission limit compared to non-cancerous tissue; hence, it is possible to differentiate cancerous tissue from non-cancerous tissue.²⁰

In this study the pCR rate and the mean ADC before and after chemotherapy were assessed. No significant relationship

between pre-CRT ADC and pCR was found in the current work. This result was similar to those of several studies.²¹⁻²² However, Chen et al. found that the amount of ADC before and after CRT was significantly different in pCR patients and non-pCR patients ($P = 0.003$ and $P < 0.001$ respectively).²³ In a study by Sun et al., performed on 37 patients, the mean pre-CRT ADC in the group with a tumor down staging was significantly lower than that of the patients who did not respond to treatment.²⁴ One of the reasons for these differences is the difference in the definition of response to treatment in various studies. DeVries, for example, has employed tumor shrinkage (50% reduction in tumor size) as response to treatment. In a study by Sun et al., The down staging of the tumor was the criterion for response. In addition, the evaluated population in these studies was generally low and no extensive research has been conducted in this field. It was also found that ADC levels after CRT were not significantly associated with pCR ($P = 0.15$). Similar results were obtained in several other studies.²⁵ However, these results were inconsistent with studies reporting significant differences in ADC levels after CRT in pCR and non-pCR patients.^{21, 26} Meanwhile, these studies reported a low value for ADC after chemotherapy in predicting pCR. One of the reasons for this could be the overlap of ADC in pCR and near pCR patients. In our work, it was found that the rate of $\% \Delta \text{ADC}$ was significantly associated with the response to treatment ($P = 0.04$). Based on the ROC chart, the sensitivity and specificity of this variable in pCR prediction with a cut-off value of 15% were calculated as 67% and 56%, respectively. $\Delta \text{ADC}\%$ has been introduced in numerous studies as a factor for predicting pCR.²⁷⁻²⁸ Moreover, in a meta-analysis, $\Delta \text{ADC}\%$ was identified as the strongest predictor of pCR in locally

advanced rectal cancer.²⁹ In calculating the sensitivity and specificity of $\Delta \text{ADC}\%$, a significant difference between various studies is observed due to various factors, the most relevant of which seems to be the definition of responder group (pCR or downstaging). Other factors, such as magnetic field strength and MR imaging protocol (different b values), scanners, coil systems, different ADC measurement methods along with study population and design, and operator dependence on ROI positioning, should also be taken into account.

This study has several limitations. First, the number of the studied patients small and perhaps with the increase in the number of patients, a significant relationship could be found between ADC after CRT and response to treatment. In addition, although the ADC was reported by an expert radiologist, several studies have used reports from two radiologists to prevent possible errors.

Conclusion

Based on the results of this research, the level of ADC before and after CRT in patients with rectal cancer is not significantly associated with a complete pathological response. However, the percentage of ADC increment has a significant association with the complete pathological response of the tumor and can be employed as a predictive factor in response to treatment. Therefore, it seems that this factor can be used to predict the response to neoadjuvant chemoradiation and complications of this treatment in patients with a low probability of pCR can be avoided. Meanwhile, studies with more patients are needed to evaluate this relationship more accurately.

Acknowledgements

We would like to acknowledge all the patients who participated in this study.

Conflict of Interest

None declared.

References

1. Azadeh S, Moghimi-Dehkordi B, Fatem S, Pourhoseingholi M, Ghiasi S, Zali M. Colorectal cancer in Iran: an epidemiological study. *Asian Pac J Cancer Prev.* 2008 ; 9(1):123-6.
2. Siegel RL, Miller KD, Jemal A. Cancer statistics, 2020. *CA Cancer J Clin.* 2020;70(1):7-30. doi: 10.3322/caac.21590.
3. Saraste D, Järås J, Martling A. Population-based analysis of outcomes with early-age colorectal cancer. *Br J Surg.* 2020; 107(3):301-309. doi: 10.1002/bjs.11333.
4. Nacion A, Park Y, Kim N. Contemporary management of locally advanced rectal cancer: resolving issues, controversies and shifting paradigms. *Chin J Cancer Res.* 2018; 30(1):131-46. doi: 10.21147/j.issn.1000-9604.2018.01.14.
5. Clermonts SHEM, Köeter T, Pottel H, Stassen LPS, Wasowicz DK, Zimmerman DDE. Outcomes of completion total mesorectal excision are not compromised by prior transanal minimally invasive surgery. *Colorectal Dis.* 2020;22(7):790-8. doi: 10.1111/codi.14962.
6. Lorimer PD, Motz BM, Kirks RC, Boselli DM, Walsh KK, Prabhu RS, et al. Pathologic complete response rates after neoadjuvant treatment in rectal cancer: an analysis of the national cancer database. *Ann Surg Oncol.* 2017; 24(8):2095-103. doi: 10.1245/s10434-017-5873-8.
7. Maas M, Lambregts DM, Nelemans PJ, Heijnen LA, Martens MH, Leijtens JW, et al. Assessment of clinical complete response after chemoradiation for rectal cancer with digital rectal examination, endoscopy, and MRI: selection for organ-saving treatment. *Ann Surg Oncol.* 2015; 22(12):3873-80. doi: 10.1245/s10434-015-4687-9.
8. Gollub M, Gultekin D, Akin O, Do R, Fuqua J, Gonen M, et al. Dynamic contrast enhanced-MRI for the detection of pathological complete response to neoadjuvant chemotherapy for locally advanced rectal cancer. *Eur Radiol.* 2012; 22(4):821-31. doi: 10.1007/s00330-011-2321-1.
9. Dzik-Jurasz A, Domenig C, George M, Wolber J, Padhani A, Brown G, et al. Diffusion MRI for prediction of response of rectal cancer to chemoradiation. *Lancet.* 2002;360(9329):307-8. doi: 10.1016/S0140-6736(02)09520-X.
10. Joye I, Deroose CM, Vandecaveye V, Haustermans K. The role of diffusion-weighted MRI and 18F-FDG PET/CT in the prediction of pathologic complete response after radiochemotherapy for rectal cancer: a systematic review. *Radiother Oncol.* 2014;113(2):158-65. doi: 10.1016/j.radonc.2014.11.026.
11. Musio D, De Felice F, Magnante AL, Ciolina M, De Cecco CN, Rengo M, et al. Diffusion-weighted magnetic resonance application in response prediction before, during, and after neoadjuvant radiochemotherapy in primary rectal cancer carcinoma. *Biomed Res Int.* 2013; 2013:740195. doi: 10.1155/2013/740195.
12. Bray F, Ferlay J, Soerjomataram I, Siegel RL, Torre LA, Jemal A. Global cancer statistics 2018: GLOBOCAN estimates of incidence and mortality worldwide for 36 cancers in 185 countries. *CA Cancer J Clin.* 2018;68(6):394-424. doi: 10.3322/caac.21492. Erratum in: *CA Cancer J Clin.* 2020;70(4):313.
13. Rawla P, Sunkara T, Barsouk A. Epidemiology of colorectal cancer: incidence, mortality, survival, and risk factors. *Prz Gastroenterol.* 2019; 14(2):89-103. doi: 10.5114/pg.2018.81072.
14. Sun Y, Zhang Y, Wu X, Lin H, Lu X, Huang Y, et al. Prognostic significance of neoadjuvant rectal score in locally advanced rectal cancer after neoadjuvant chemoradiotherapy and

construction of a prediction model. *J Surg Oncol.* 2018;117(4):737-44. doi: 10.1002/jso.24907.

15. Malekzadeh Moghani M, Alahyari S, Moradi A, Nasiri M. Pathological predictors of response to neoadjuvant treatment in rectal carcinoma. *J Gastrointest Cancer.* 2021;52(2):690-695. doi: 10.1007/s12029-020-00450-8.

16. Patel UB, Taylor F, Blomqvist L, Christopher George, Hywel Evans, Paris Tekkis, et al. Magnetic resonance imaging-detected tumor response for locally advanced rectal cancer predicts survival outcomes: MERCURY experience. *J Clin Oncol.* 2011;29(28):3753-60. doi: 10.1200/JCO.2011.34.9068.

17. Taylor FG, Swift RI, Blomqvist L, Brown G. A systematic approach to the interpretation of preoperative staging MRI for rectal cancer. *AJR Am J Roentgenol.* 2008; 191(6):1827-35. doi: 10.2214/AJR.08.1004.

18. Horvat N, Carlos Tavares Rocha C, Clemente Oliveira B, Petkovska I, Gollub MJ. MRI of rectal cancer: Tumor staging, imaging techniques, and management. *Radiographics.* 2019;39(2):367-87. doi: 10.1148/rg.2019180114.

19. Monguzzi L, Ippolito D, Bernasconi DP, Trattenero C, Galimberti S, Sironi S. Locally advanced rectal cancer: value of ADC mapping in prediction of tumor response to radiochemotherapy. *Eur J Radiol.* 2013; 82(2):234-40. doi: 10.1016/j.ejrad.2012.09.027.

20. White NS, McDonald C, Farid N, Kuperman J, Karow D, Schenker-Ahmed NM, et al. Diffusion-weighted imaging in cancer: physical foundations and applications of restriction spectrum imaging. *Cancer Res.* 2014; 74(17):4638-52. doi: 10.1158/0008-5472.CAN-13-3534.

21. Kim YC, Lim JS, Keum KC, Kim KA, Myoung S, Shin SJ, et al. Comparison of diffusion-weighted MRI and MR volumetry

in the evaluation of early treatment outcomes after preoperative chemoradiotherapy for locally advanced rectal cancer. *J Magn Reson Imaging.* 2011; 34(3):570-6. doi: 10.1002/jmri.22696.

22. DeVries AF, Kremser C, Hein PA, Griebel J, Krezcy A, Öfner D, et al. Tumor microcirculation and diffusion predict therapy outcome for primary rectal carcinoma. *Int J Radiat Oncol Biol Phys.* 2003;56(4):958-65. doi: 10.1016/s0360-3016(03)00208-6.

23. Chen YG, Chen MQ, Guo YY, Li SC, Wu JX, Xu BH. Apparent diffusion coefficient predicts pathology complete response of rectal cancer treated with neoadjuvant chemoradiotherapy. *PLoS One.* 2016; 11(4):e0153944. doi: 10.1371/journal.pone.0153944.

24. Sun YS, Zhang XP, Tang L, Ji JF, Gu J, Cai Y, et al. Locally advanced rectal carcinoma treated with preoperative chemotherapy and radiation therapy: preliminary analysis of diffusion-weighted MR imaging for early detection of tumor histopathologic downstaging. *Radiology.* 2010; 254(1):170-8. doi: 10.1148/radiol.2541082230.

25. Doi H, Beppu N, Kato T, Noda M, Yanagi H, Tomita N, et al. Diffusion-weighted magnetic resonance imaging for prediction of tumor response to neoadjuvant chemoradiotherapy using irinotecan plus S-1 for rectal cancer. *Mol Clin Oncol.* 2015; 3(5):1129-34. doi: 10.3892/mco.2015.604.

26. Genovesi D, Filippone A, Cefaro GA, Trignani M, Vinciguerra A, Augurio A, et al. Diffusion-weighted magnetic resonance for prediction of response after neoadjuvant chemoradiation therapy for locally advanced rectal cancer: preliminary results of a monoinstitutional prospective study. *Eur J Surg Oncol.* 2013; 39(10):1071-8. doi: 10.1016/j.ejso.2013.07.090.

27. Foti PV, Privitera G, Piana S, Palmucci S, Spatola C, Bevilacqua R, et al. Locally

advanced rectal cancer: qualitative and quantitative evaluation of diffusion-weighted MR imaging in the response assessment after neoadjuvant chemoradiotherapy. *Eur J Radiol Open*. 2016;3:145-52. doi: 10.1016/j.ejro.2016.06.003.

28. Lee EM, Hong YS, Kim KP, Lee JL, Kim SY, Park YS, et al. Phase II study of preoperative chemoradiation with S-1 plus

oxaliplatin in patients with locally advanced rectal cancer. *Cancer Sci*. 2013;104(1):111-5. doi: 10.1111/cas.12041.

29. Xie H, Zhou X, Zhuo Z, Che S, Xie L, Fu W. Effectiveness of MRI for the assessment of mesorectal fascia involvement in patients with rectal cancer: a systematic review and meta-analysis. *Dig Surg*. 2014;31(2):123-34. doi: 10.1159/000363075.

Table 1. Clinicopathologic factors of patients

Clinicopathologic Factors	Number (n=19)	%
Male	10	52.6
Female	9	47.4
Tumor location		
lower	11	57.9
Mid	6	36.6
Upper	2	10.5
MRF		
Positive	18	94.7
Negative	1	5.3
T Stage		
T3	8	42.1
T4	11	57.9
N Stage		
N0	1	5.3
N1	3	15.8
N2	15	78.9

MRF: Mesorectal fascia

Table 2. Relationship between ADC and pathologic complete response

	Pathologic response	N	Mean	Standard Deviation	Standard Error Mean	P-value
Preoperative ADC	Partial	13	0.73992	0.179782	0.049862	0.18
	Complete	6	0.84633	0.073921	0.030178	
Postoperative ADC	Partial	13	0.99985	0.242166	0.067165	0.15
	Complete	6	0.88900	0.073179	0.029875	
Δ ADC	Partial	13	45.7151	62.65639	17.37775	0.04
	Complete	6	5.8196	13.58303	5.54525	

ADC: Apparent diffusion coefficient

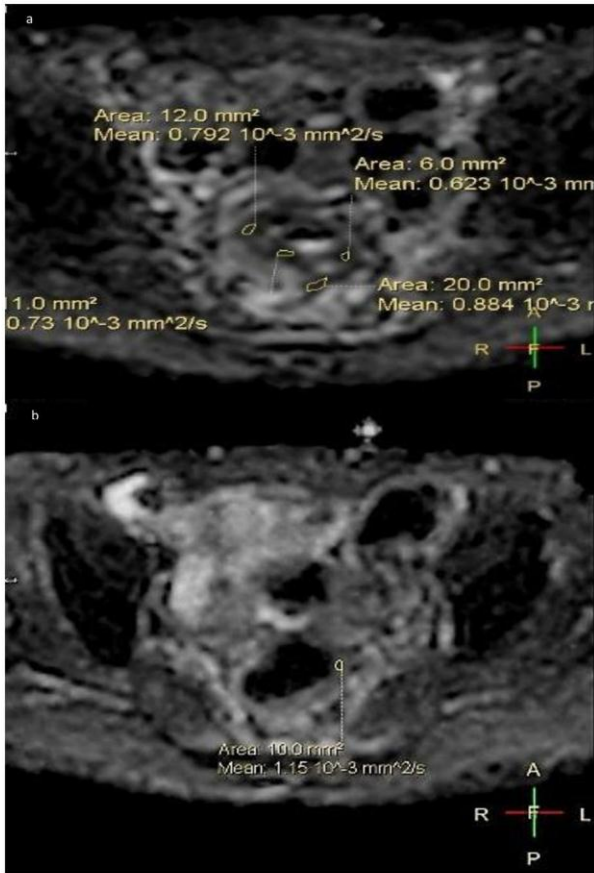


Figure 1. Diffusion imaging of a representative 57-year-old patient with rectal tumor, a) before neoadjuvant chemoradiation, b) after neoadjuvant chemoradiation. The patient had pathologic complete response.