

Review Article

Running Title: Adenoid Cystic Carcinoma of Breast: a Review of Molecular Markers

Received: May 26, 2020; Accepted: March 04, 2021

Adenoid Cystic Carcinoma of Breast: A Review of Molecular Markers to Elucidate its Cancer Biology

Allan L. Hilario [♦], MD, MHA, MSc, John Robert C. Medina ^{**}, MD, MHS, Catherine Lynn T. Silao ^{***,****}, MD, PhD

**Department of Biochemistry and Molecular Biology, College of Medicine, University of the Philippines Manila, Manila City, Philippines*

***Department of Epidemiology and Biostatistics, College of Public Health, University of the Philippines Manila, Manila City, Philippines*

****Department of Pediatrics, College of Medicine, University of the Philippines Manila, Manila City, Philippines*

*****Institute of Human Genetics, National Institutes of Health, University of the Philippines Manila, Manila City, Philippines*

♦ Corresponding Author

Allan L Hilario, MD, MHA, MSc

Department of Biochemistry and Molecular Biology, College of Medicine,
University of the Philippines Manila, Manila City, Philippines

Tel/Fax: +63285264197

Email: alhilario@up.edu.ph

Abstract

Background: Adenoid cystic carcinoma (ACC) of breast is a rare type of breast cancer, which belongs to the triple-negative breast cancer associated with aggressive behavior and poor prognosis. Despite being classified as triple-negative breast cancer, ACC of breast is an indolent subtype with good biological behavior, less aggressive course, good response to treatment and clinical outcomes. It has generally a good overall survival with no propensity for metastasis. Thus, a correct diagnosis could be of great importance for providing proper and adequate treatment.

Method: Published literature was reviewed to determine differentially expressed genes that could be used as biomarkers for this disease and to elucidate the biology and carcinogenesis of ACC of breast according to this genetic profile.

Results: Several genes were differentially expressed and were found to belong to a wide range of biological processes. The most prevalent genetic alteration is a gene translocation that produces the *MYB-NF1B* fusion gene and the overexpression of MYB, which initiates tumorigenesis. This crucial genetic aberration is the hallmark of adenoid cystic carcinoma. The rest of the genes are involved in cell proliferation, apoptosis, stable epithelial phenotype, tumor suppression, and keeping an intact basement membrane, evasion of epithelial-mesenchymal transition, and prevention of metastasis.

Conclusion: This gene expression is responsible for various biological processes that reflect the biology of ACC of breast with an indolent course and good clinical outcomes. This genetic profile impacts biomarker research and could be used to refine patient diagnosis and selection for appropriate and less aggressive treatment options.

Keywords: Adenoid cystic carcinoma, Breast, Biomarkers, Review

Introduction

Adenoid cystic carcinoma (ACC) is a non-heritable cancer with varied clinical courses and prognoses depending on the organ of origin. Its treatment depends on a myriad of factors with different responses to surgery, radiotherapy, and chemotherapy. The etiology remains unknown, but a common genetic alteration seems to initiate tumorigenesis. It is an uncommon cancer of exocrine glandular origin, which could be found in various parts of the body. It is found more commonly in the salivary glands accounting for about 10-25% of all salivary gland malignancies. This form of cancer makes ACC the second most prevalent malignancy of both major and minor salivary glands.¹ It could be detected in other parts of the body, such as head and neck, lacrimal glands, auditory tract, upper respiratory tract, trachea, lungs, breast, skin, gastrointestinal tract, prostate, and gynecological tract. Genetically, ACC is similar throughout the body with minor mosaicism. It has a histologic characteristic of tangled cylinders composed of a hyaline stroma with intertwined epithelial and myoepithelial cells. Hence, it is also known as “cylindroma” as coined by Billroth. Cylindroma later on gained infamy and was changed to its present term of ACC for the salivary gland by Ewing in 1919 and for breast by Geschickter in 1945. Currently, it has four histological architectural patterns, namely cribriform, tubular, trabecular, and solid for primary and metastatic ACC.²

Despite being a rare malignancy, molecular profiling of ACC has been the focus of intensive research over the recent years. Most ACC found in various sites of the body have similar genetic characteristics with unique molecular drivers from an indolent type to a more aggressive form. Elucidating ACC carcinogenesis has evolved with advances in genetic testing, in other words, genetic studies using immunohistochemistry

(IHC)³, fluorescence in-situ hybridization (FISH),^{3, 4} and microarray assay.⁵⁻⁷ Tumorigenesis of ACC starts with the activation of the proto-oncogene, *MYB*, and the loss of function of a transcription factor, *NFIB*, due to chromosomal translocation involving chromosomes 6 and 9. This translocation results in gene fusion characterized as t(6:9) (q22-23;p23-24) and a deletion of the chromosomal band 6q at chromosome 6 activating other proto-oncogenes, such as *c-ros*, *c-syn*, and *c-myb*. These genetic alterations are common to all the ACC in the body and lead to the evasion of apoptosis, dysregulation of cell cycle control, and uncontrolled cell growth.⁸

Gene translocation, as a driver of carcinogenesis, appears to be widespread in several cancers not only in ACC. The activation of *MYB-NFIB* and *MYBL1-NFIB* fusion oncogenes initiates the role of MYB transcription factors in the sequence of events, which leads to ACC carcinogenesis. ACC of the salivary gland (ACCs) is one of the numerous ACC types, which appears to be initiated this way. ACC is the most common malignancy of minor salivary glands⁹ and is the second prevalent malignancy of the parotid and major salivary glands.^{10, 11} ACC of head and neck, including salivary glands, is considered as one of the most destructive cancers leading to significant facial disfigurement and a biologically erratic malignant course. Clinically, it is characterized as a slow growing type of cancer, yet with disparate tumor boundary and poor prognosis, which is aggressive and is more likely to recur in the primary site and metastasize. This is commonly seen in ACC of salivary gland origin.¹² Unlike its anatomical cousin, ACC of breast (ACCb) with genetic similarity to ACCs, has the opposite clinical and biological behavior.¹³

ACCb accounts for less than 1% of all breast cancer types in the world. ACC of breast belongs to the triple-negative breast cancer (TNBC) which does not

express the estrogen receptor (ER), progesterone receptor (PR), and human epidermal growth factor receptor 2 (HER2).^{14, 15} However, ACCb is a very distinct subtype of TNBC. TNBC is quite similar to ACCs in terms of prognosis, aggressiveness, response to treatment, clinical outcomes, and survival. Among the histologic types of TNBC, ACCb has a favorable course with a good prognosis and an overall survival rate ranging from 85-100%.¹⁶ Even with few cases of recurrence to the primary site and metastasis to some organs, the general clinical outlook following the treatment remains very good.¹⁷ Hence, it is imperative to identify specific and distinct molecular signatures of this histologic type of TNBC to improve diagnosis, properly select patients, provide appropriate targeted therapeutic strategies, and prevent these patients with ACCb from undergoing destructive surgeries and aggressive adjuvant therapy as advised for those with TNBC in general. This literature review aimed to determine the molecular markers of ACC of breast and elucidate its cancer biology and carcinogenesis based on the interplay of these differentially expressed genes published in literature.

Materials and Methods

A literature search was conducted using the mesh words “adenoid cystic carcinoma”, and “breast”, and “biomarkers” in PubMed for the articles published from 1990 to 2019. The search was done in 18 February 2020. Each article was evaluated for inclusion in this narrative review. The articles were included according to the following criteria: 1) studies that reported ACCb with biomarkers or molecular testing applying various methods, such as IHC, FISH, and microarray-based assays; 2) studies derived from molecular data sets of human ACCb mined from publicly available repositories; 3) review articles, case reports, case series, and studies about ACCb with molecular profiles employing

various techniques, such as IHC, FISH, and PCR-based assays. The exclusion criteria included: 1) studies on ACC of other sites; 2) studies not written in English; 3) studies done using animal models and cell lines. The guidelines recommended by Preferred Reporting Item for Systematic Reviews and Meta-Analyses (PRISMA) were followed in this review.¹⁸

Results

After performing a PubMed search using the mesh words “adenoid cystic carcinoma”, “breast”, and “biomarkers”, 217 articles were recognized. After evaluating each of these articles based on the inclusion and exclusion criteria, 71 articles were chosen. Each article was reviewed according to the purpose of this study. After the initial review, 49 articles were chosen and downloaded. Each full-text article was reviewed and checked if molecular profile was reported. Finally, eight articles were employed in this work (Figure 1). All the differentially expressed genes were tabulated (Table 1). Several genes were identified, which belonged to a wide range of biological processes.

Discussion

Summary of evidence and limitation

The generated gene set from the included studies in this systematic review showed a robust genetic profile which could be utilized for the basis of the elucidation of its cancer biology as discussed in this review. The findings of this review were based on the eight studies included, in which adenoid cystic breast disease was not expected to be a common triple-negative breast cancer type.

General considerations in clinical use of biomarker research for breast cancer

In general, the mainstay of breast cancer management is surgery either by breast-conservation surgery or simple to modified radical mastectomy with breast reconstruction,²⁷ followed by adjuvant chemotherapy,²⁸ adjuvant radiation

therapy,²⁹ and various targeted therapies.³⁰ Targeted therapies include hormonal therapy for ER+ and PR+ breast cancer types and immunotherapy with trastuzumab for HER2+ breast cancer types.³¹ The standard biomarkers used include ER, PR, HER2, and Ki67, which are tested by IHC and FISH.³² The use of microarray-based biomarkers has not indicated any significant clinical uses or evidence-based guidelines, as recommended by various organizations, like the American Society of Clinical Oncology (ASCO),³³ National Comprehensive Cancer Network (NCCN),³⁴ and the St. Gallen Group (SGG).^{35, 36} Breast cancer susceptibility genes, *BRCA 1* and 2, are also used in the evaluation of the hereditary form of breast cancer.³⁷ These few biomarkers are currently the ones being utilized in the prognostication and treatment planning and targeted therapeutics despite significant strides in breast cancer biomarker research employing IHC, FISH, and micro-array assay techniques for molecular profiling.^{38, 39}

The clinical use of biomarkers for breast cancer is quite limited. However, the number of breast cancers-associated tumor biomarkers and its various types and subtypes has exploded due to the robust research on breast cancer biomarkers. Breast cancer biomarkers comprise a wide range of biomolecules from nucleic acids to proteins and metabolites. The biomarkers are generally used to provide specific molecular categorization of breast cancers in types and subtypes with distinct prognostic features and treatment response evaluation and targeted therapeutics. Nonetheless, proteomic biomarkers are commonly studied and used for targeted therapies and clinical diagnostic assays owing to their utility in diagnosis and therapy via various standard existing molecular platforms. This also enables the characterization of breast cancer into molecular types and subtypes associated with particular clinical outcomes, making

the use of these biomarkers highly important clinically for biological classification, molecular typing and subtyping, prognostication, and targeted therapeutics.⁴⁰

An important breast cancer type, which has been extensively studied regarding to the elucidation of biomarkers and molecular profiling, is the triple-negative breast cancer (TNBC). Advances in molecular profiling has led to the molecular subtyping of TNBC to molecularly distinct subtypes with different clinical outcomes and prognosis. TNBC is presently subtyped into the following: 1) basal-like, 2) immunomodulatory, 3) luminal androgen receptor, 4) mesenchymal, and 5) mesenchymal stem-like. These subtypes have different clinical and molecular profiles associated with different prognosis and response to the available treatments. All these subtypes are characterized by aggressive behavior, poor prognosis, invariable treatment response, and limited treatment options in addition to high regional and distant metastasis, recurrence, and mortality, except for one, the ACCb, which is more comparable to the basal-like molecular sub-type based on genomic and transcriptome analyses.^{41, 42} Thus, the use of biomarkers to clinically identify ACCb patients among TNBC patients may benefit from a more conservative treatment option despite being classified as TNBC, which may be approached by most surgeons and oncologists aggressively in their treatment planning.

Adenoid cystic carcinoma of breast (ACCb) and molecular subtyping of TNBC

ACC of breast belongs to a very heterogenous breast cancer type, the triple-negative breast cancer, and is associated with diverse molecular signals and various molecular subtypes. Several studies on genomic and molecular profiling have reported various subtyping of TNBC.⁴¹⁻⁴⁵ These several subtyping of TNBC have proven that TNBC is a far highly

heterogenous both in its genotype and phenotype. Molecular heterogeneity has resulted in further TNBC subtypes with different biological characteristics and clinical outcomes. Despite the fact that TNBC consists of several molecular subtypes, breast cancer phenotype correlates well with genotype, which is further defined and clarified in ACCb. Specific genotype-phenotype correlations are based on a single chromosomal aberration involving the reciprocal translocation between the long arm of chromosome 6 in *MYB* and the short arm of chromosome 9 within *nuclear factor I/B (NFIB)*. This chromosomal translocation is responsible for the formation of the *MYB-NFIB* fusion gene that results in the overexpression of *MYB*, a transcription factor, and carcinogenesis of ACC. This chromosomal aberration is common to all ACC found in different body parts.⁴⁶

Breast cancer diagnosis has been based broadly on standard histopathologic techniques with the aid of certain clinically accepted biomarkers which are most commonly detected using IHC and FISH on formalin-fixed and paraffin-embedded tumor tissues. However, the diagnostic use of molecular typing based on microarray assays of breast cancer in general and TNBC in particular have not reached significant clinical use by the medical community because of the presence of several classification models for molecular typing and the absence of concurrence among these different molecular models. The limited use of molecular typing remains in the purview of scientific research and has not crossed over to clinical application despite clear evidence indicating that molecular typing of TNBC and special types of breast cancers shows distinct molecular signatures that could be conducive to disease prognostication and treatment planning employing standard treatment options and targeted therapeutics. Much has to be done to make high throughput technologies in molecular

subtyping to gain wide acceptance in clinical use. One reason behind such resistance may be the increasing complexity and variability of molecular subtypes reported in the literature with no definitive application for clinical use. Several clinicians question the use of molecular taxonomy instead of the standard histopathologic labeling of various breast cancer types and subtypes despite evidence implying that TNBC subtypes have clearly unique molecular signatures with significant clinical implications.^{47, 48}

Biomarkers of breast adenoid cystic carcinoma

ACCb most likely corresponds to the basal-like subtype of TNBC which is distinctly different from basal-like subtypes of breast cancer. It belongs to the largest breast cancer histopathologic type, which is the invasive ductal carcinoma or invasive carcinoma of no special type based on recent World Health Organization disease classification.⁴⁹ ACCb has a morphological and histological feature and distinct genetic signature associated with negative regulation of genes responsible for cell migration, proliferation, and immune response. ACCb is a unique special type of breast cancer with good prognosis classified within a very aggressive breast cancer type, which is TNBC.⁵⁰ Several reports have confirmed the same findings including other indolent special types of breast cancers.⁵¹

The biomarkers of ACCb in this review showed a similar expression of biomarkers characterizing the basal-like subtype of TNBC and special type of breast cancer. This gene expression profile includes the negative expression of ER, PR, and HER2 and the positive expression of *MYB*,^{19, 24} *E-cadherin*,²² *P-cadherin*,²² *keratin 5*, *keratin 7*, *keratin 17*,^{21-22, 25} *EGFR*,^{21, 22} *fibroblast growth factor receptor (FGFR)*,²⁶ *V-Set Domain Containing T Cell Activation Inhibitor 1 (VTCN1)*,²⁶ *c-KIT*,^{21, 24}, *Ki-67*,²³ *SMA*,^{20,}

²⁴ CRYAB, ²⁵ ID4, ²⁵ and loss of function of p63.^{21, 22} These differentially expressed genes are responsible for the biology of ACCb from the initiation of tumor formation, carcinogenesis, and clinical features that favors good prognosis with less potential for metastasis and good response for chemotherapy and indolent clinical course.

Tumorigenesis and disease progression of ACCb

The underpinning driver of tumorigenesis of ACC is the *MYB-NF1B* gene fusion not only in breast, but also in all ACC of different parts of the body. The mechanism is similar in different ACCs of the body. The overexpression of MYB, a transcription factor, causes the basal and myoepithelial cell of the mammary glandular unit to undergo uncontrolled cell proliferation and evasion of apoptosis.⁵² The resulting clonal progression of these epithelial cells lining the ductal and terminal acini of the mammary glands establishes the tumor. The acquired multiple chromosomal mutation results in malignant degeneration for ACCb. This carcinogenesis mimics the arrest of the epithelial developmental stage where the luminal progenitor and myoepithelial progenitor cells of the mammary glandular epithelium fail to normally differentiate and develop to basal cell and myoepithelial cell, respectively, underlining the ductal and lobular acini of the mammary gland unit due to *BRAC 1* mutation and dysfunctional *BRAC 1* pathway. BRCA 1-deficient cells and the interplay with dysregulated *BRAC 1* pathway result in the mammary epithelial developmental arrest leading to a basal-like subtype of TNBC and also reminiscence of the evolution of ACCb as shown in figure 2.²⁵

Although ACCb is not biologically aggressive, this particular type of breast cancer and a subtype of TNBC have low risk of nodal and systemic metastasis. However, there are several case reports of ACCb with documented metastasis to the

brain, lungs, kidneys,⁵³ the axillary lymph nodes,⁵⁴ and the bone⁵⁵ even though ACCb rarely metastasizes regionally and systemically. In addition, the cancer stem cell hypothesis and the subclonal evolution of the cancer cells may result in ACCb pathogenesis, which can push it to undergo transformation to high-grade TNBC explaining the few case reports of metastasis associated with ACCb. The same *MYB-NF1B* fusion gene and a clonal *NOTCH1* mutation play roles in the dysregulation of NOTCH1 signaling pathway and contribute to the ACCb pathogenesis and aggressiveness.⁵⁶ Although these are just few case reports of metastases of ACCb, the general outlook of ACCb is still less aggressive with less predisposition for lymphatic and hematogenous spread.

Biology of ACCb

The indolent biological behavior of ACCb may be attributed to its genetic profile. Even though such correlation may not be well-understood and well-demonstrated using specific cell line studies, the genetic characteristics of ACCb play a significant role in its biology and carcinogenesis. Genetically, ACCb has a stable genome with low genetic instability and single copy number aberration.⁴⁶ It could be attributed to its low mutation rate when compared with its salivary counterpart with a high mutation rate, opposite biological behavior, and poor prognosis. The absence of a *p53* gene mutation in ACCb may also be responsible for such biological behavior. In contrast to most TNBC, where ACCb belongs as a breast cancer type, mutations in the *p53* gene are widespread in TNBC, which could explain the aggressive behavior and generally poorer prognosis of TNBC despite the loss of function of *p63* in ACCb as reported in this study. The *p63* gene clearly plays a minor role in apoptosis and ACCb cell proliferation as shown in Figure 3, which explains the good prognosis and clinical outcomes of ACCb when compared with TNBC.^{21, 22, 57}

The overexpression of significant cytokeratin, such as Keratin 5, 7, and 17, E-cadherin, and P-cadherin, promotes the epithelial characteristics of ACCb.^{20-22, 25} These proteins are responsible for cell structural integrity and tight junctions between epithelial cell lining of the ductal and lobular acini of the mammary glandular unit. Despite the overexpression of SMA^{20, 24} and FGFR²⁶ proteins, which clearly provides mesenchymal features, the balance of epithelial and mesenchymal characteristics of ACCb ensures that epithelial-mesenchymal transition (EMT) does not occur. The initiation of EMT is a strong driver for metastasis where mammary epithelial cells lose their immotile features and change to a mobile feature of mesenchymal cells, like fibroblasts. Furthermore, ACCb has been shown to mutate the *ZEB1*, *twist*, and *snail* genes, which are strong drivers of EMT as shown in Figure 4. The loss of functions of these EMT drivers further prevents ACCb from undergoing metastasis through EMT.⁵⁸

The overexpression of various keratins ensures cytoskeletal integrity of the myoepithelial cells, the structural integrity of the basement membrane and evasion of EMT results in a highly stable tumor cell population despite the influence of SMA^{20, 24} and FGFR²⁶ for a more mesenchymal feature. The terminal lobular acini of the mammary glandular unit is lined by epithelial cells encircled by myoepithelial cells with the ability to contract. These cellular architecture and units sit on the basement membrane. This site is believed to be the origin of most breast cancers. The characteristic gene expression of ACCb, which produces these various protein products, creates a tumor microenvironment where the transformed epithelial and myoepithelial cells to cancer cells are allowed to remain in a stable tumor population. The sustained epithelial features prevent EMT while the intact basement membrane restricts the tumor growth well contained in the terminal

lobular acini of the mammary glandular unit. These mechanisms prevent metastasis whereas the balance of the counteracting processes of cell proliferation and tumor suppression and apoptosis may contribute to its indolent behavior.⁵⁹

Clinical implications of biomarkers in ACCb

The establishment of a distinct genetic profile or biomarkers for ACCb allows a definitive diagnosis of ACCb beyond a histopathologic diagnosis, which could be utilized to correctly identify patients with ACCb despite being included in triple-negative breast cancer. This is important since ACCb and TNBC have different prognosis, clinical outcomes, and responses to conventional breast cancer treatment. The clinical practice guidelines in the diagnosis and treatment of breast cancer are conventionally based on different clinical and histopathologic variables, like tumor size, histologic grade, stage and status of a few biomarkers, such as ER, PR, HER2, and Ki-67. Being classified as TNBC, the treatment of ACCb is already limited to surgery, chemotherapy, and radiotherapy. Hormonal and anti-HER2/neu therapies are no longer applicable. ACCb may be aggressively treated for being considered as TNBC in spite of having a good prognosis and good response to treatment. ACCb is a rare type of breast cancer and the available treatments are not subjected to randomized clinical trials unlike the most prevalent types of breast cancer, such as invasive ductal and lobular carcinomas. Currently, treatment options for ACCb, such as surgery, chemotherapy, and radiotherapy, are based on certain large population-based studies, case reports, and case series. Thus, identification of unique biomarkers for ACCb will certainly benefit patients in terms of treatment.³⁹

The identification of a unique genetic signature might also contribute to targeted therapy. Presently, there are no targeted therapies for ACCb in clinical use. Meanwhile, research on molecular

profiling of ACCb may lead to such targeted therapy. Some of the established molecular signals in this review are currently being investigated in pre-clinical and clinical studies. MYB has been targeted for anti-tumor therapy for leukemias and solid tumors, including breast cancer. However, anti-MYB therapies, which include DNA vaccine, inhibition using RNA interference and silencing, and small molecule compounds with potential inhibitory effect, have been focused on in various pre-clinical and clinical studies.⁶⁰ Another biomarker with targeted therapeutic potential is the c-KIT, a receptor tyrosine kinase (RTK). The use of receptor tyrosine kinase inhibitors has shown success in the treatment of gastrointestinal stromal tumor, acute myelogenous leukemia, and melanoma. The use of RTK inhibitors is considered complementary with other anti-cancer modalities and not as a single therapy; it has not been used specifically for ACCb. However, various RTK inhibitors are in different levels of clinical trials for TNBC and breast cancer in combination with other cancer treatment modalities.⁶¹ The use of anti-EGFR drugs such as the dual tyrosine kinase inhibitor, lapatinib, which targets both HER2/neu and EGFR has been approved for clinical use in ER+, HER2+, and EGFR+ breast cancer but not in ACCb.⁶² Another possible target is the FGFR with the use of inhibitors for the tyrosine kinase pathways. Several FGFR inhibitors are in various phases of clinical trials and in combination with other cancer modalities. These trials are for various cancers, including breast cancer.⁶³ Lastly, the use of Ki-67 protein as an index of cell proliferation has been established as a diagnostic and prognostic tool in breast cancer. Moreover, ER, PR, HER2, BRCA 1/2, and Ki-67 are taken into consideration in the guidelines by the St. Gallen Group in the evidence-based clinical practice guidelines for breast cancer including ACCb.⁶⁴

Conclusion

ACCb is an indolent and rare special type of breast cancer with a different clinical course and biology from triple-negative breast cancer. Being less aggressive, it has good clinical outcomes, good prognosis, and good response to treatment and rarely undergoes nodal and distant metastasis unlike its salivary counterpart. Nevertheless, like all ACCs in the body, it is triggered by translocation of chromosomes 6 and 9 leading to oncogenic activation of *MYB-NFIB* fusion gene and overexpression of MYB transcription factor. This cancer has distinct genetic signatures, which affect cell proliferation, tumor suppression, apoptosis, evasion of EMT, and ensure integrity of the basement membrane. As a complement to histopathologic diagnosis, this genetic profile can be used in order to obtain a more accurate diagnosis. These genetic signatures and their protein products influence the biology and carcinogenesis of ACCb with good clinical outcomes and good prognosis.

Acknowledgments

This work was part of the TNBC Philippine Research Project[®] approved by the University of the Philippines Manila Research Ethics Board (UPMREB Approval No. 2020-070-01) and was registered in the Research Grants and Administration Office (RGAO) of the UPM-NIH (Reg. no. 2019-1131).

Funding Statement

This work was part of the TNBC Philippine Research Project[®] which was funded by the NIH Faculty Research Grant of the National Institutes of Health, University of the Philippines Manila (UPM-NIH).

Conflicts of Interest

None declared.

References

1. Fordice J, Kershaw C, El-Naggar A, Goepfert H. Adenoid cystic carcinoma of the head and neck: predictors of morbidity and mortality. *Arch Otolaryngol.* 1999;125:149-52. doi:10.1001/archotol.125.2.149.
2. Marchiò C, Weigelt B, Reis-Filho JS. Adenoid cystic carcinomas of the breast and salivary glands (or 'The strange case of Dr Jekyll and Mr Hyde' of exocrine gland carcinomas). *J Clin Pathol.* 2010;63(3):220-8. doi:10.1136/jcp.2009.073908.
3. Terada T. Adenoid cystic carcinoma of the oral cavity: immunohistochemical study of four cases. *Int J Clin Exp Pathol.* 2013;6(2):932-9.
4. Sandros J, Stenman G, Mark J. Cytogenetic and molecular observations in human and experimental salivary gland tumors. *Cancer Genet Cytogenet.* 1990;44(22):153-67. doi:10.1016/0165-4608(90)90042-9.
5. Huang D, Chen W, He R, Yu F, Zhang Z, Ciu W. Different cDNA microarray patterns of gene expression reflecting changes during metastatic progression in adenoid cystic carcinoma. *World J Surg Oncol.* 2003;1(8):220-80. doi:10.1186/1477-7819-1-28.
6. Fusco N, Geyer FC, De Filippo MR, Martelotto LG, Ng CK, Piscuoglio S, et al. Genetic events in the progression of adenoid cystic carcinoma of the breast to high-grade triple-negative breast cancer. *Mod Pathol.* 2016;29(11):1292-305. doi:10.1038/modpathol.2016.134.
7. Seethala RR, Cieply KC, Barnes EL, Dacic S. Progressive genetic alterations of adenoid cystic carcinoma with high-grade transformation. *Arch Pathol Lab Med.* 2011;135:123-230. doi:10.1043/2010-0048-OAR.1.
8. Moskaluk C. Adenoid Cystic Carcinoma: Clinical and Molecular Features. *Head and Neck Pathol.* 2013;7:17-22. doi:10.1007/s12105-013-0426-3.
9. Poorten VLV, Balm AJ, Hilgers FJ. Prognostic factors for long term results of the treatment of patients with malignant submandibular gland tumors. *Cancer.* 1999; 85:2255-64. doi:10.1034/j.1399-0020.2000.290519-2.x.
10. Erovic BM, Sha MD, Bruch G, Johnston M, Kim J, O'Sullivan B, et al. Outcome analysis of 215 patients with parotid gland tumors: a retrospective cohort analysis. *J Otolaryngol.* 2015;44(43):1-8. doi:10.1186/s40463-015-0097-z.
11. Shigeish H, Ohla K, Okui G, Seino S, Hashikata M, Yamamoto K, et al. Clinicopathological analysis of salivary gland carcinomas and literature review. *Mol Clin Oncol.* 2015; 3:202-6.
12. Liu J, Shao C, Tan ML, Mu D, Ferris RL, Ha PK. Molecular biology of adenoid cystic carcinoma. *Head Neck.* 2012;4(11):1665-77. doi:10.1002/hed.21849.
13. Thomas DN, Asarian A, Xiao P. Adenoid cystic carcinoma of the breast. *J Surg Case Rep.* 2019;1:rfy333. doi:10.1093/jscr/rjy355.
14. Kocaay AF, Celik SU, Hesimov I, Eker T, Percinel S, Demirer S. Adenoid Cystic Carcinoma of the Breast: A Clinical Case Report. *Med Arch.* 2016;70(5):392-4. doi:10.5455/medarh.2016.70.392-394.
15. Agafonoff S, Sobolewski A, Braverman TS. Adenoid cystic carcinoma of the breast – discordant size on imaging and pathology: a case report and review of literature.

- Ann Med Surg.* 2019;43:1-4. doi:10.1016/j.amsu.2019.04.007.
16. Ghabach B, Anderson WF, Curtis RE, Huycke MM, Lavigne JA, Dores GM. Adenoid cystic carcinoma of the breast in the United States (1977 to 2006): a population-based cohort study. *Breast Can Res.* 2010;2:1-9. doi:10.1186/bcr2613.
 17. Yerushalmi R, Hayes MM, Gelmon KA. Breast carcinoma—rare types: review of the literature. *Ann Oncol.* 2009;20:1763-70. doi:10.1093/annonc/mdp245.
 18. Moher D, Liberati A, Tetzlaff J, Altman DG, The PRISMA Group. Preferred reporting item of systematic reviews and meta-analyses *Ann Intern Med.* 2009;15(4):264-9. doi:10.7326/0003-4819-151-4-200908180-00135.
 19. Arpino G, Clark GM, Mohsin S, Bardou VJ, Elledge RM. Adenoid cystic carcinoma of the breast molecular markers, treatment and clinical outcome. *Cancer.* 2002; 94:2119-27. doi:10.1002/cncr.10455.
 20. Mikai K, Schwartz MR, Divatia MK, Anton RC, Park YW, Ayala AG, et al. Adenoid cystic carcinoma of the breast: recent advances. *World J Clin Cases.* 2014;2(12):732-41. doi:10.12998/wjcc.v2.i12.732.
 21. Azoulay S, Lae M, Freneoax P, Merle S, Al Ghuzlan A, Chnecker C, et al. KIT is highly expressed in adenoid cystic carcinoma of the breast, a basal-like carcinoma associated with favorable outcome. *Mod Pathol.* 2005;18(12):1623-31. doi:10.1038/modpathol.3800483.
 22. Reyes C, Jordan M, Gomez-Fernandez C. salivary gland-like tumors of the breast express basal-like immunohistochemical markers. *Appl Immunohistochem Mol Morphol.* 2013;21(4):283-6. doi:10.1097/PAI.0b013e31826a277e .
 23. Junaianh E, Baslaim M, Shegairi S, Mashhoor R, Alsalmi J, Bajaber A. et al. Adenoid cystic carcinoma of the breast, high grade with basal phenotype, literature review. *Int J Surg Open.* 2018;10:43-56.
 24. Chin S, Kim K. Adenoid cystic carcinoma of the breast: report of two cases and immunohistochemical profile of C-kit and MYB overexpression. *Indian J Pathol Micr.* 2014;57(4):611-3.
 25. Perou CM. Molecular stratification of triple-negative breast cancers. *Oncologist.* 2010;15(Suppl 5):39-48. doi:10.1634/theoncologist.2010-S5-39.
 26. Burstein MD, Tsimelzon A, Poage GM, Covington KR, Contreras A, Fuqua SA, et al. Comprehensive genomic analysis identifies novel subtypes and targets of triple-negative breast cancer. *Clin Cancer Res.* 2015;21(7):1688-98. doi:10.1158/1078-0432.CCR-14-0432.
 27. McCrate F, Dicks E, Powell E, Chafe J, Roome R, Simmonds C, et al. Surgical treatment choices for breast cancer in Newfoundland and Labrador: a retrospective cohort study. *Can J Surg.* 2018;61(6):377-84. doi:10.1503/cjs.015217.
 28. Anampa J, Makower D, Sparano JA. Progress in adjuvant chemotherapy for breast cancer: an overview. *BMC Med.* 2015;13:195. doi:10.1186/s12916-015-0439-8.
 29. Krug D, Baumann R, Budach W, Dunst J, Feyer P, Fietkau R, et al. Current controversies in radiotherapy for breast cancer. *Radiat Oncol.* 2017;12(1):25. doi:10.1186/s13014-017-0766-3.
 30. Lehmann BD, Bauer JA, Chen X, Sanders ME, Chakravarthy AB, Shyr Y, et al. Identification of human triple-negative breast cancer subtypes and preclinical models for selection of targeted therapies. *J Clin*

- Invest.* 2011;121(7):2750-67. doi:10.1172/JCI45014.
31. Rodriguez D, Ramkairsingh M, Lin X, Kapoor A, Major P, Tang D. The Central Contributions of Breast Cancer Stem Cells in Developing Resistance to Endocrine Therapy in Estrogen Receptor (ER)-Positive Breast Cancer. *Cancers (Basel)*.;11(7):1028. doi:10.3390/cancers11071028.
 32. Ontario Health (Quality). Gene Expression Profiling Tests for Early-Stage Invasive Breast Cancer: A Health Technology Assessment. *Ont Health Technol Assess Ser.* 2020;20(10):1-234.
 33. Chiorean EG, Nandakumar G, Fadelu T, Temin S, Alarcon-Rozas AE, Bejarano S, et al. Treatment of Patients With Late-Stage Colorectal Cancer: ASCO Resource-Stratified Guideline. *JCO Glob Oncol.* 2020;6:414-38. doi:10.1200/jgo.19.00367.
 34. Tyagi NK, Dhesy-Thind S. Clinical practice guidelines in breast cancer. *Curr Oncol.* 2018;25(Suppl 1):S151-S160. doi:10.3747/co.25.3729.
 35. Goldhirsch A, Glick JH, Gelber RD, Thürlimann B, Senn HJ. Meeting highlights: international expert consensus on the primary therapy of early breast cancer 2005. *Ann Oncol.* 2005;16(10):1569-83. doi:10.1093/annonc/mdi326.
 36. Senkus E, Kyriakides S, Ohno S, et al. Primary breast cancer: ESMO Clinical Practice Guidelines for diagnosis, treatment and follow-up. *Ann Oncol.* 2015;26(Suppl 5):v8-v30. doi:10.1093/annonc/mdv298.
 37. Kemp Z, Turnbull A, Yost S, Seal S, Mahamdallie S, Poyastro-Pearson E, et al. Evaluation of Cancer-Based Criteria for Use in Mainstream BRCA1 and BRCA2 Genetic Testing in Patients With Breast Cancer. *JAMA Netw Open.* 2019;2(5):e194428. doi:10.1001/jamanetworkopen.2019.4428.
 38. Sharma P, Klemp JR, B. Kimler BF, Mahnken JP, Geier LJ, Khan QJ, et al. Germline BRCA mutation evaluation in a prospective triple-negative breast cancer registry: implications for hereditary breast and/or ovarian cancer syndrome testing. *Breast Can Res Treat.* 2014;145(3):707-14. doi:10.1007/s10549-014-2980-0.
 39. Kittaneh M, Montero AJ, Glück S. Molecular profiling for breast cancer: a comprehensive review. *Biomark Cancer.* 2013;5:61-70. doi:10.4137/BIC.S9455.
 40. Choo JR, Nielsen TO. Biomarkers for basal-like breast cancer. *Cancers.* 2010;2:1040-65. doi:10.3390/cancers2021040.
 41. Massé J, Truntzer C, Romain Boidot R, Khalifa E, Pérot G, Velasco V et al. Solid-type adenoid cystic carcinoma of the breast, a distinct molecular entity enriched in *NOTCH* and *CREBBP* mutations. *Mod Pathol.* 2020;33:1041-55. doi.org/10.1038/s41379-019-0425-3.
 42. Weigelt B, Geyer FC, Reis-Filho JS. Histologic types of breast cancer: How special are they? *Mol Oncol.* 2010;4:192-208. doi:10.1016/j.molonc.2010.04.004.
 43. Garrido-Castro AC, Lin NU, Polyak K. Insights into Molecular Classifications of Triple-Negative Breast Cancer: Improving Patient Selection for Treatment. *Cancer Discov.* 2019;9(2):176-98. doi:10.1158/2159-8290.CD-18-1177.
 44. Pareja F, Geyer FC, Marchiò C, Burke KA, Weigelt B, Reis-Filho JS. Triple-negative breast cancer: the importance of molecular and histologic subtyping, and recognition of low-grade variants,” *Breast Can.* , 2016;2:16036. doi:10.1038/npjbcancer.2016.36.

45. Santonja A, Sánchez-Muñoz A, Lluch A, Chica-Parrado M, Albanell J, Ignacio Chacón J, et al. Triple negative breast cancer subtypes and pathologic complete response rate to neoadjuvant chemotherapy. *Oncotarget*. 2018;9:26406-16. doi:10.18632/oncotarget.25413.
46. Mikse OR, Tchaicha JH, Esra A, Akbay EA, Chen L, Bronson RT, Hammerman PS et al. The impact of the *MYB-NFIB* fusion proto-oncogene *in vivo*. *Oncotarget*. 2016;7(22):31681-8. doi:10.18632/oncotarget.9426.
47. Perou CM, Sørlie T, Eisen MB, van de Rijn M, Jeffrey SS, Rees CA, et al. Molecular portraits of human breast tumours. *Nature*. 2000;406(6797):747-52. doi:10.1038/35021093.
48. Sørlie T, Perou CM, Tibshirani R, Aas T, Geisler S, Johnsen H, et al. Gene expression patterns of breast carcinomas distinguish tumor subclasses with clinical implications. *Proc Natl Acad Sci USA*. 2001;98(19):10869-74. doi:10.1073/pnas.191367098.
49. Hu Z, Fan C, Oh DS, Marron JS, He X, Qaqish BF, et al. The molecular portraits of breast tumors are conserved across microarray platforms. *BMC Genomic*. 2006;7(96). doi:10.1186/147-21647-96.
50. Weigelt B, Horlings HM, Kreike B, Hayes MM, Hauptmann M, Wessels LF et al. Refinement of breast cancer classification by molecular characterization of histological special types. *J Pathol*. 2008;216:141-50. doi:10.1002/path.2407.
51. Lambros MB, Tan DS, Jones RL, Vatcheva R, Savage K, Tamber N, et al. Genomic profile of a secretory breast cancer with an ETV6eNTRK3 duplication. *J Clin Pathol*. 2009;62:604e612. doi:10.1136/jcp.2008.059675.
52. Ho AS, Ochoa A, Jayakumaran G, Zehir A, Valero Mayor C, Tepe J, et al. Genetic hallmarks of recurrent/metastatic adenoid cystic carcinoma. *J Clin Invest*. 2019;129(10):4276-89. doi:10.1172/JCI128227.
53. Mhamdi HA, Kourie HR, Jungels C, Aftahos P, Belbaraka R, Piccart-Gehhart M. Adenoid cystic carcinoma of the breast-an aggressive presentation with pulmonary, kidney, brain metastases: a case report. *J Med Case Rep*. 2012;11:303. doi:10.1186/s13256-017-1459-0.
54. Burusapat C, Buarabporn N, Wongchansom K, Chanapai P, Parinyamit P, Supaporn A. Mammary adenoid cystic carcinoma presenting with ductal carcinoma in situ and axillary lymph node metastasis. *J Surg Case Rep*. 2020;2:1-4. doi:10.1093/jscr/rjz362.
55. Glover TE, Butel R, Bhuller CM, Senior EL. An unusual presentation of adenoid cystic carcinoma of the breast with metastatic disease to the clavicle. *BJR Case Rep*. 2017;2:20160119. doi.org/10.1259/bjrcr.20160119.
56. Sajed DP, Faquin WC, Carey C, Severson EA, H Afrogheh A, A Johnson C, et al. Diffuse Staining for Activated NOTCH1 Correlates With NOTCH1 Mutation Status and Is Associated With Worse Outcome in Adenoid Cystic Carcinoma. *Am J Surg Pathol*. 2017;41(11):1473-82. doi:10.1097/PAS.0000000000000945.
57. Martelotto LG, De Filippo MR, Ng CK, Natrajan R, Fuhrmann L, Cyrta J, et al. Genomic landscape of adenoid cystic carcinoma of the breast. *J Pathol*. 2015;237:179-89. doi:10.1002/path.4573.

58. Herschkowitz JI, Simin K, Weigman VJ, Mikaelian I, Usary J, Hu Z, et al. Identification of conserved gene expression features between murine mammary carcinoma models and human breast tumors. *Genome Biol.* 2007;8(5):R76. doi:10.1186/gb-2007-8-5-r76.
59. Thierauf J, Veit JA, Hess J. Epithelial-to-Mesenchymal Transition in the Pathogenesis and Therapy of Head and Neck Cancer. *Cancers (Basel)*. 2017;9(7):76. doi:10.3390/cancers9070076.
60. Liu X, Xu Y, Han L, Yi Y. Reassessing the Potential of Myb-targeted Anti-cancer Therapy. *J Can.* 2018;9:1259-66. doi:10.7150/jca.23992.
61. Babaei MA, Kamalidehghan B, Saleem M, Huri HZ, Ahmadipour F. Receptor tyrosine kinase (c-Kit) inhibitors: a potential therapeutic target in cancer cells. *Drug Des Dev Ther* . 2016;10:2443-59. doi:10.2147/DDDT.S89114.
62. Flynn JF, Wong C, Wu JM. Anti-EGFR Therapy: Mechanism and Advances in Clinical Efficacy in Breast Cancer. *J Oncol.* 2009;2009:526963. doi:10.1155/2009/526963.
63. Chae YK, Ranganath K, Hammerman PS, Vaklavas C, Mohindra N, Kalyan A, et al. Inhibition of the fibroblast growth factor receptor (FGFR) pathway: the current landscape and barriers to clinical application. *Oncotarget.* 2017;8(9):16052-74. doi:10.18632/oncotarget.14109.
64. Jung S, Han W, Lee JW, Ko E, Kim E, Yu J, et al. Ki-67 Expression Gives Additional Prognostic Information on St. Gallen 2007 and Adjuvant! Online Risk Categories in Early Breast Cancer. *Ann Surg Oncol.* 2009;16:1112-21. doi:10.1245/s10434-009-0334-7

Table 1. Differentially expressed genes in adenoid cystic carcinoma of breast from the literature

Gene	Gene Name	Biological Process	References
<i>MYB</i>	<i>MYB</i> proto-oncogene transcription factor	HTH DNA binding domain as transcription regulation	19, 24
<i>CK7</i>	Keratin 7	Cytoskeleton of epithelium	20
<i>CK 5/6</i>	Keratin 5	Cytoskeleton of epithelium	20, 21 22, 25
<i>CK17</i>	Keratin 17	Cytoskeleton of epithelium	20, 25
<i>c-KIT</i>	Receptor tyrosine kinase	Growth factor signaling	21
<i>EGFR</i>	Epidermal growth factor receptor	Cell proliferation	21, 25
<i>p63</i>	Tumor protein p63	Tumor suppression	21, 22
<i>P-cadherin</i>	Cadherin 3	Cell-cell adhesion	22
<i>E-cadherin</i>	Cadherin 1	Cell-cell adhesion	22
<i>Ki-67</i>	Marker of proliferation Ki-67	Cell proliferation	23
<i>SMA</i>	Actin alpha 2, smooth muscle	Cell motility	20, 24
<i>CRYAB</i>	Alpha crystalline B chain	Heat-shock protein, inhibits apoptosis	25
<i>ID4</i>	Transcription inhibitory protein	Cell proliferation	25
<i>VTCN1</i>	V-set domain containing T-cell activation inhibitor 1	Tumor progression	26
<i>FGFR</i>	Fibroblast growth factor receptor	Fibroblast proliferation and differentiation	26

Legend: HTH-helix-turn-helix; Source: <https://www.ncbi.nlm.nih.gov/gene>.

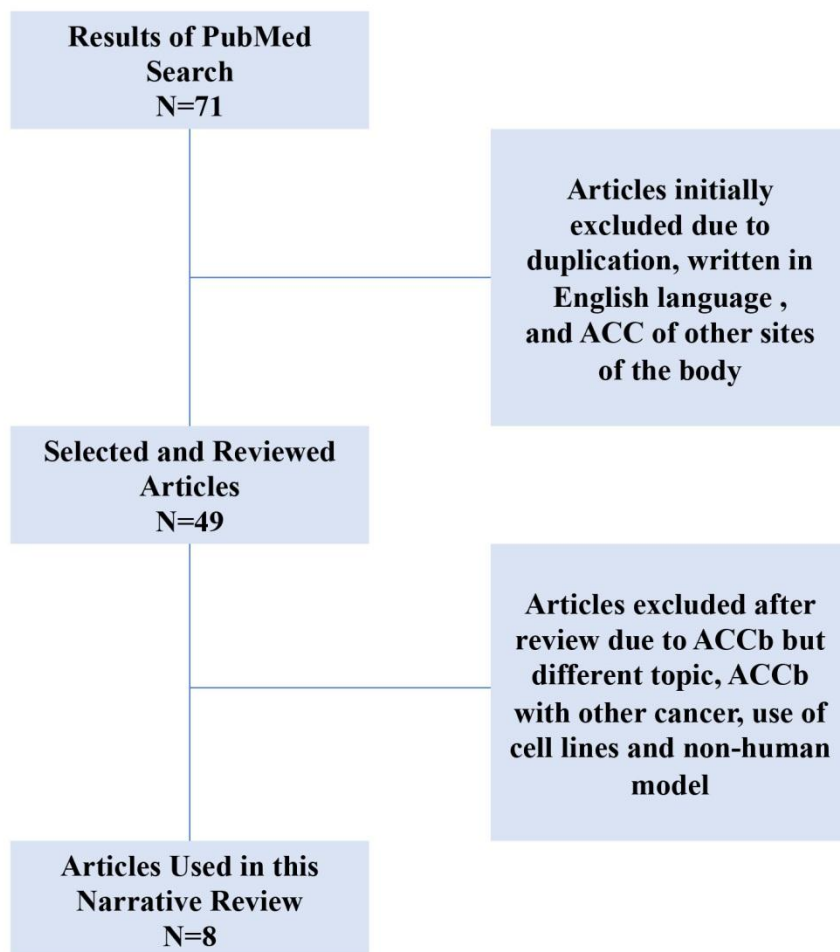


Figure 1. The flowchart used in the selection of the studies with genetic profile of adenoid cystic carcinoma of breast in the generation of gene set.

ACC: Adenoid cystic carcinoma; ACCb: Adenoid cystic carcinoma of the breast.

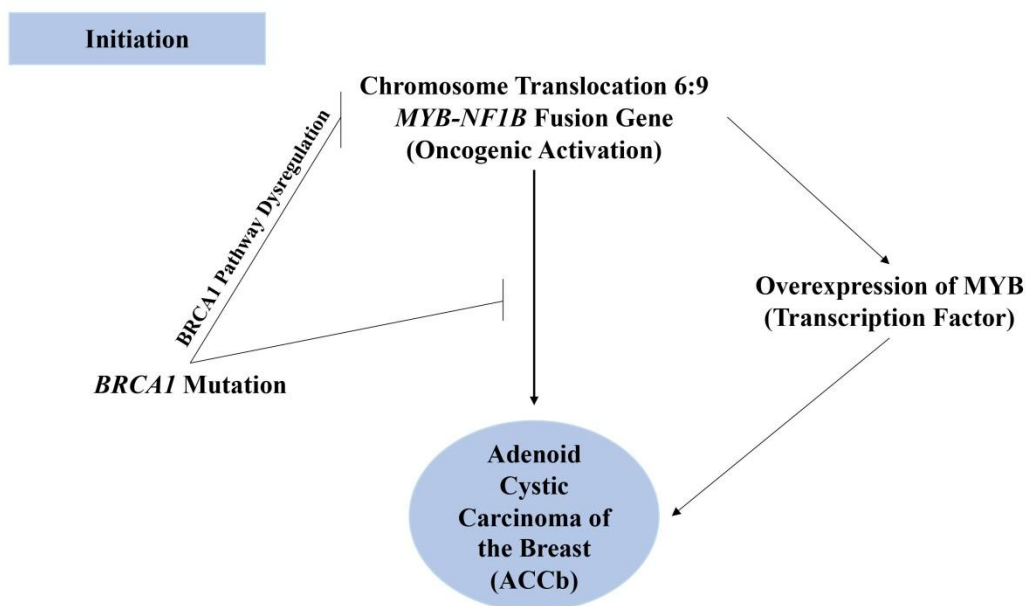


Figure 2 . This figure shows the genetic events that initiate tumorigenesis of adenoid cystic carcinoma of breast.

ACCb: Adenoid cystic carcinoma of the breast; *BRCA1*: Breast cancer gene 1; *MYB-NF1B*: Myeloblastosis-Nuclear Factor 1 B-type.

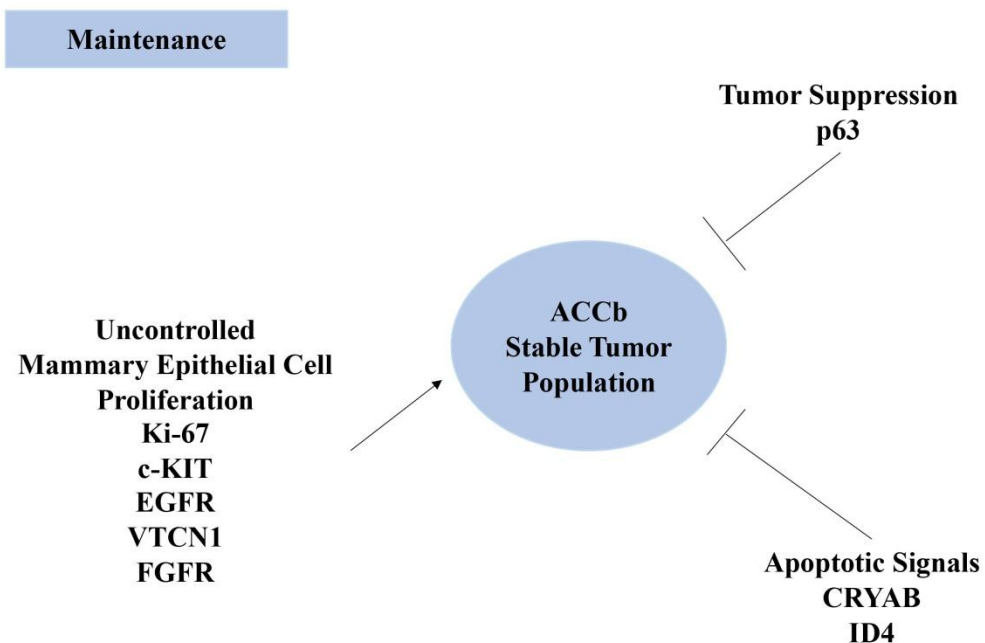


Figure 3. This figure shows the genetic interplay that sustains the tumor population of adenoid cystic carcinoma of breast.

ACCb: Adenoid cystic carcinoma of the breast; p63: Tumor suppressor gene 63; Ki-67: a marker of cell proliferation where Ki came from the place of discovery (Kiel, Germany) and clone number; c-KIT: cellular-Kinase tyrosine; EGFR: Epidermal growth factor receptor; VTCN1: V-set domain containing T-cell activation inhibitor 1; FGFR: Fibroblast growth factor receptor; CRYAB: Alpha crystalline B chain; ID4: Inhibition of DNA-Binding 4.

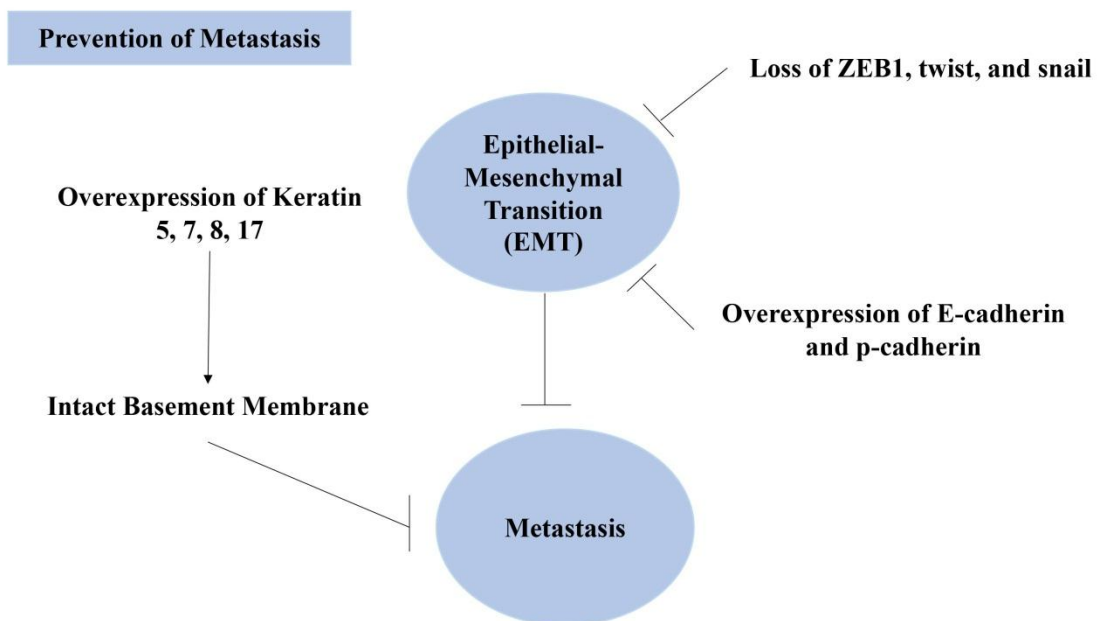


Figure 4. The mechanism of preventing metastasis in adenoid cystic carcinoma of breast is mainly based on the molecular regulation of epithelial-mesenchymal transition.

ZEB1: Zinc finger E-box-binding homeobox 1; EMT: Epithelial-mesenchymal transition