

## Case Report

**Running Title:** Mediastinal Choriocarcinoma

Received: May 15, 2020; Accepted: June 26, 2021

### Primary Mediastinal Choriocarcinoma in a Female Patient with Vaginal Bleeding: A Case Report

Nasrin Namdari<sup>\*♦</sup>, MD, Mohammad Hossein Anbardar<sup>\*\*</sup>, MD, Mehdi Dehghani<sup>\*\*\*</sup>, MD,

*\*Hematology and Medical Oncology Department, Shiraz University of Medical Science, Shiraz, Iran*

*\*\*Department of Pathology, Shiraz University of Medical Sciences, Shiraz, Iran*

*\*\*\*Hematology Research Center, Hematology and Medical Oncology Department, Shiraz University of Medical Science, Shiraz, Iran*

#### ♦Corresponding Author

Nasrin Namdari, MD

Hematology and Medical Oncology Department,  
Shiraz University of Medical Science, Shiraz, Iran

Tel: +989177111911

Email: [sonanamdari@yahoo.com](mailto:sonanamdari@yahoo.com)

#### Abstract

Primary mediastinal germ cell tumors accounts for about 3-15% of the mediastinal malignancies. Nonseminomatous tumors make a small percentage of germ cell tumors. Treatment of mediastinal choriocarcinoma includes initial systemic chemotherapy, followed by complete resection of all residual tumors. However, patients with non-seminomatous tumors have very poor prognosis.

**Keywords:** Choriocarcinoma, Nonseminomatous germ cell tumor, Mediastinal neoplasms

#### Introduction

Primary mediastinal Germ cell Tumors (PMGCTs) are rare malignancies constituting approximately 3-15% of the mediastinal tumors.<sup>1-3</sup>

Histologic and serologic properties of PMGCTs are similar to those of gonadal Germ cell Tumors (GCTs), yet with poorer prognosis.<sup>4,5</sup>

These tumors occur more frequently in males with a ratio of 9/1.<sup>6</sup>

A major part of mediastinal GCTs are teratomas followed by seminomas and

nonseminomas, accounting for a relatively smaller percentage of these malignancies.<sup>7</sup>

Primary mediastinal choriocarcinoma (PMC) is diagnosed with a mediastinal detectable lesion without the presence of the primary lesion in the gonads or metastatic disease in the retroperitoneal lymph nodes

Herein, we presented a case of PMC in a female patient who initially presented with vaginal bleeding, which progressed to superior vena cava syndrome.

## Case presentation

A 48-year-old female G4L4 initially presented with menorrhagia with high  $\beta$ -HCG titer (30000IU/L). She underwent total abdominal hysterectomy and bilateral salpingo-oophorectomy in another center, due to unusual vaginal bleeding. However, her pathology revealed that endometrial adenomyosis and gonads were normal.

About two months after the operation, the patient referred to our center due to facial edema and dyspnea on exertion.

Computed tomography (CT) of chest, abdomen, and pelvis was obtained, revealing a large superior mediastinal mass. The mass had led to pressure on SVC with multiple collateral vessels in anterior chest wall (Figure1). Abdomen and pelvis CT revealed portal vein thrombosis without evidence on retroperitoneal lymphadenopathy.

In her laboratory data, the patient had LDH: 950 U/L,  $\beta$ -HCG: 57700 IU/L, with normal AFP level.

Tru-cut Biopsy of mediastinal mass was done for the patient, revealing cohesive sheets of malignant epithelioid cells with focal central necrosis surrounded by fibrotic tissue (Figure 2). Tumoral cells showed marked cytologic atypia with hyperchromasia and several mitotic figures. There were certain giant multinucleated cells around cohesive syncytial cells (Figure 3). Immunohistochemical study indicated positive cytokeratin 7, PLAP, p63, SALL4, and CD5. According to the morphology and immunohistochemistry of the patient, we reached two different diagnoses of germ cell tumor and thymic carcinoma. Due to the presence of syncytial trophoblastic component and syncytiotrophoblast cells with central necrosis, germ cell tumor, particularly choriocarcinoma, was the most likely diagnosis. Mixed germ cell tumors could not be excluded in the tru-cut biopsy.

## Discussion

Our patient received one course of BEP chemotherapy protocol. However, the chemotherapy then changed to VIP, due to bleomycin pulmonary toxicity and probable need for mediastinal surgery. Following three cycles of VIP chemotherapy regimen, chest spiral CT scan revealed good response to chemotherapy with residual disease in mediastinum; consequently, thoracic surgery consultation was done for the patient, yet surgery was impossible due to the involvement of mediastinal great vessels and formation of several collaterals. Therefore, the patient underwent mediastinal radiation as a local therapy. Currently, about 9 months after the treatment, the patient is symptom-free and the disease is under control.

Extragonadal GCTs occur in anterior mediastinum, the retroperitoneum, pineal, and suprasellar regions. Less than 5% of germ cell tumors present as a mediastinal mass without the involvement of other sites.<sup>8,9</sup>

Extragonadal GCTs are categorized as seminomas, Nonseminomatous, mature teratoma, and immature teratoma. Choriocarcinoma is a subtype of nonseminomatous GCTs that behave aggressively and metastasize via hematogenous or lymphatic system to visceral organs.

Patients with PMC may present with symptoms of compression to adjacent structures, including dyspnea, chest pain, cough, superior vena cava syndrome, or symptoms of metastasis<sup>10</sup> although a small percentage of patients might be without any symptoms. Furthermore, elevated levels of HCG could be conducive to the diagnosis.

Only a few PMC cases have been reported among female patients<sup>7,8</sup>. The pathologic aspect of this tumor is characterized by the presence of cytotrophoblastic and syncytiotrophoblastic cells with extensive hemorrhage and/or necrosis.

The most frequently used immunohistochemical marker for the diagnosis of choriocarcinoma is Human chorionic gonadotropin (HCG). Other stains, such as keratin, PLAP, EMA, and AFP, might be positive in choriocarcinoma.<sup>7</sup>

Treatment of PMC consists of multimodality approach, including initial systemic chemotherapy, followed by complete resection of all residual tumors.<sup>11-12</sup>

There is no consensus on the best chemotherapy regimen for PMCs. Bleomycin-containing regimens, including BEP (bleomycin, etoposide, cisplatin), are known to be the standard treatment of patients with low-risk GCTs, like PMGCTs. Post-operative complications, namely pneumonia, acute respiratory distress, and prolonged ventilator requirement >48 hours, were more frequent with BEP compared to those with VIP (etoposide, ifosfamide, cisplatin) regimen.<sup>13</sup> Thus, several experts prefer VIP chemotherapy protocol for PMC. Five-year overall survival rate of patients with nonseminomatous tumors is lower than that in patients with seminoma, 45% versus 90%, respectively.<sup>2</sup>

### Conclusion

Primary mediastinal choriocarcinoma is a rare disease with only few cases being reported among female patients. As a result of very poor prognosis, the treatment initially consists of systemic chemotherapy and is followed by surgery.

### Acknowledgment

The authors wish to thank Mr. H. Argasi at the Research Consultation Center (RCC) of Shiraz University of Medical Sciences for his invaluable assistance in editing this manuscript.

### Informed Consent

We received oral informed consent from the patient.

### Conflict of Interest

None declared.

### References

1. Davis RD Jr, Oldham HN Jr, Sabiston DC Jr. Primary cysts and neoplasms of the mediastinum: recent changes in clinical presentation, methods of diagnosis, management, and results. *Ann Thorac Surg.* 1987;44(3):229-37. doi: 10.1016/s0003-4975(10)62059-0.
2. Tanaka Y, Okamura T, Nagai T, Kobayashi D, Kobayashi T, Akita H, et al. A study of patients with primary mediastinal germ cell tumors treated using multimodal therapy. *Adv Urol.* 2017;2017:1404610. doi: 10.1155/2017/1404610.
3. Mullen B, Richardson JD. Primary anterior mediastinal tumors in children and adults. *Ann Thorac Surg.* 1986;42(3):338-45. doi: 10.1016/s0003-4975(10)62751-8.
4. Mead GM, Stenning SP, Cook P, Fossa SD, Horwich A, Kaye SB, et al. International Germ Cell Consensus Classification: a prognostic factor-based staging system for metastatic germ cell cancers. International Germ Cell Cancer Collaborative Group. *J Clin Oncol.* 1997;15(2):594-603. doi: 10.1200/JCO.1997.15.2.594.
5. Toner GC, Motzer RJ. Poor prognosis germ cell tumors: current status and future directions. *Semin Oncol.* 1998;25(2):194-202.
6. Kalhor N, Moran CA. Primary germ cell tumors of the mediastinum: a review. *Mediastinum.* 2018;2:4.
7. Moran CA, Suster S. Primary germ cell tumors of the mediastinum: I. Analysis of 322 cases with special emphasis on teratomatous lesions and a proposal for histopathologic classification and clinical staging. *Cancer.* 1997;80(4):681-90.
8. Iyoda A, Hiroshima K, Yusa T, Toyozaki T, Fujisawa T, Ohwada H. The primary

- mediastinal growing teratoma syndrome. *Anticancer Res.* 2000;20(5C):3723-6.
9. Hainsworth JD, Greco FA. Extragonadal germ cell tumors and unrecognized germ cell tumors. *Semin Oncol.* 1992;19(2):119-27.
  10. Batman S, Morgan T, Brunetti M, Strandabø RAU, Micci F, Moffitt M, et al. Primary mediastinal choriocarcinoma in a female patient: Case report and review of the literature. *Gynecol Oncol Rep.* 2018;26:99-101. doi: 10.1016/j.gore.2018.10.013.
  11. Ganjoo KN, Rieger KM, Kesler KA, Sharma M, Heilman DK, Einhorn LH. Results of modern therapy for patients with mediastinal nonseminomatous germcell tumors. *Cancer.* 2000; 88(5):1051-6.
  12. Sakurai H, Asamura H, Suzuki K, Watanabe S, Tsuchiya R. Management of primary malignant germ cell tumor of the mediastinum. *Jpn J Clin Oncol.* 2004;34(7):386-92. doi: 10.1093/jjco/hyh062.
  13. Ranganath P, Kesler KA, Einhorn LH. Perioperative morbidity and mortality associated with bleomycin in primary mediastinal nonseminomatous germ cell tumor. *J Clin Oncol.* 2016;34(36):4445-6. doi: 10.1200/JCO.2016.69.8910.

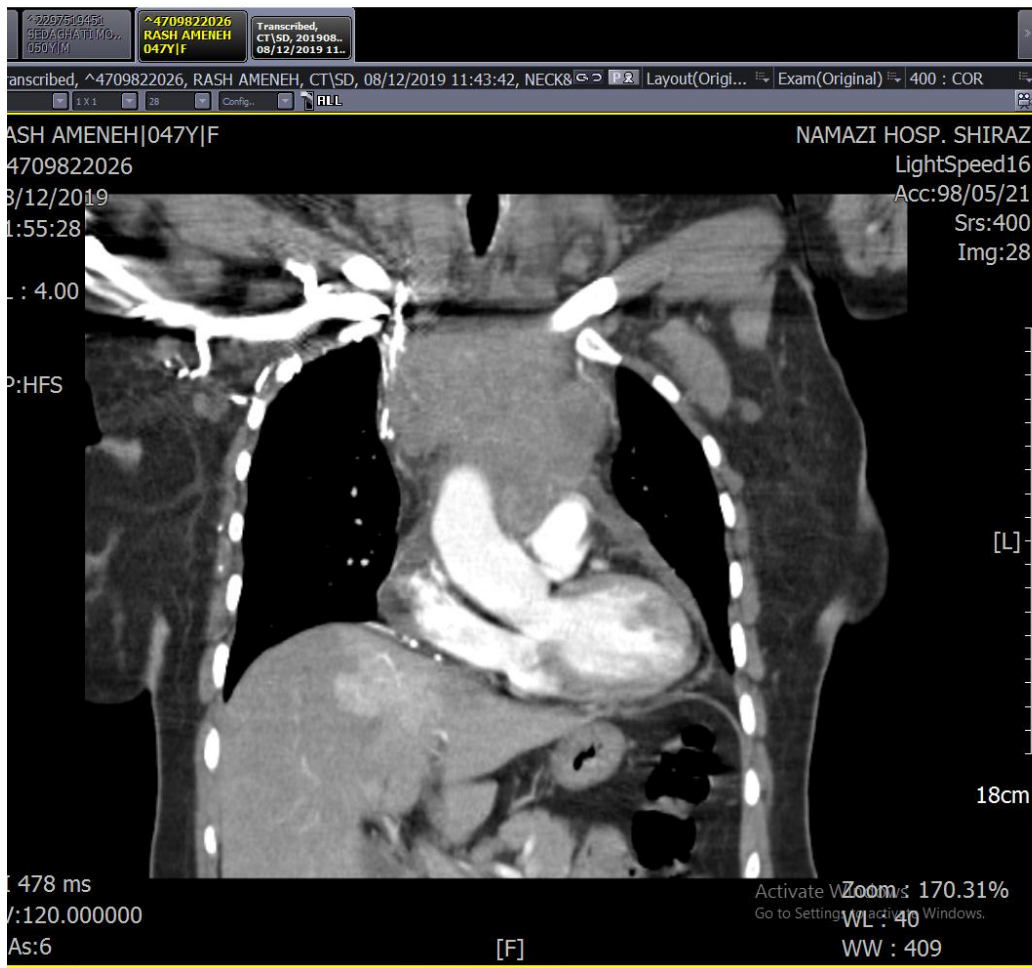


Figure 1. This figure shows the computed tomography of chest revealed large superior mediastinal mass with pressure on Superior Vena Cava.

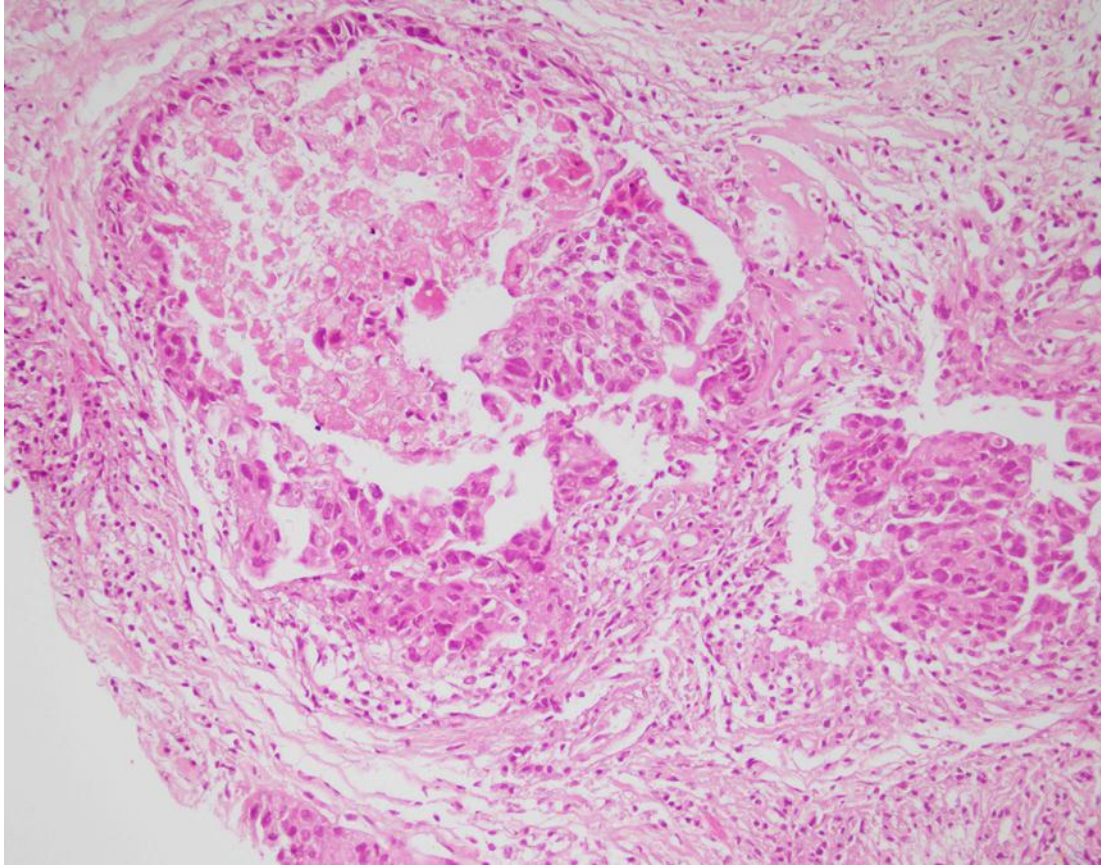


Figure 2. Microscopic section shows syncytial cohesive trophoblastic cells with central necrosis. (Hematoxyline and Eosin,  $\times 200$ )

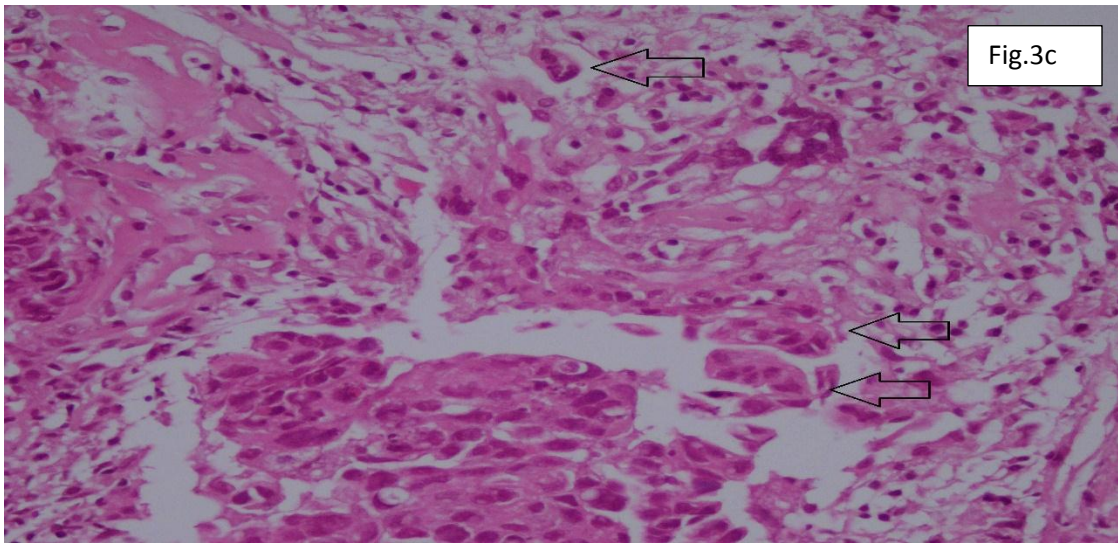
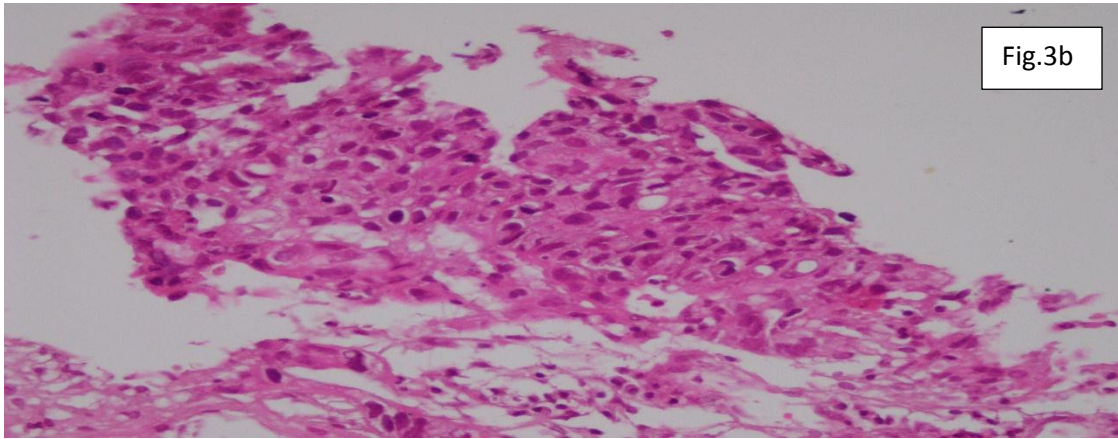
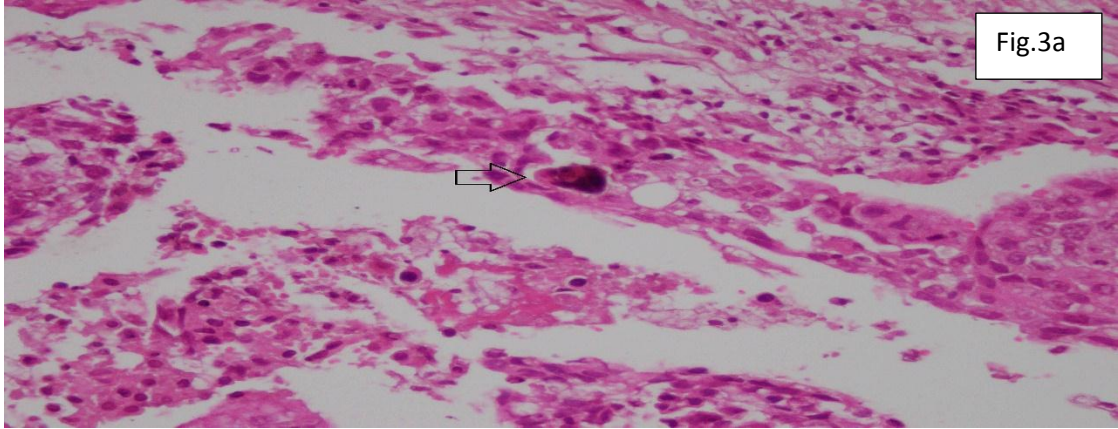


Figure 3. (a-c) Microscopic section shows trophoblastic cells with marked atypia and some syncytiotrophoblasts (arrow). (Hematoxyline and Eosin,  $\times 400$ )