

Case Report

Middle East Journal of Cancer 2013; 4(4): 185-188

Cervical Lymphadenopathy as the First Presentation of Sigmoid Colon Cancer

Bulent Aksel*, Lutfi Dogan**, Niyazi Karaman*, Salim Demirci**

*Department of General Surgery, Ankara Oncology Training and Education Hospital, Ankara, Turkey

**Department of Surgical Oncology, Ankara University, School of Medicine, Ankara, Turkey

Abstract

The most common metastatic sites for colorectal carcinomas include the liver, lungs, brain, bones and peritoneal surfaces. In this report, a case of sigmoid colon carcinoma presented with cervical lymphadenopathy was detected with the help of PET/CT. A 57 year-old male presented with a complaint of swelling on the left side of his neck. Ultrasonographic examination of the neck revealed three hypoechoic, peripherally vascularized lymph nodes with the largest diameter of 3cm. The thyroid gland was normal. Fine needle aspiration biopsy was performed and the pathology result was a metastatic carcinoma. He underwent a PET/CT scan to search for the primary carcinoma which showed increased standardized uptake value of 13.2 in the left colon and 10.8 in the left cervical region. Colonoscopy showed an ulcerated mass lesion with obstruction of the lumen in the sigmoid colon. The patient had an anterior resection of the sigmoid colon with simultaneous resection of cervical lymph nodes. There was no evidence of intra-abdominal dissemination during surgery. The lymph nodes removed from the neck were also reported as metastatic adenocarcinoma. The patient underwent six cycles of adjuvant FOL FOX chemotherapy regimen. The patient has remained disease free after nine months of follow-up. PET/CT was a quick, effective method for the detection of the primary tumor in the sigmoid colon. In addition to colonic resection and systemic therapy, palliative local control can also be achieved with the excision of metastatic lymph nodes in the neck.

Keywords: Cancer, Sigmoid colon, Metastasis, Cervical lymph node, PET/CT

Introduction

Systemic dissemination of colorectal carcinomas is not rare. At the time of diagnosis, synchronous-liver metastasis is present in about 15%-20% of patients.¹ The other frequent metastatic sites are the lungs, brain, bones and peritoneal surfaces.²

Lymphatic spread occurs by migration of tumor cells in the regional lymph node stations. Cervical lymph node metastasis of colon carcinomas without any other solid organ metastasis is very uncommon. In this article we describe a case of sigmoid colon

Corresponding Author:

Lutfi Dogan, MD
Oncology Hospital, Demetevler-
Ankara, Turkey
Tel: +90312 3196209
Fax: +90 312 345 49 79
Email: lutfidogan1@gmail.com



carcinoma that presented with cervical lymphadenopathy (LAP) detected with the help of fluorine-18-fluorodeoxyglucose positron emission tomography/computed tomography (PET/CT).

Case Report

A 57 year-old male patient presented with a complaint of swelling on the left side of his neck for about three months. There were no other complaints of dyspnea, dysphagia, hoarseness, loss of appetite or weight loss. There were no gastrointestinal complaints like abdominal pain, difficulty in defecation, nausea or vomiting. At physical examination, a firm and fixed LAP was palpated on the left lateral cervical region. There were three hypoechoic, peripherally vascularized lymph nodes with the largest diameter of 3cm described at ultrasonographic examination of the neck. The thyroid gland was normal at ultrasonography. Fine needle aspiration biopsy (FNAB) was performed and the pathology result was metastatic carcinoma. There were no additional pathological findings other than cervical LAPs visualized on neck and thorax computed tomographies. A PET/CT was performed to search for the primary carcinoma. Increased standardized uptake values (SUV) of 13.2 and 10.8 were observed in the left colon and left cervical region, respectively (Figure 1). At colonoscopy, there was an ulcerated mass lesion with obstruction of the lumen in the sigmoid colon.

Distant solid organ metastasis was not observed at abdominal CT; the biopsy result for the primary lesion was also adenocarcinoma. The patient underwent an anterior resection of the sigmoid colon with the simultaneous resection of the cervical lymph nodes. There was no evidence of intra-abdominal dissemination during surgery. The final pathology report revealed that the tumor had reached to the subserosa and tumor metastasis was present in all of the 27 dissected lymph nodes in the mesocolon. The lymph nodes removed from the neck were metastatic adenocarcinoma (Figure 2); thus the tumor was staged as T3N2M1b. He underwent six cycles of adjuvant FOLFOX chemotherapy. The patient was disease-

free at nine months of follow-up.

Discussion

The most likely primary sites for adenocarcinoma metastasis of the cervical lymph nodes are the thyroid gland, lungs, breast, and head and neck region. However, detection of a primary tumour is not possible in 3%-9% of patients.³ Although the histological and immunohistochemical features of the metastatic lesion is a guide during the investigation of a primary tumor, these features sometimes do not designate the primary.⁴ Additionally, a tru-cut biopsy or metastatic lymph node excision is usually required to obtain an adequate tissue sample for immunohistochemical studies. Taking into consideration all cancer types, the PET/CT sensitivity and specificity for diagnosis of lymph node metastases is reported between 92%-94% and 95%-100%, respectively.⁵ PET/CT is an effective technique for the detection of lymph node metastases from colon carcinoma.⁶

A study from M.D. Anderson Cancer Center reported the following predictive values for PET/CT in the detection of colon cancer: sensitivity (53%), specificity (93%), positive (65%) and negative (89%). The values for discrimination of tumors greater than one centimeter were 72% (sensitivity), 90% (specificity), 45% (positive) and 96% (negative).⁷ SUVs were not valuable for the definition of true and false positivity rates. In the current case PET/CT was a quick, effective method for the detection of a primary focus in the sigmoid colon.

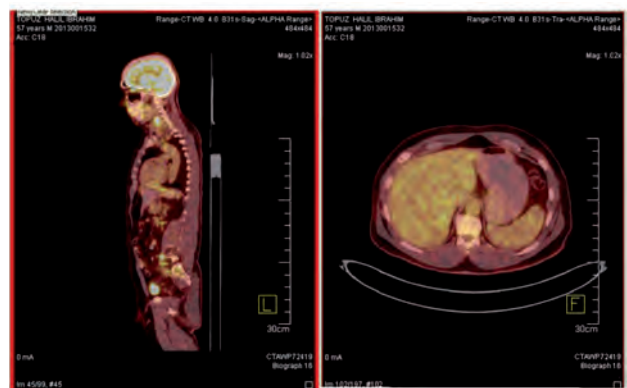


Figure 1. Hot spots obtained by PET/CT in the sigmoid colon and left cervical areas.

The SUVs of both primary and metastatic are as were quite high for our patient.

Regional lymph node metastasis is seen in 35%-40% of colon carcinomas.¹ The process of metastasis starts with the migration of tumor cells into the lymphatic channels. The tumor spread is expected to occur sequentially at the epicolic, paracolic, intermediate and mesenteric lymph node stations. Molecular studies have shown that skip micrometastases between regional lymph node stations can be seen in 18% of cases.⁸ After the metastatic involvement of para-aortic lymph nodes, sequential left supraclavicular (Virchow node) and left cervical lymph node metastasis can be seen as a result of invasion of the ductus thoracicus with tumor cells. Skip metastasis between lymph node stations can occur during the formation of this type of metastasis. As in our case, metastasis can present in the mid-jugular neck region. This type of metastasis in the absence of solid organ metastasis is not a typical pattern for the dissemination of colon cancer.

The treatment choice for metastatic colon cancer depends on the site of metastasis and dissemination pattern of the disease. In addition to systemic treatment, local surgical treatment can also be used in a case of metastatic disease limited to cervical lymph nodes. Excision of the lymph nodes may be required to provide palliative local control in the neck. In the literature, colorectal carcinoma cases that presented with cervical lymphadenopathy have been reported. Kim et al. reported that long-term survival can be obtained with nodule excision and FOLFOX chemotherapy in sigmoid colon cancer cases that have metastasis to the Virchow nodule.⁹ In their case, the disease stage was pT3N0M0. Hirose et al. reported that although the same regimen provided long-term survival in a similar patient, the presence of irresectable nodules might cause problems during treatment. In that case the lymph nodes regressed with chemotherapy, but progressed after completion of chemotherapy and resulted in painful swelling with drainage.¹⁰

Cipe et al. reported the use of PET/CT in preoperative staging of 64 colorectal carcinoma

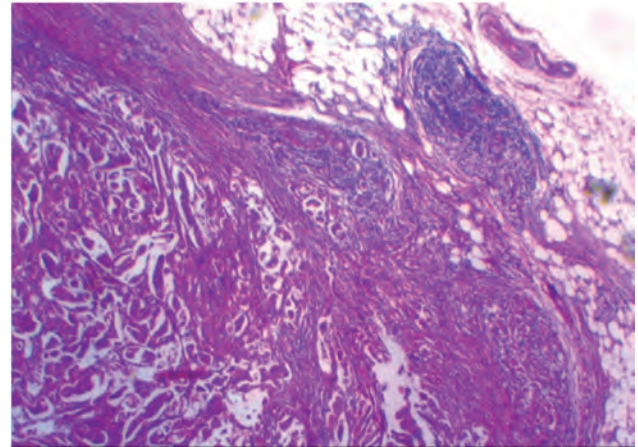


Figure 2. Adenocarcinoma metastasis in a cervical lymph node.

patients. The false positivity rate of this technique was 6.25%. A supraclavicular lymph node was detected in one patient evaluated with PET/CT and the lymph node was simultaneously resected. However treatment did not change in 96.8% of patients; thus it was not recommended for routine staging.¹¹ PET/CT was also not recommended in a review analysis of primary staging for colorectal carcinomas due to high false positive rates and cost.¹² However it is accepted as an effective method in recurrent and metastatic colorectal cancer cases.¹³

In conclusion, PET/CT can be used effectively for the detection of a primary focus in a patient who presents with cervical lymph node metastasis. In addition to colon resection and systemic therapy, palliative local control can be achieved with the excision of metastatic lymph nodes in the neck.

References

1. Pisani P, Bray F, Parkin DM. Estimates of the worldwide prevalence of cancer for 25 sites in the adult population. *Int J Cancer* 2002;97:72-81.
2. Hamilton SR, Aaltonen LA. World Health Organization classification of tumours. Pathology and genetics of tumours of the digestive system. Lyon: IAR Press, 2000.
3. Krejović-Trivić SB, Trivić AS, Banko AV, Milovanović AP, Ugrinović AB, Vukasinović M. Diagnostic algorithm in patients with cervical metastasis of malignant tumours unknown primary location. *Acta Chir Jugosl* 2009;56:17-21.
4. Matsumoto M, Nakajima T, Kato K, Kouno T, Sakamoto T, Matsuda T, et al. Small invasive colon cancer with systemic metastasis: A case report. *BMC*

- Gastroenterol* 2011;11:59.
5. Rades D, Kühnel G, Wildfang I, Börner AR, Schmoll HJ, Knapp W. Localised disease in cancer of unknown primary (CUP): The value of positron emission tomography (PET) for individual therapeutic management. *Ann Oncol* 2001;12:1605-9.
 6. Bohuslavizki KH, Klutmann S, Kröger S, Sonnemann U, Buchert R, Werner JA, et al. FDG PET detection of unknown primary tumors. *J Nucl Med* 2000;41:816-22.
 7. Weston BR, Iyer RB, Qiao W, Lee JH, Bresalier RS, Ross WA. Ability of integrated positron emission and computed tomography to detect significant colonic pathology: The experience of a tertiary cancer center. *Cancer* 2010;116:1454-61.
 8. Merrie AE, Phillips LV, Yun K, McCall JL. Skip metastases in colon cancer: Assessment by lymph node mapping using molecular detection. *Surgery* 2001;129:684-91.
 9. Min Kim H, Hasegawa J, Hirota M, Matsunami N, Mikata S, Shimizu J, et al. A case of sigmoid colon cancer with Virchow's lymph node metastasis successfully treated with chemotherapy. *Gan To Kagaku Ryoho* 2012;39:2249-51.
 10. Hirose H, Ikeda M, Miyoshi N, Kim HM, Okano M, Uemura M, et al. A long-term survival case of rectal cancer with Virchow's lymph node metastasis by multimodality therapy. *Gan To Kagaku Ryoho* 2010;37:2545-7.
 11. Cipe G, Ergul N, Hasbahceci M, Firat D, Bozkurt S, Memmi N, et al. Routine use of positron-emission tomography/computed tomography for staging of primary colorectal cancer: Does it affect clinical management? *World J Surg Oncol* 2013;11:49.
 12. Brush J, Boyd K, Chappell F, Crawford F, Dozier M, Fenwick E, et al. The value of FDG positron emission tomography/computerised tomography (PET/CT) in pre-operative staging of colorectal cancer: A systematic review and economic evaluation. *Health Technol Assess* 2011;15:1-192.
 13. Facey K, Bradbury I, Laking G, Payne E. Overview of the clinical effectiveness of positron emission tomography imaging in selected cancers. *Health Technol Assess* 2007;11:265-7.