

## Case Report

Middle East Journal of Cancer; October 2020; 11(4): 512-515

# Acute Renal Failure: A Rare Initial Presentation of Acute Lymphoblastic Leukemia

Mohammadreza Bordbar\*, Nader Shakibazad\*\*\*, Hadi Mottaghipisheh\*\*\*, Mahdi Shahriari\*\*\*, Soheila Zareifar\*, Omid Reza Zekavat\*

\*Hematology Research Center, Shiraz University of Medical Sciences, Shiraz, Iran

\*\*Department of Pediatric Hematology and Oncology, Bushehr University of Medical Sciences, Bushehr, Iran

\*\*\*Department of Pediatrics, Division of Pediatric Hematology and Oncology, Shiraz University of Medical Sciences, Shiraz, Iran

Please cite this article as: Bordbar M, Shakibazad N, Mottaghipisheh H, Shahriari M, Zareifar S, Zekavat OR. Acute renal failure: A rare initial presentation of acute lymphoblastic leukemia. Middle East J Cancer. 2020;11(4): 512-5. doi: 10.30476/mejc.2020.78666.0.

## Abstract

Acute lymphoblastic leukemia has several presentations associated with bone marrow and extramedullary involvement. The unusual presentation may be due to the infiltration of leukemic cells in any organ. An 11-year-old girl presented with fever and vomiting, since one day before admission after starfish biting during swimming. Her vital signs were: blood pressure 150/100 mmHg, pulse 98 beats per minute, respiration 18 breathes per minute, and temperature 37.2 °C (99 F). Laboratory work-up showed blood urea nitrogen 38 mg/dl and creatinine 2.8 mg/dl. In peripheral blood smear, few atypical cells, mild anemia (Hb: 9.2 g/dl), and mild thrombocytopenia (Platelet: 109,000/ $\mu$ L) were detected. Bone marrow aspiration and immunophenotyping were in favor of acute precursor B cell type lymphoblastic leukemia. The patient had a favorable response to treatment after initiating high-risk chemotherapy. Therefore, acute renal failure can be a rare initial presentation of acute lymphoblastic leukemia, and azotemia will improve with an early chemotherapy treatment.

**Keywords:** Renal failure, Acute lymphocytic leukemia, Precursor B-cell lymphoblastic leukemia, Azotemia

◆Corresponding Author:  
Nader Shakibazad, MD  
Department of Pediatric  
Hematology and Oncology,  
Bushehr University of Medical  
Sciences, Bushehr, Iran  
Tel/Fax: +98-936-2663809  
Email: nshakibazad@gmail.com

## Introduction

Acute lymphoblastic leukemia (ALL) is one of the most prevalent hematologic malignancies in pediatrics with a survival rate of around 85%.<sup>1</sup> The presentations of

ALL differ according to bone marrow infiltration or extramedullary involvement of blast cells.<sup>2, 3</sup> It can present with fever, bone pain, anorexia, bleeding, and pallor, which is indicative of bone marrow (BM)

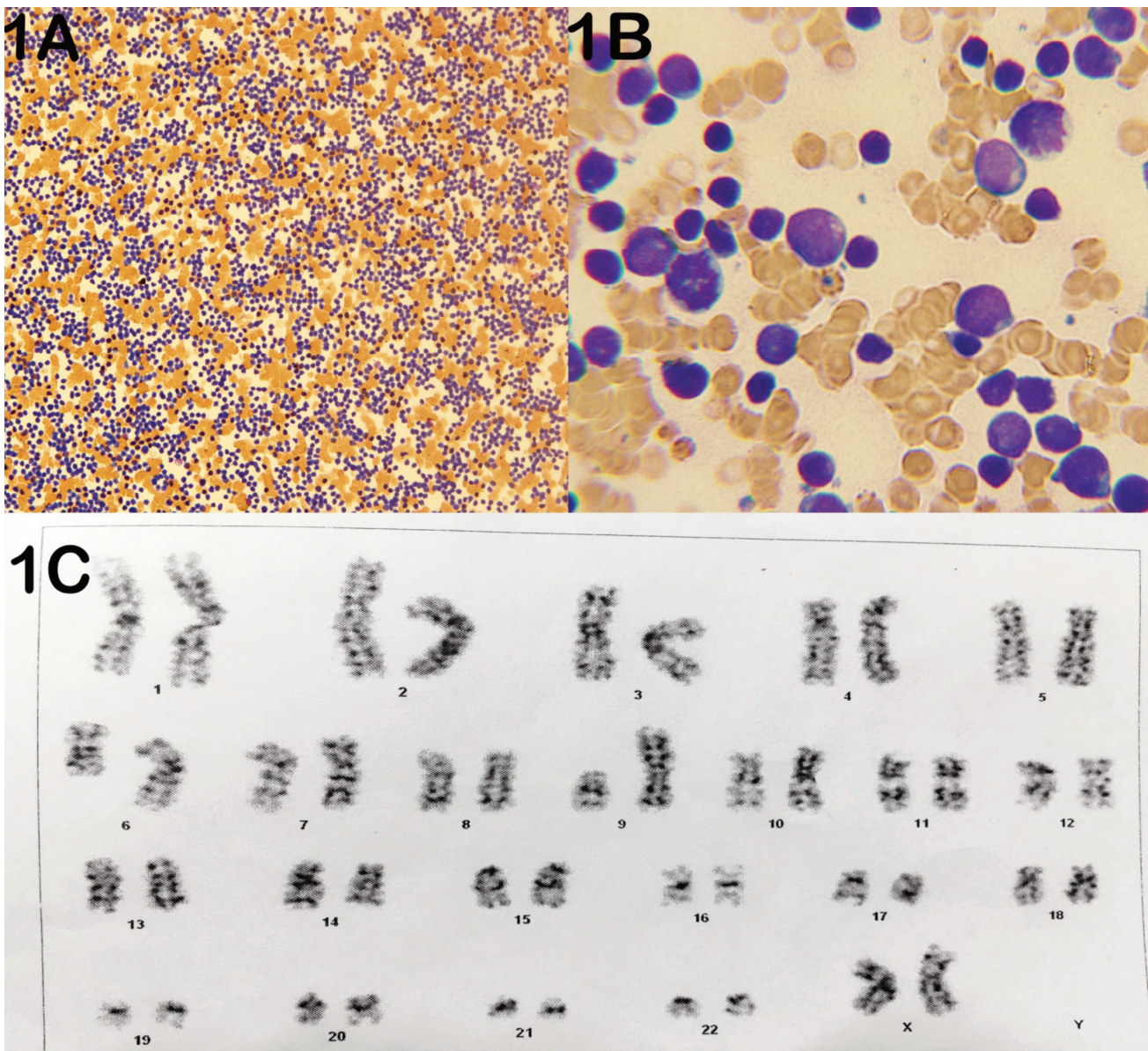
failure. It can further present with an extramedullary presentation like painless lymphadenopathy and asymptomatic hepatosplenomegaly.<sup>3,4</sup> The unusual presentation may be attributed to the infiltration of leukemic cells in any organ and a high index of suspicion is warranted. Therefore, the objective of this study was to present a case of ALL with a rare presentation.

### Case Presentation

An 11-year-old girl presented with leg pain, fever, headache, and vomiting since one day prior

to admission. She had gone swimming in the Persian Gulf the night before her admission and remembered that a starfish had bitten her leg while swimming.

A physician visited the patient, who was admitted with the impression of starfish biting. Her symptoms included vomiting and her weakness worsened during admission; she received Apotel (paracetamol) and hydrocortisone with the impression of reaction to starfish bite. Additionally, she developed a yellowish discoloration of urine. Her vital signs were: blood pressure 150/100 mmHg, pulse 98 beats per



**Figure 1.** Bone marrow smear (A:  $\times 20$  and B:  $\times 100$ ). 1C: The karyotype study of the bone marrow culture.

**Table 1.** Laboratory findings in our case report

Variable	Results	Variable	Results
WBC	4,200 / $\mu$ L(82% lymphocyte, 12% neutrophil, and 6 % atypical lymphocyte)	CRP	Negative
Hb	9.2 g/dl	PT	13 seconds
MCV	75 fl	PTT	34 seconds
Platelet	109,000/ $\mu$ L	Total Protein	5.8 g/dL
ESR	78 mm/h	Albumin	3.6 g/dL
LDH	1800 U/L	ALT	19 U/L
BUN	38 mg/dl	AST	49 U/L
Cr	2.8 mg/dl	ALP	563 U/L
Calcium	9 mg/dl	Total bilirubin	0.6 mg/dL
Phosphate	6.2 mg/dL	Direct bilirubin	0.2 mg/dL
Uric acid	7.6 mg/d	PH	7.30
Fasting blood sugar	96 mg/dl	HCO <sub>3</sub>	19 mg/dL
		PCO <sub>2</sub>	34 torr
		Potassium	4.2 mEq/L
		Sodium	132 mEq/L

White blood cells (WBC), hemoglobin (Hb), mean corpuscular volume (MCV), erythrocyte sedimentation rate (ESR), lactate dehydrogenase (LDH), blood urea nitrogen (BUN), creatinine (Cr), C-reactive protein (CRP), prothrombin time (PT), partial thromboplastin time (PTT), alanine aminotransferase (ALT), aspartate transaminase (AST), alkaline phosphatase (ALP)

minute, respiration 18 breathes per minute, and temperature 37.2 °C (99 F). Optic disc was sharp and there was no evidence of papilledema. Other physical examinations were normal. The urine output was 1.3 ml/kg/24 hours.

Laboratory results showed high blood urea nitrogen (BUN): 38 mg/dl and creatinine (Cr): 2.8 mg/dl which increased to 3.8 mg/dl during the three days of hospital admission (Table 1). Urine analysis showed 2+ proteinuria and 2+ bloods with red blood cells (RBC): 20-25 RBC/HPF in the urine. The urinary system sonography showed a mild increased parenchymal echogenicity suggestive of infiltrative disorder or renal injury in both kidneys without evidence of any stone. After consultation with the pediatric nephrologist, due to intractable vomiting and hypertension, the case underwent three-time dialysis. Simultaneously, a pediatric hematologist provided consultation due to the few atypical cells in peripheral smear, anemia, and mild thrombocytopenia, recommending BM aspiration and trephine biopsy. Therefore, she was transferred to an oncology hospital, and BM aspiration and biopsy revealed more than 90 % lymphoblast (Figure 1A and 1B). The detailed results of immunophenotyping were provided by flow cytometry method performed on the BM of the case by a panel of antibodies designed in the

Faghihi Hospital Pathology Center for Leukemia Study. A population of cells was selected on SSC/CD45 and SSC/ FSC scattergram. The selected population accounted for 90% of the total cells, had immature B cell phenotype, and was positive for HLADR, CD34, CD45, CD10, CD19, and TDT. Additionally, this population was negative for CD13, CD33, MPO, CD11, CD117, CD14, CD 64, CD61, CD 3, CD5, CD 7, and CD2, which was compatible with acute precursor B lymphoblastic leukemia.

The karyotype study of BM culture revealed derivative chromosome 1 with inversion 1q and duplication 1q, translocation (6; 9), and deletion 9p (Figure 1C). Therefore, we initiated chemotherapy as a high-risk acute precursor B lymphoblastic leukemia protocol including dexamethasone, vincristine, doxorubicin, and PEG-L-asparaginase.

During induction, kidney function became normal 10 days following the initiation of chemotherapy. On day 14 of induction chemotherapy, the BUN and Cr were 21 mg/dl and 0.9 mg/dl, respectively. Kidney sonography was performed every week and parenchymal echogenicity of both kidneys became normal on the third week of induction chemotherapy. BM aspiration was indicative of remission and good response to treatment on day 14 and at the end

of induction.

Cerebrospinal fluid analysis showed no evidence of leukemic involvement. Currently, she is in remission and in intensification phase of chemotherapy.

## Discussion

Renal presentations of ALL are rare in children. So far, the reported renal system presentation of ALL in children includes acute renal failure,<sup>5, 6</sup> renal calculi,<sup>7</sup> nephromegaly,<sup>8</sup> and hematuria.<sup>9</sup> The mechanism of renal involvement in ALL can be attributed to uric acid nephropathy because of hyperuricemia and tumor lysis syndrome.<sup>5, 10</sup> The renal failure caused by this mechanism normally occurs after the start of chemotherapy. Our patient initially presented with acute renal failure prior to chemotherapy; however, it seems that this mechanism does not play a role in the development of renal failure in our patients.

Another mechanism associated with renal failure in patients with leukemia, which seems to be our patient's compliance with this mechanism, includes infiltration of leukemic cell in renal interstitium. These leukemic cells cause vascular stasis and reversible kidney injury.<sup>5, 6</sup>

In the literature review, renal involvement is usually seen with T cell ALL.<sup>5</sup> However, in our case report, it was associated with B cell ALL; also, she had no poor prognostic sign except age. Noteworthy, in case of ALL with renal involvement, the most optimal treatment is an early chemotherapy.

In our patient, clinical symptoms, laboratory findings, and kidney ultrasound results became normal with the initiation of chemotherapy. Laboratory findings including azotemia became normal on day 10 of induction chemotherapy while renal ultrasound became normal on the third week of induction chemotherapy. In addition, supportive care such as dialysis seems helpful.

## Conclusion

Acute renal failure can be a rare initial presentation of ALL. In addition, azotemia can be improved with early chemotherapy treatment.

## Informed Consent

Written informed consent was obtained from the parents.

## Conflict of Interest

None declared.

## References

1. Cooper SL, Brown PA. Treatment of pediatric acute lymphoblastic leukemia. *Pediatr Clin North Am.* 2015;62(1):61-73.
2. Inaba H, Greaves M, Mullighan CG. Acute lymphoblastic leukaemia. *Lancet.* 2013;381(9881):1943-55.
3. Hunger SP, Mullighan CG. Acute lymphoblastic leukemia in children. *N Engl J Med.* 2015;15:373(16):1541-52.
4. Sadawaite S, Jijina F, Nair CK, Seth S, Ghosh K. An unusual presentation of pediatric acute lymphoblastic leukemia. *Indian J Hematol Blood Transfus.* 2008;24(2):59-62.
5. Asdahl PH, Warner LF, Bendix K, Hasle H. Acute renal failure and normal blood count: A rare presentation of T-cell acute lymphoblastic leukemia. *Leuk Res Rep.* 2014;3(1):14-6.
6. Bhatia NG, Sneha LM, Selvan SM, Scott JJ. Acute renal failure as an initial manifestation of acute lymphoblastic leukemia. *Indian J Nephrol.* 2013;23(4):292-3.
7. Daly GF, Barnard EB, Thoreson L. Renal calculi: An unusual presentation of T-cell acute lymphoblastic leukemia. *Pediatrics.* 2016;137(1).
8. Martins A, Cairoli H, Domínguez P, Martin S, Ortiz C, Potasznik J, et al. Nephromegaly: as unusual presentation of acute lymphoblastic leukemia in an infant. [Article in Spanish]. *Arch Argent Pediatr.* 2008;106(3):263-5.
9. Marwaha RK, Kulkarni KP. Hematuria and renal involvement at presentation in acute lymphoblastic leukemia. *Saudi J Kidney Dis Transpl.* 2012;23(5):1088-9.
10. Jones DP, Stapleton FB, Kalwinsky D, McKay CP, Kellie SJ, Pui CH. Renal dysfunction and hyperuricemia at presentation and relapse of acute lymphoblastic leukemia. *Med Pediatr Oncol.* 1990;18(4):283-6.