

Granulosa Cell Tumor-like Variant of Endometrioid Carcinoma of the Ovary with Osseous Metaplasia: Report of a Rare Case

Kavita Mardi[†], Neelam Gupta, Shivani Sood, Manju Rao

Department of Pathology, Indira Gandhi Medical College, Shimla, India

Abstract

The sex cord-like variant of endometrioid carcinoma is a rare subtype with a close histological resemblance to the sex cord-stromal tumor of the ovaries, in particular the Sertoli cell tumor. However, very few cases of the granulosa cell tumor-like variant have been reported since it is commonly misdiagnosed as a granulosa cell tumor. Immunohistochemistry is useful in the diagnosis of these tumors as they are typically negative for inhibin alpha. We herein describe the histological and immunohistochemical features of a rare case of granulosa cell tumor-like variant of endometrioid carcinoma of the ovary with extensive areas of hyalinization, calcification and osseous metaplasia in a 45-year-old female patient.

Keywords: Endometrioid carcinoma, Sex cord variant, Granulosa tumor-like variant, Ovary

Introduction

The sex cord-like variant of endometrioid adenocarcinoma is a rare tumor that histologically closely resembles the sex cord-stromal tumor of the ovaries.¹ Despite its rarity, the correct histological diagnosis of the sex cord-like variant of endometrioid adenocarcinoma is crucial to avoid misdiagnosis of a less aggressive tumor. Still rarer are the ones with extensive hyalinization, calcification and osseous metaplasia.² We herein report a rare case of granulosa cell

tumor-like variant of endometrioid carcinoma of the ovary with extensive areas of hyalinization, calcification and osseous metaplasia in a 45-year-old female patient.

Case Report

A 45-year-old female patient was admitted with complaints of a slowly increasing mass in her abdomen since 15 years and lower abdominal pain since 3 months. There was a history of increased frequency of micturition and decreased appetite. Patient had

†Corresponding Author:
Kavita Mardi, MD, DNB
12-A, Type V Quarters, IAS
Colony, Kasumpti, Shimla, H.P
Tel: 9418063130
Email: kavitamardi@yahoo.co.in

polymenorrhagia for 5 years but was menopausal since 5 months. On examination, there was a huge mass of 24-28 weeks size in the lower abdomen that arose from the pelvis, firm-to-hard in consistency, with an indiscernable lower border of growth and restricted side-to-side mobility. Serum CA-125 was 171.84 u/ml. Ultrasonography of the pelvis revealed a heterogenous mass with solid components that measured 15×15 cm in the right adnexa. The possibility of a malignant ovarian tumor was suggested. The patient underwent an exploratory laparotomy with total abdominal hysterectomy and bilateral salpingo-oophorectomy. An ovarian tumor of 20×15 cm, with a smooth surface was identified on the right side. The cut section was partly solid and partly cystic with areas of necrosis (Figure 1). A polypoidal grey-white growth was identified in the fundus of the uterine cavity.

The histologic features of the tumor were similar to those of a granulosa cell tumor with small tumor cells that had round-to-ovoid nuclei, bland nuclear chromatin and scanty eosinophilic cytoplasm. Cells were predominantly arranged in a microfollicular pattern (Figure 2). There were areas that showed a cordlike arrangement of the tumor cells surrounded by hyalinized collagen tissue. Also present were areas that had marked dystrophic calcification and osteoid metaplasia (Figure 3). However, focally the tumor exhibited histologic characteristics of a conventional

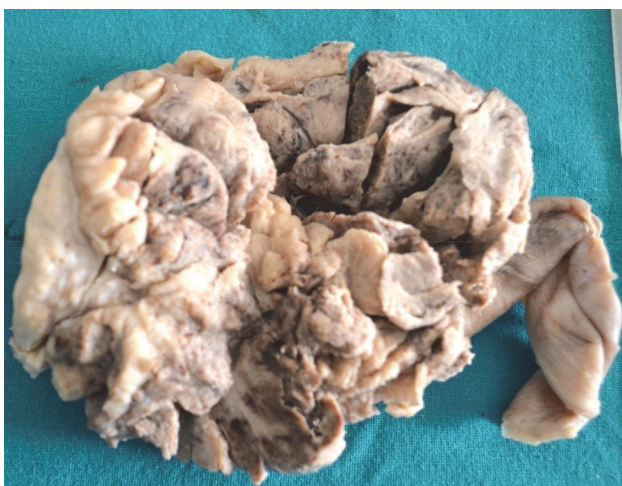

Figure 1. Gross specimen of partly solid cystic ovarian mass.

endometrioid carcinoma, with the tumor cells arranged in a glandular and microglandular pattern. In these areas the tumor cells showed pseudostratification, ovoid-to-elongated vesicular nuclei, prominent nucleoli, moderate amounts of eosinophilic cytoplasm and frequent atypical mitotic figures. The tumor involved the endometrium with invasion into the superficial myometrium. Immunohistochemically, the tumor cells were diffusely positive for cytokeratin (AE1/AE3) as seen in figure 4. They were negative for inhibin alpha.

Discussion

Ovarian endometrioid carcinomas are the second most common type of ovarian surface epithelial malignancies after serous carcinomas. The sex cord-like variant of endometrioid carcinoma is a rare subtype that closely histologically resembles the sex cord-stromal tumor of the ovaries, in particular the Sertoli cell tumor.³⁻⁶ However, few cases of the granulosa cell tumor-like variant have been reported, which suggests this tumor may often be hidden under the diagnosis of granulosa cell tumor. Because the granulosa cell tumor-like variant is pathologically similar to the granulosa cell tumor, showing only some dissimilarities to the latter, it can easily be misdiagnosed if the possibility of this variant is not kept in mind. Identification of the typical endometrioid histologic features or related lesions

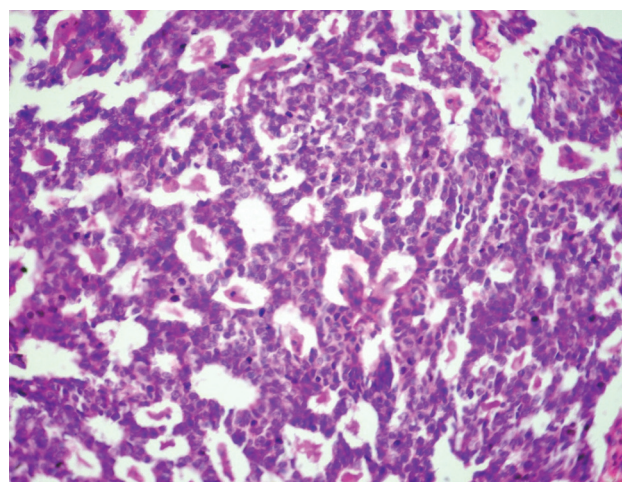


Figure 2. Photomicrograph showing granulosa cell tumor-like area revealing microfollicular pattern (H&E, 40×).

or immunohistochemistry may lead to a proper diagnosis. Fujibayashi et al.⁷ have observed nuclear clearing with biotin activity in nonmorular nests of a case of granulosa cell tumor-like variant of endometrioid carcinoma of the ovary which suggests that this tumor has endometrioid epithelial characteristics.

Only a few cases with the granulosa cell tumor-like variant of endometrioid carcinoma have been reported in the literature,^{4,5} perhaps because of its apparent rarity.⁸ In addition, granulosa cell tumors occur during a wide age range with its peak incidence in postmenopausal women between 50 and 55 years of age (approximately 60%), thus overlapping in age range with endometrioid carcinoma. Many cases of granulosa cell tumor-like variant of endometrioid carcinoma may be hidden under the diagnosis of granulosa cell tumor; in fact, there have been several reported cases in which the diagnosis of the referring pathologist or the first diagnosis of the tumor was granulosa cell tumor^{4,8} or in other cases, the diagnosis of granulosa cell tumor was corrected to sex cord-like variant of endometrioid carcinoma following immunohistochemical analysis for inhibin alpha.⁹

Calcification has been reported in a wide range of both primary neoplasms and metastatic diseases of the ovary. Psammomatous calcification is likely to account for the majority of calcified disease in the ovaries, particularly in cases of serous cyst ade-

nocarcinomas. However, amorphous calcification, as seen in the present case is known to occur in psammomatous calcification where the psammoma bodies act as niduses for the deposition of new layers of calcification.¹⁰ Burkil et al.¹¹ studied the significance of calcification in a series of ovarian tumors and concluded that tumor calcification in ovarian metastases is a dynamic process independent of treatment effects and therefore, can not be used as a marker of disease status. Benign osseous metaplasia in ovarian tumors is rare and its histogenesis remains unclear. However, it is probable that a metaplastic process involving multipotential stromal stem cells results in bone formation. As far as we know, this process does not appear to have any prognostic or pathological significance.¹²

In conclusion, because the granulosa cell tumor-like variant is pathologically similar to the granulosa cell tumor, showing only some dissimilarities to the latter, it can easily be misdiagnosed if the possibility of this variant is not kept in mind. Identification of the typical endometrioid histologic features or related lesions or immunohistochemistry may lead to a proper diagnosis.

Conflict of Interest

No conflict of interest is declared.

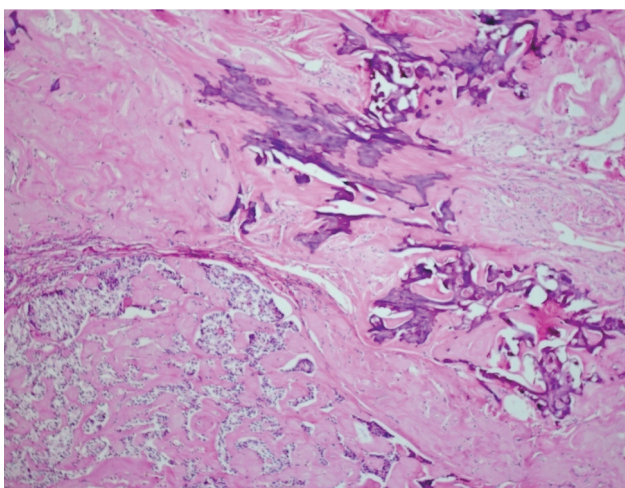


Figure 3. Areas showing extensive hyalinization and calcification in the tumor (H&E, 20×).

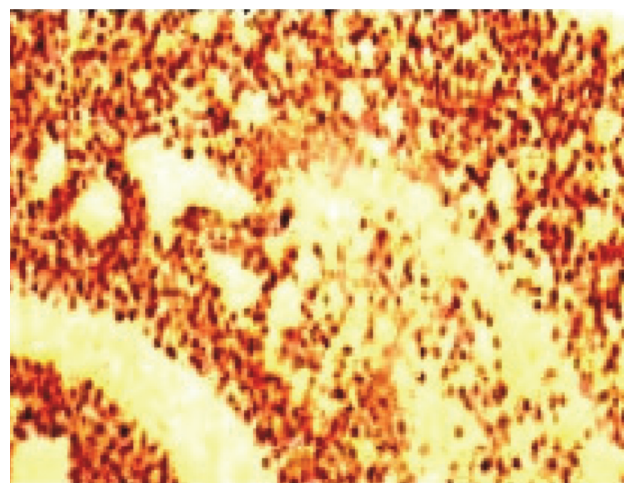


Figure 4. Tumor cells positive for cytokeratin 7 (IHC, 40×).

Reference

1. Kauppila S, Altinörs M, Väre P, Liakka A, Knuuti E, Nissi R. Primary sex cord-like variant of endometrioid adenocarcinoma arising from endometriosis. *APMIS*. 2008;116(9):842-5.
2. Murray SK, Clement PB, Young RH. Endometrioid carcinomas of the uterine corpus with sex cord-like formations, hyalinization, and other unusual morphologic features: a report of 31 cases of a neoplasm that may be confused with carcinosarcoma and other uterine neoplasms. *Am J Surg Pathol*. 2005;29(2):157-66.
3. Remadi S, Ismail A, Tawil A, MacGee W. Ovarian sertoliform endometrioid carcinoma. *Virchows Arch*. 1995;426(5):533-6
4. Guerrieri C, Franlund B, Malmstrom H, Boeryd B. Ovarian endometrioid carcinomas simulating sex cord-stromal tumors: a study employing inhibin and cytokeratin 7. *Int J Gynecol Pathol*. 1998;17(3):266-71.
5. Matias-Guiu X, Pons C, Prat J. Mullerian inhibiting substance, alpha-inhibin, and CD99 expression in sex cord-stromal tumors and endometrioid ovarian tumor resembling sex cord-stromal tumors. *Hum Pathol*. 1998;29(8):840-5.
6. Ordi J, Schammel DP, Rasekh L, Tavassoli FA. Sertoliform endometrioid carcinomas of the ovary: a clinicopathologic and immunohistochemical study of 13 cases. *Mod Pathol*. 1999;12(10):933-40.
7. Fujibayashi M, Aiba M, Iizuka E, Igarashi A, Muraoka M, Takagi K. Granulosa cell tumor-like variant of endometrioid carcinoma of the ovary exhibiting nuclear clearing with biotin activity: a subtype showing close macroscopic, cytologic, and histologic similarity to adult granulosa cell tumor. *Arch Pathol Lab Med*. 2005;129(10):1288-94.
8. Young RH, Prat J, Scully RE. Ovarian endometrioid carcinomas resembling sex cord-stromal tumors: a clinicopathological analysis of 13 cases. *Am J Surg Pathol*. 1982;6(6):513-22.
9. Pelkey TJ, Frierson HF Jr, Mills SE, Stoler MH. The diagnostic utility of inhibin staining in ovarian neoplasms. *Int J Gynecol Pathol*. 1998;17(2):97-105.
10. Maile CW, Rodan BA, Godwin JD, Chen JTT, Ravin CE. Calcification in pulmonary metastases. *Br J Radiol*. 1982;55(650):108-13.
11. Burkil GJC, Allen SD, Ahren RP, Gore ME, King MD. Significance of tumour calcification in ovarian carcinoma. *Br J Radiol*. 2009;82(980):640-4.
12. Mukonoweshuro P, Oriowolo A. Stromal osseous metaplasia in a low-grade ovarian adenocarcinoma. *Gynecol Oncol*. 2005;99(1):222-4.