

Case Report

Middle East Journal of Cancer 2011; 2 (3 & 4): 139-142

Carcinoid Tumor of the Common Bile Duct Misdiagnosed as Cholangiocarcinoma

Ali Eishi Oskuie, Nasim Valizadeh*

Department of Hematology/Medical Oncology, Urmia University of Medical Sciences, Urmia, Iran

Abstract

Carcinoid tumors of the bile duct are rare. Despite cholangiocarcinoma, they grow more slowly and generally occur in younger patients and females. These tumors have a better prognosis and more disease-free survival. We present the case of a 25-year-old male with common bile duct (CBD) carcinoid tumor misdiagnosed as cholangiocarcinoma.

Keywords: Cholangiocarcinoma, Carcinoid tumor, Common bile duct

Introduction

Carcinoid tumors of the extrahepatic bile ducts are quite rare, ¹⁻⁵ accounting for only 0.2%-2% of all gastrointestinal carcinoids.² Signs and symptoms are not specific and may be similar to bile duct stones.⁴

Carcinoid syndrome and symptoms of hormone production have not been reported in carcinoid tumors of the bile ducts. However, obstructive jaundice, biliary colic, and pruritus are common manifestations.⁶ We present a case of carcinoid tumor of the common bile duct (CBD) in a 25-year-old male who presented with abdominal pain and jaundice, initially misdiagnosed as cholangiocarcinoma.

Case Report

A 25-year-old male presented with abdominal pain and intermittent jaundice since 1 month before admission. Past medical history was unremarkable. Physical examination revealed only jaundice. CBC differential, PT, PTT, CEA, and AFP were normal, however AST, ALT, bilirubin and alkaline phosphatase were elevated (Table 1). Additionally, the patient's CA19-9 level was elevated at 120 u/ml (normal: <37).

Abdominal sonography showed increased diameter of the proximal part of the CBD to 15 mm. There was a 13 mm mass, suggestive of lymphadenopathy and CBD obstruction. Endosonography showed a proximal CBD tumor (17×9 mm) adjacent to the portal vein. The proximal CBD diameter was 16 mm.

*Corresponding Author:

Nasim Valizadeh, MD
Department of Hematology,
Medical Oncology, Urmia
University of Medical Sciences,
Urmia, Iran
Tel: +98-9125474755
Email: nседaha0@gmail.com



MRCP revealed an intraluminal 20×19 mm mass in the distal of the common hepatic duct and proximal of the CBD, suggestive of cholangiocarcinoma of the CBD. The patient underwent a laparotomy and cholecystectomy, with CBD tumor resection, lymph node biopsy, and Roux-en-Y hepaticojejunostomy reconstruction. The initial pathology was reported as cholangiocarcinoma of the CBD with perineural invasion (Figures 1A, B). Pathology samples and biopsy were sent to an expert pathologist, who reported carcinoid tumor of the CBD (Figures 2A, B). IHC study was strongly positive for chromogranin and NSE (Figures 2C, D). In this young male with abdominal pain, jaundice, and elevated liver enzymes, we found a carcinoid tumor of the CBD, initially misdiagnosed as cholangiocarcinoma. The patient is currently disease-free, at 4.5 years after surgery.

Discussion

Neuroendocrine tumors of the bile ducts are exceedingly rare.¹⁻⁴ Unlike cholangiocarcinoma, they grow more slowly and generally occur in younger patients and females, with better prognosis and more disease-free survival, even in the presence of metastasis.

Aggressive surgery with complete resection in patients with biliary carcinoid tumor leads to prolonged overall survival, even in cases with metastases.^{2, 6-9} In most patients, excision of the

Table 1. Laboratory results of the patient.

Unit	Result	Test
×10 ³ /μl	4.8	WBC
g/dl	15.3	Hb
×10 ³ /μl	245	Platelets
mg/dl	2*	Total bilirubin
mg/dl	1.1*	Direct bilirubin
unit/l	52*	AST
unit/l	78*	ALT
unit/l	368*	Alk ph
gr/dl	4.7	Albumin
ng/ml	5	AFP

*High

extrahepatic bile ducts with portal lymphadenectomy and Roux-en-Y hepaticojejunostomy surgery leads to complete tumor clearance.¹⁰

Similar to other cases with carcinoid tumors of the CBD, our patient has achieved a prolonged disease-free survival 4.5 years after surgery.

In contrast to cholangiocarcinoma, the beneficial effects of adjuvant radiotherapy and/or chemotherapy are not approved for CBD carcinoid tumors.^{11, 12}

Despite advanced and metastatic cholangiocarcinoma, surgery should be considered, even in metastatic patients with bile duct carcinoid tumors.⁷

Pre-surgical assessments are not adequate to discriminate between cholangiocarcinoma and bile duct carcinoids, thus histology and IHC are necessary for diagnosis.^{6, 13} We recommend tissue diagnosis and IHC study in any young patient

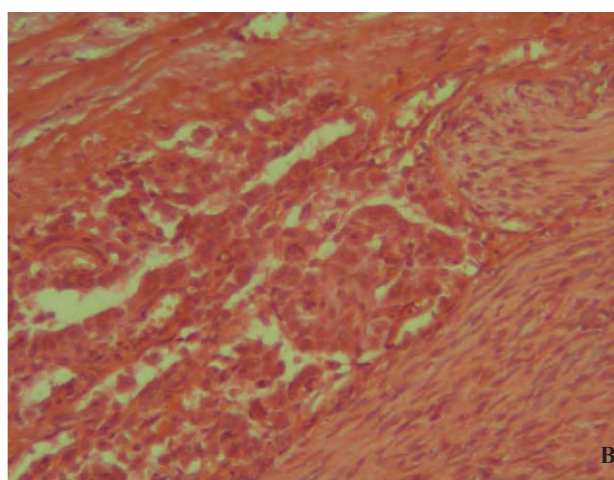
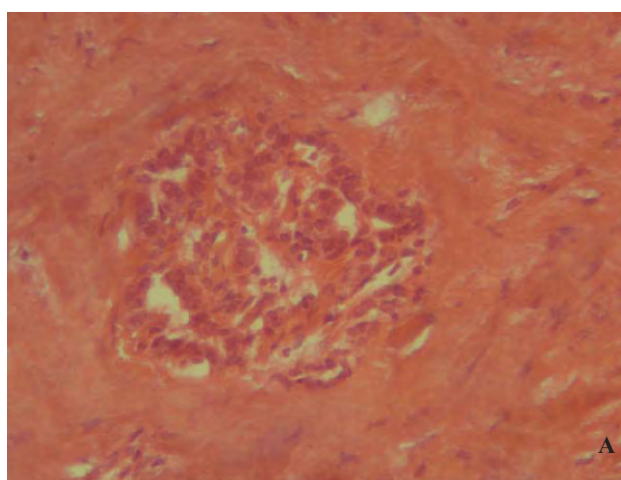


Figure 1. A-Small glandular structures which often appear deceptively bland. The nuclei are often quite oval and vesicular. There is characteristically a dense sparsely cellular fibrous stroma (H & E, 400×); B-Tumoral cells invading to perineural area (H & E, 400×).

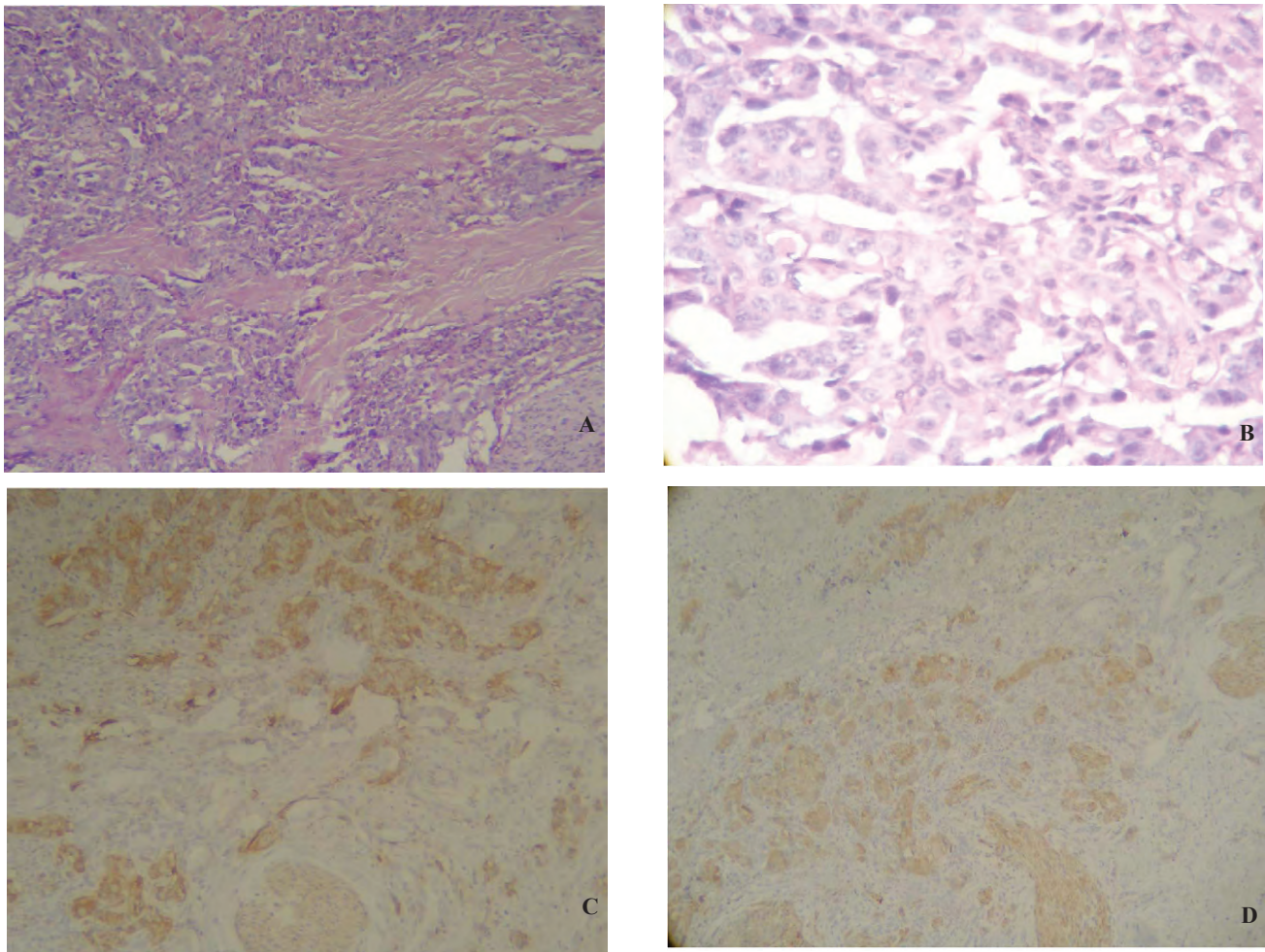


Figure 2. A-Mild to moderate pleomorphic tumoral cells and a nerve in the lower right corner (H & E, 200×); B-Scattered hyperchromatic bizarre cells (H & E, 400×); C-IHC staining was positive for chromogranin (100×); D-IHC staining was positive for NSE protein (100×).

with bile duct tumors. The IHC study is recommended for all young patients with diagnoses of cholangiocarcinoma. Physicians should consider carcinoid tumor of the bile duct in the differential diagnosis of bile duct tumors, particularly in younger patients and those with mild elevations of CA19-9.

Acknowledgements

We express our appreciation to Drs. Abbas Saffarifard and Pantea Rohanidoost, residents of the Pathology Department in Urmia University of Medical Sciences who photographed the pathology slides of this patient.

References

1. Rugge M, Sonogo F, Militello C, Guido M, Ninfo V. Primary carcinoid tumor of the cystic and common bile ducts. *Am J Surg Pathol* 1992;16:802-7.
2. Chamberlain RS, Blumgart LH. Carcinoid tumors of the extrahepatic bile duct. A rare cause of malignant biliary obstruction. *Cancer* 1999;86:1959-65.
3. Hao L, Friedman AL, Navarro VJ, West B, Robert ME. Carcinoid tumor of the common bile duct producing gastrin and serotonin. *J Clin Gastroenterol* 1996;23(1):63-5.
4. Jensen SI, Pless T, Mortensen MB. Carcinoid tumor of the choledochus mimicking a bile-duct stone during endoscopic ultrasonography and endoscopic retrograde cholangiography. *Endoscopy* 2001;33:100.
5. El Rassi ZS, Mohsine RM, Berger F, Thierry P, Partensky CC. Endocrine tumors of the extrahepatic bile ducts. Pathological and clinical aspects, surgical management and outcome. *Hepatogastroenterology* 2004;51:1295-300.
6. Caglikulekci M, Dirlik M, Aydin O, Ozer C, Colak T, Dag A, et al. Carcinoid tumor of the common bile duct: Report of a case and a review of the literature. *Acta Chir Belg* 2006;106:112-5.
7. Davies AJ. Carcinoid tumor (argentaffinomata). *Ann R Coll Engl* 1959;36:560-9.
8. Pawlik TM, Shah S, Eckhauser FE. Carcinoid tumor

- of the biliary tract: Treating a rare cause of bile duct obstruction. *Am Surg* 2003;69:98-101.
9. Hubert C, Sempoux C, Berquin A, Deprez P, Jamar F, Gigot JF. Bile duct carcinoid tumors: An uncommon disease but with a good prognosis? *Hepatogastroenterology* 2005;52:1042-7.
 10. Sethi H, Madanur M, Srinivasan P, Portmann B, Heaton N, Rela M. Non-functioning well-differentiated neuroendocrine tumor of the extrahepatic bile duct: An unusual suspect? *Hepatobiliary Pancreat Dis Int* 2007;6(5):549-52.
 11. Saltz L, Kemeny N, Schwartz G, Kelsen D. A phase II trial of alpha-interferon and 5-fluorouracil in patients with advanced carcinoid and islet cell tumours. *Cancer* 1994;74:958-61.
 12. Conti AR, Cusumano F, Baticci F, Salvadori B. Clinical considerations on 8 cases of abdominal carcinoids. *Tumori* 1981;67(2):145-9.
 13. Pithawala M, Mittal G, Prabhu RY, Kantharia CV, Joshi A, Supe A. Carcinoid tumor of bile duct. *Indian J Gastroenterol* 2005;24:262-3.