

Cervical Lymph Node Metastases from Meningioma: Report of Two Cases and Treatment Outcome

Shapour Omidvari[♦], Hamid Nasrolahi^{*}, Yahya Daneshbod^{**},
Neda Bagheri^{**}, Shahrzad Negahban^{**}, Mohammad Mohammadianpanah^{*},
Niloofar Ahmadloo^{*}, Mansoor Ansari^{*}, Ahmad Mosalaei^{*}

**Department of Radiation Oncology, Nemazee Hospital, Shiraz University of Medical Sciences, Shiraz, Iran*

***Dr. Daneshbod Pathology Lab, Shiraz, Iran*

Abstract

Meningioma is usually a benign central nervous system (CNS) tumor. Metastasis is rare; however if it does occur the most metastatic sites are the liver and lungs. Here, two cases of CNS meningioma with metastasis to cervical lymph nodes are reported. The first case, a 48 year-old man developed cervical lymph node metastasis nine years after primary tumor diagnosis. The second case, a 23 year-old woman with parietal lobe meningioma, developed lymph node metastasis in the neck nine months after the diagnosis of meningioma.

Keywords: Meningioma, Metastasis, Lymph node, Neck

Introduction

Meningioma is a common CNS tumor that occurs more frequently in the elderly.¹ Treatment consists of surgery. However, according to both the pathology and type of surgery (Simpson's grade), radiotherapy may be indicated.² Approximately one per thousand patients may develop metastasis^{3,4} for which no defined treatment schedule exists.⁵ Although there are a considerable number of reports of metastatic meningioma, there are only a few case series. Here we present two patients cervical

lymph node metastasis who demonstrated two different responses to the treatment modalities that were implemented.

Case 1

In July 1999, a 38 year-old man presented with blurred vision in the left eye and left facial paresthesia. Brain MRI images demonstrated a mass in the parasellar region with invasion of the cavernous sinus (Figure 1). The patient underwent partial tumor resection and a diagnosis of meningioma was established by pathologic examination.

♦Corresponding Author:

Shapour Omidvari MD,
Department of Radiation
Oncology, Nemazee Hospital,
Shiraz University of Medical
Sciences, Shiraz, Iran
PO Box: 71937-11351
Tel: +98-711-6125884
Fax: +98-711-6474320
E-mail: omidvari@sums.ac.ir

The patient received postoperative external beam radiotherapy and a total dose of 54 Gy was delivered to the involved fields. He was clinically free of disease for a period of nine years, when he developed left upper cervical lymphadenopathy (Figure 2). Concurrently, the patient's brain MRI disclosed local recurrent disease in the temporal lobe.

Core needle biopsy of the cervical lymph node revealed metastatic carcinoma with extensive necrosis as seen by light microscopic examination. However, the immunohistochemical study was positive for cytokeratin which was consistent with metastatic meningioma (Figure 3).

At present, the patient is undergoing a chemotherapy regimen of gemcitabine and cisplatin with partial regression of his neck lesion. The patient's characteristics are depicted in Table 1.

Case 2

In January 2007, a 23 year-old female presented with complaints of severe headache, convulsions and diplopia. The patient's brain MRI showed a mass in the mid and posterior parietal region with edema, significant contrast enhancement and nonhomogeneous signal intensity (Figure 4). The patient underwent surgery with complete tumor resection. Histopathologic examination was positive for meningioma with anaplastic

transformation. The patient subsequently received postoperative external beam radiotherapy with a total dose of 54 Gy that was delivered to the tumor bed. Nine months later, the patient developed multiple cervical lymphadenopathies. A neck CT scan demonstrated bilateral large lymph nodes of variable sizes that involved both the anterior and posterior triangles. Some cervical lymphadenopathies showed central necrosis with peripheral enhancement. The lymphadenopathies extended to both supraclavicular regions. An excisional biopsy of the cervical lymphadenopathies showed a malignant metastatic tumor as seen by light microscopic examination. Immunohistochemical studies were positive for EMA (focally) and S100 (diffuse) which confirmed the diagnosis of metastatic meningioma (Figures 5-6). Metastatic work-up including a chest CT scan as well as abdominal and pelvic ultrasonography excluded other sites of metastatic disease.

She received systemic interferon alpha2-b and external beam radiotherapy with a total dose of 50 Gy to the entire cervical lymph nodes. However, the patient's cervical lymphadenopathies progressed rapidly and she died five months following the onset of recurrent neck disease. The patient's characteristics are depicted in Table 1.

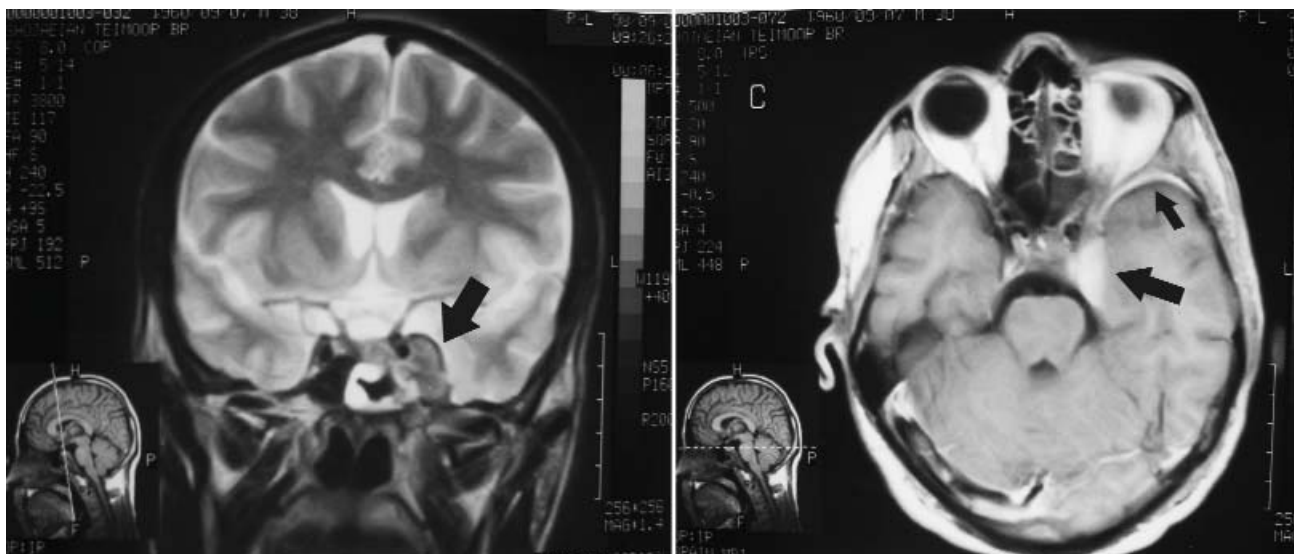


Figure 1. Coronal T2 and axial contrast enhanced T1 weighted MRI images of the head show a well circumscribed parasellar brain tumor (large arrow) with dural tail (small arrow) consistent with meningioma.

Table 1. Patient characteristics, treatments and outcomes.

Patients characteristics	Case 1	Case 2
Age at diagnosis (yrs.)	38	23
Gender	Male	Female
Primary site histology subtype	Benign meningioma	Anaplastic meningioma
Time to metastasis	9 years	9 months
Treatment modality	Gemcitabine and cisplatin	Radiotherapy to neck followed by interferon alpha 2-b
Response to treatment	Partial response	No response
Outcome	Patient is alive after 1.5 years	Patient died after 5 months

Discussion

Meningioma is a common CNS tumor,^{6,7} whose prevalence ranges from 14 to 26% of primary intracranial tumors.^{3,8} The peak incidence occurs during the sixth and seventh decades of life, with a female to male ratio of 2:1.^{1,7} Meningiomas are typically slow growing and benign; however like leiomyomas, they can metastasize in 0.1% of all patients.^{3,4} Meningiomas can spread via hematogenous, lymphatic and cerebrospinal fluid routes. The most common route is hematogenous.⁹ According to WHO classification, there are three grades of meningioma of which grade 1 is benign. Grade 2 or atypical meningioma consists of more than 4 mitoses per 10 high power field, an increase in cellularity, small cells with high nuclei to cytoplasm ratios, small nucleoli, patternless

growth, and spontaneous or geographic necrosis. Grade 3 is anaplastic meningioma.^{3,10} Metastases usually occur with high grade tumors; however, a high rate of cellular proliferation is not essential for metastasis. Metastasis can occur with any of the histological patterns.^{4,9} The most common site of metastasis is the lung, which account for 61% of all cases.⁶ Liver and intra-abdominal metastases account for 30% of all metastases whereas lymph node and bone metastases are less frequently seen.^{3,9} Metastasis can occur within a few months or even years following diagnosis of the primary disease. Metastases as long as 20 years after primary tumor diagnosis have been reported in the literature.^{9,11,12} In our first patient, metastasis occurred after nine years; however in the second patient metastasis presented after nine months.

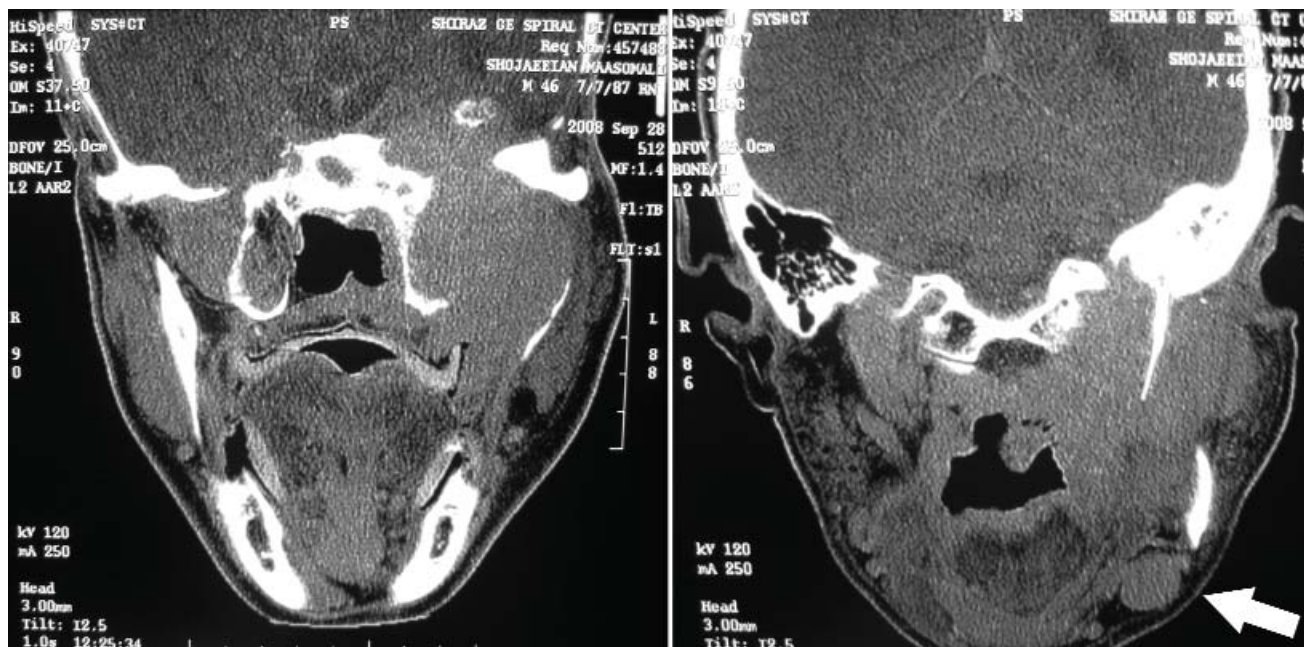


Figure 2. Recent coronal CT scan shows a mass in the parasellar region with skull base destruction, extending to the left buccal area and left submandibular lymph node (arrow).

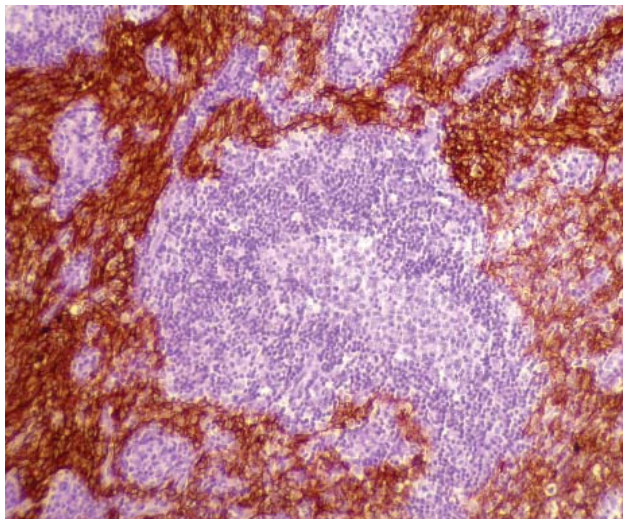


Figure 3. Immunohistochemical staining of the lymph node showing nests of epithelioid cells which are positive for cytokeratin (immunoperoxidase, 300 \times).

Most deaths are due to uncontrolled CNS tumor rather than metastasis, *per se*.¹³

As has been previously reported the treatment of choice for meningioma is surgery.^{7,14} Simpson described five grades of resection: biopsy is labeled as grade 5, grade 4 refers to partial resection, grade 3 includes gross total resection, whereas grade 2 is gross tumor resection and dural attachment, and finally grade 1 is the removal of hyperostotic bone.² Borovich et al., in 1986, proposed grade 0 resection as a wide dural excision.¹⁵ After incomplete resection of the primary tumor, treatment with adjuvant radiotherapy can decrease the chance of recurrence

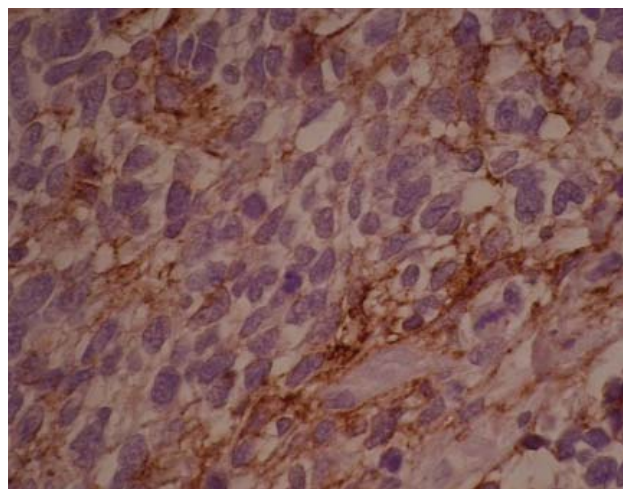


Figure 5. Immunohistochemical staining of lymph node showing focal positivity for epithelial membrane antigen (EMA) in epithelioid cells (immunoperoxidase, 300 \times).

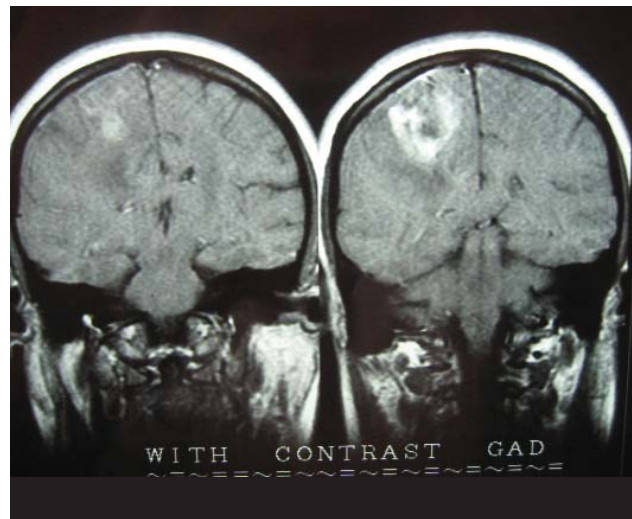

Figure 4. Coronal gadolinium enhanced MRI of the head shows a mass arising from the posterior parietal region with significant enhancement.

from 90% to 41%.^{7,16} Management of unresectable meningioma is a challenge because there are limited therapeutic options.⁵

Sioka et al. have suggested that administration of interferon alpha2-b can produce long lasting remission in a rapidly growing meningioma.⁵ However that study was based on CNS meningioma. Our second patient received interferon alpha2-b which did not show a response.

There is no proven effective chemotherapy agent for treating meningioma.¹⁷ In some studies irinotecan and hydroxyurea have had a marginal response.⁵ Our first patient has a stable disease condition with partial response to gemcitabine

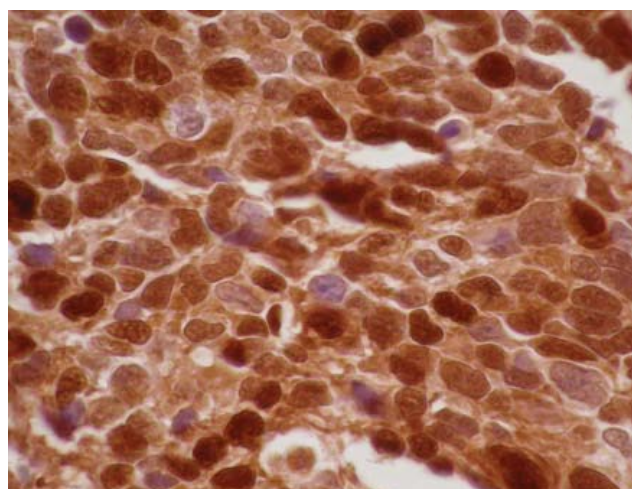


Figure 6. Immunohistochemical staining of lymph node showing diffuse staining for S100 of epithelioid cells (immunoperoxidase, 300 \times).

and cisplatin.

The different behaviors of disease in our patients may partially be due to differences in primary tumor grade or treatment modality. We have found no study or case report that have used the combination of gemcitabine and cisplatin. At present, there is no proven treatment for metastatic meningioma however gemcitabine and cisplatin may be promising and need to be further studied in future trials.¹⁶

References

1. Lamszus K. Meningioma pathology, genetics, and biology. *J Neuropathol Exp Neurol* 2004;63(4):275-86.
2. Simpson D. The recurrence of intracranial meningiomas after surgical treatment. *J Neurol Neurosurg Psychiatry* 1957;20(1):22-39.
3. Pramesh CS, Saklani AP, Pantvaidya GH, Heroor AA, Naresh KN, Sharma S, et al. Benign metastasizing meningioma. *Jpn J Clin Oncol* 2003;33(2):86-8.
4. Figueroa BE, Quint DJ, McKeever PE, Chandler WF. Extracranial metastatic meningioma. *Br J Radiol* 1999;72(857):513-6.
5. Sioka C, Kyritsis AP. Chemotherapy, hormonal therapy, and immunotherapy for recurrent meningiomas. *J Neuro Oncol* 2009;92(1):1-6.
6. Yekeler E, Dursun M, Yilmazbayhan D, Tunaci A. Multiple pulmonary metastases from intracranial meningioma. MR imaging findings (case report). *Diagn Interv Radiol* 2005;11(1):28-30.
7. Whittle IR, Smith C, Navoo P, Collie D. Meningiomas. *Lancet* 2004;363(9420):1535-43.
8. Marosi C, Hassler M, Roessler K, Reni M, Sant M, Mazza E, et al. Meningioma. *Crit Rev Oncol Hematol* 2008;67(2):153-71.
9. Delgado-López PD, Martín-Velasco V, Castilla-Díez JM, Fernández-Arconada O, Corrales-García EM, Galacho-Harnero A, et al. Metastatic meningioma to the eleventh dorsal vertebral body: total en bloc spondylectomy. Case report and review of the literature. *Neurocirugia (Astur)* 2006;17(3):240-9.
10. Magu SK, Gupta MK, Behl A. Malignant meningioma - clinicopathological study of an unusual presentation of a rare malignancy. *Armed Forces Med J India* 2003;59(2):166-8.
11. Opsahl R Jr, Löken AC. Meningioma with metastases to cervical lymph nodes; Case report. *Acta Pathol Microbiol Scand* 1965;64(3):294-8.
12. Lee GC, Choi SW, Kim SH, Kwon HJ. Multiple extracranial metastases of atypical meningiomas. *J Korean Neurosurg Soc* 2009;45(2):107-11.
13. Leighton SE, Rees GL, McDonald B, Alun-Jones T. Metastatic meningioma in the neck. *J Laryngol Otol* 1991;105(3):229-31.
14. Chamberlain MC, Glantz MJ. Cerebrospinal fluid-disseminated meningioma. *Cancer* 2005;103(7):1427-30.
15. Borovich B, Doron Y, Braun J, Guilburd JN, Zaaroor M, Goldsher D, et al. Recurrence of intracranial meningiomas: The role played by regional multicentricity. Part 2: Clinical and radiological aspects. *J Neurosurg* 1986;65(2):168-71.
16. Ramina R, Neto MC, Fernandes YB, Aguiar PH, de Meneses MS, Torres LF. Meningiomas of the jugular foramen. *Neurosurg Rev* 2006;29(1):55-60.
17. Modha A, Gutin PH. Diagnosis and treatment of atypical and anaplastic meningiomas: A review. *Neurosurgery* 2005;57(3):538-50.