

Case Report

Middle East Journal of Cancer; October 2022; 13(4): 717-722

Ovarian Yolk Sac Tumor Coexisting with the Involvement of the Fallopian Tube in an Eight-Month-Old Girl: A Rare Case Report

Salahedin Delshad*, MD, Naser Piri***, MSc, Zahra Mirmoghadam***, MSc, Farzane Sharifi****, MD,

*Department of Pediatric Surgery, Maryam Hospital, Alborz University of Medical Sciences, Karaj, Iran

**Department of Epidemiology, Alborz University of Medical Sciences, Karaj, Iran

***Deputy of Health, Alborz University of Medical Sciences, Karaj, Iran

****Department of Pathology, Fardis central Laboratory, Alborz University of Medical Sciences, Karaj, Iran

Abstract

Yolk sac tumors (YSTs) of the ovary are rare neoplasms, accounting for less than 0.2% of all ovarian tumors. Although this malignancy is much rarer in children, pediatric cases are attributed to a poorer prognosis. Diagnosis of YST is often made by post-operative pathologic examination. The prevalent clinical presentations include fever, distended abdomen or asymptomatic abdominal mass. YST rarely coexists with involvement of fallopian tube and this entity is rare in children.

The present research was conducted to present a rare case of ovarian YST in an 8-month-old female infant with involvement of fallopian tube. This report, presents a rare case of YST in terms of its clinical presentation, histopathology findings, imaging findings, diagnosis, and treatment. The patient underwent surgical resection of the mass, followed by pathological examination, which confirmed an ovarian YST. To the best of our knowledge, this case is the youngest case of ovarian YST with the involvement of the fallopian tube reported in literature.

Keywords: Ovarian neoplasms, Malignancy, Asymptomatic abdominal mass, Pediatrics, Case report

Introduction

Yolk sac tumors (YSTs) are germ cell tumors (GCTs) that are highly malignant. The malignancy was primarily described by Teillum in 1976. Most tumors of the ovary can

be placed into one of the three major categories based on their origin: surface epithelial-stromal tumors, sex cord-stromal tumors, and GCTs. GCTs are uncommon malignancies occurring predominantly in children

Please cite this article as: Delshad S, Piri N, Sharifi F, Mirmoghadam Z. Ovarian yolk sac tumor coexisting with the involvement of the fallopian tube in an eight-month-old girl: a rare case report. Middle East J Cancer. 2022;13(4):717-22. doi: 10.30476/mejc.2021.89096.1505.

Corresponding Author:

Naser Piri, MSc
Department of Epidemiology,
Maryam Hospital, Alborz
University of Medical Sciences,
Karaj, Iran
Tel: +982633512462
Fax: 33512459
Email: piri.naser1989@gmail.com



and young women.¹ The annual incidence of malignant ovarian tumors is reported to be 0.7/100,000 in 0-14-year-old females.² YSTs most frequently occurs in the second and third decades of life. Some of these tumors are bilateral, while most of them are unilateral. These tumors tend to grow rapidly; therefore, the duration of clinical manifestations is very short. As a result, timely diagnosis and treatment will be of great importance. Here, we describe a novel case of Ovarian yolk sac tumor (OYST) coexisting with a fallopian tube tumor involvement.

Case Presentation

This study was approved by the Ethics Committee of Alborz University of Medical Sciences, and informed consent was obtained from the patient's parents. The code of ethics of this study is IR.ABZUMS.REC.1388.298. An 8-month-old girl was admitted to our hospital with the chief complaint of abdominal pain for 2 months and a change in urine color to pink color, from 4 months ago. Physical examination revealed a unilateral adnexal mass, otherwise normal. Ultrasound examination revealed a stone in the right kidney. The dimensions of the stones were reported to 4×3×2 mm. In addition, the sonography stated that the right kidney was approximately 22×53 mm and the left kidney was 23×54 mm. Also, the renal parenchyma was normal. In the bladder lumen, hyperdense foci in the dependent portion of the lumen was seen, which was in

favor of small stones.

In the urine analysis, several brown stones of calcium oxalate (60%) and uric acid (40%) were found. Alpha-fetoprotein (AFP) level was increased significantly (22300 IU/mL, Normal Range<6), while the beta-HCG level was normal. According to the results of clinical examination and ultrasonography, the patient was admitted for surgery with the diagnosis of a pelvic mass.

Surgery

In the pelvic exploration, a mass measuring 5×3.5×3.5 cm was observed. The mass originated in the salpinx portion of the right fallopian tube, which is attached to the right ovary. Masses from the right ovary and right fallopian tube were resected. Also, the negative margins of the masses were carefully resected (Figure 1-a, 1-b). The ovaries and fallopian tubes were normal (Figure 1-c). No other tumors were observed in the pelvic exploration. The patient was discharged 4 days after the operation and recovered well. The patient was then referred to the oncologist for further treatment and under stringent follow-up. It should be noted that there was no family history of cancer.

Histopathology report

Macroscopic anatomy showed an ovarian mass consists of multiple fragments of irregular grayish-brown tissue, a total of 5×3.5×3.5cm. Simultaneous involvement of the right fallopian tube was also observed. Also, Paratubal tissue was composed of two small fragments of irregular creamy-gray tissue, totally 0.5×0.5×0.3cm.

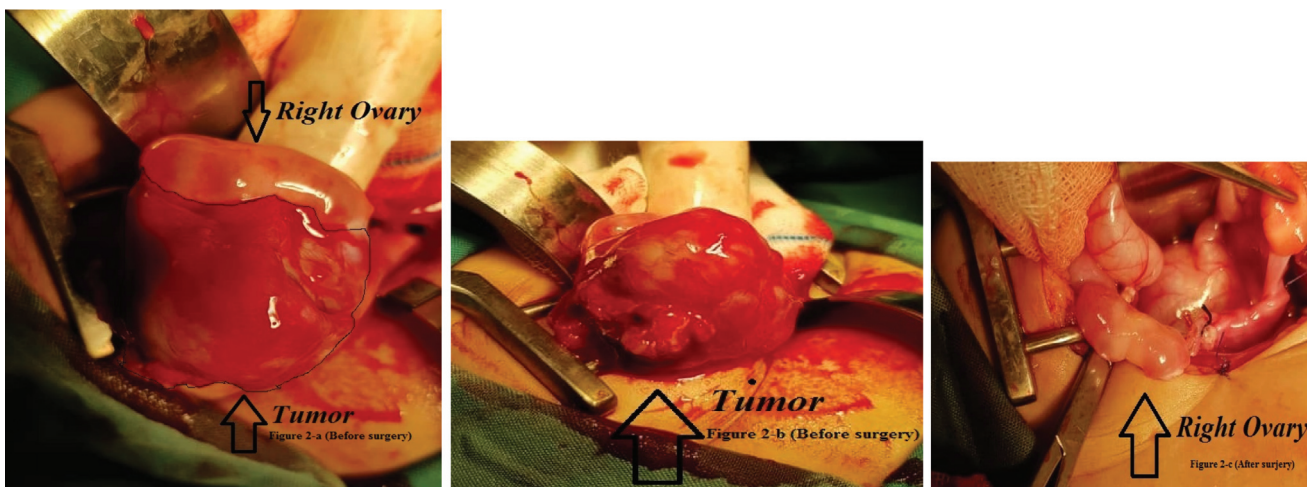

Figure 1. (a, b, and c) In this figure, the ovarian photos are displayed.

Microscopic study

Microscopically sections showed a malignant tumor composed of pleomorphic cells with large

hyperchromatic nuclei and clear to eosinophilic cytoplasm arranged in reticular or microcystic area, pseudopapillary processes with central

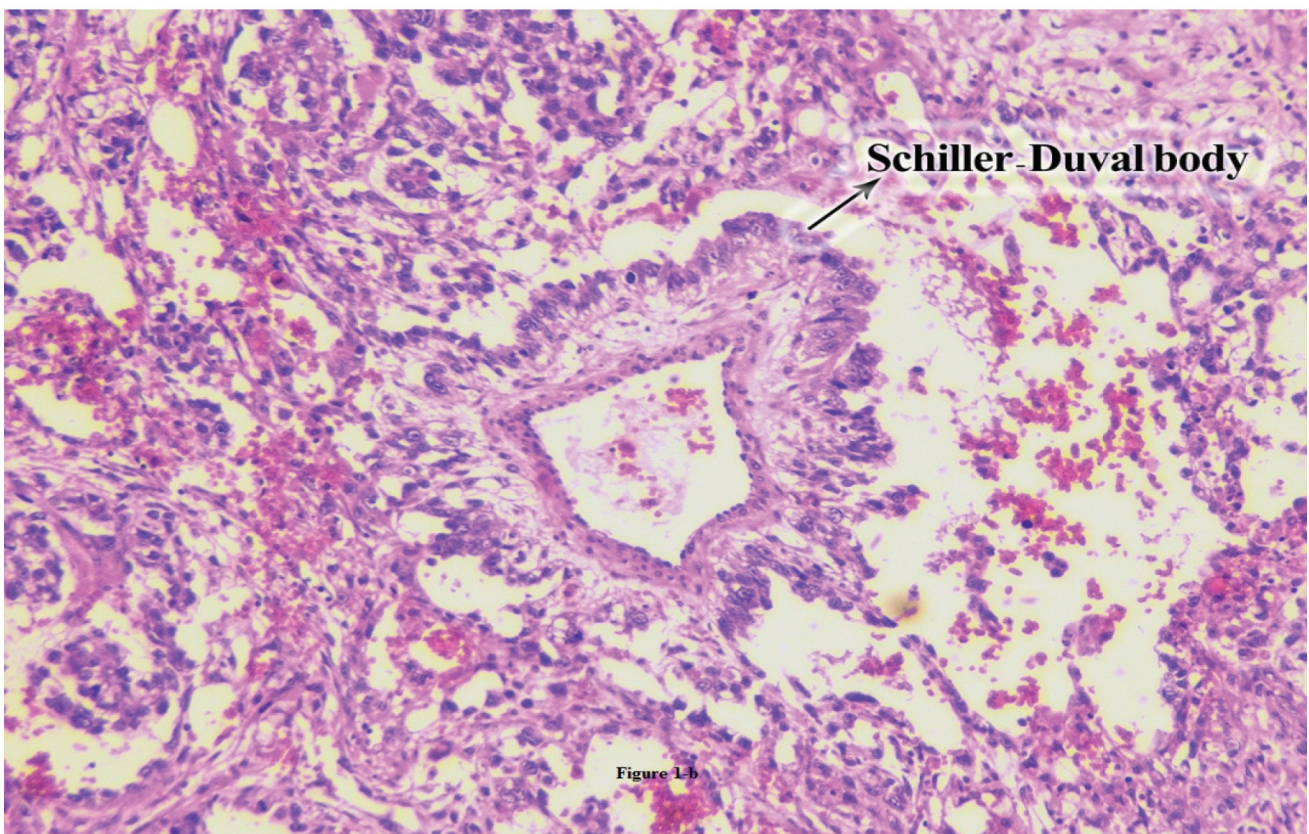
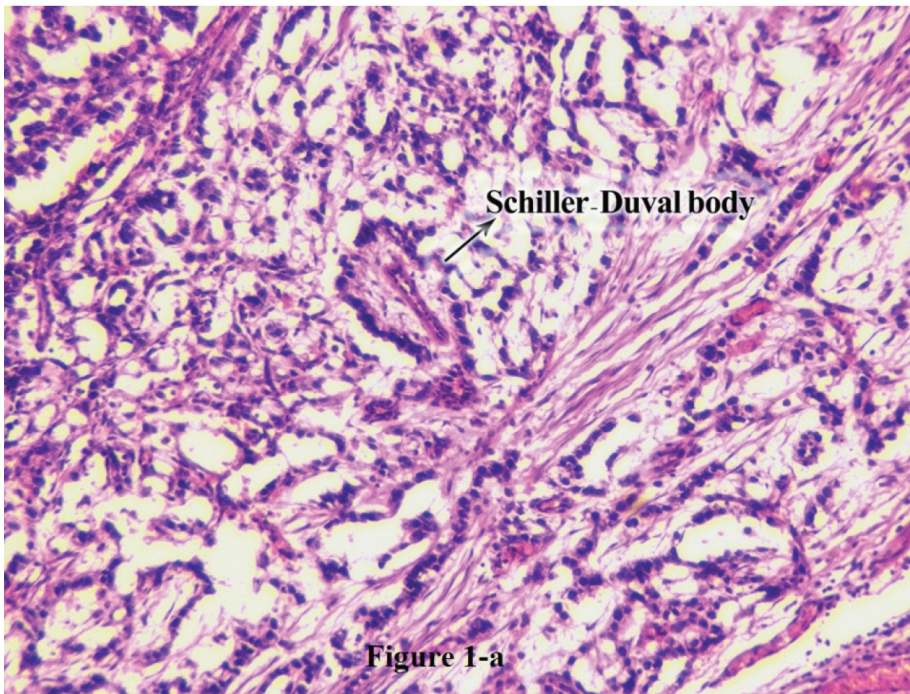


Figure 2. Histological sections of YST show overview of reticular pattern with multiple Schiller-Duval bodies (a) and close-up of Schiller-Duval body (b).

YST: Yolk sac tumor

vessels (Schiller-Duval bodies), and small solid area. Also, some hyaline globules in the cytoplasm of tumor cells were found. The final diagnosis consisted of a right ovarian mass with simultaneously tumor involvement of the fallopian tube that was the result of a biopsy of the right para tubal tissues. The immunohistochemistry (IHC) was compatible with the YST. (ICD-10: code 56.1 and ICD-O-3: code 9071/3).³ The tumor had a germ cells type appearance with Schiller-Duval bodies (Figure. 2-a, 2-b). Schiller-Duval bodies, which consist of fibro-vascular papillae covered by columnar tumor cells projecting into glands of cystic spaces lined by cuboidal cells, are characteristic and diagnostic of YST.⁴ Also, some hyaline globules in the cytoplasm of tumor cells were seen. The presence of the hyaline globules and positive AFP has also been utilized as markers in the cytopathological diagnosis of YSTs.⁵

In our case, before the operation, on IHC, tumor cells were positive for AFP (more than 22300 IU/ml) and negative for Beta-hCG (less than 2.0 IU/L). But exactly, 3 weeks after the operation, the AFP level was dramatically dropped (512.6 IU/ml). However, its level was still high (The normal range in our case is 0-99 IU/ml). The AFP level in umbilical cord blood at birth can be up to 100 mg/L, and then gradually decreases.⁶

Discussion

OYST is the second germinal malignancy after dysgerminoma. Pediatric GCTs are rare childhood tumors accounting for less than 3% of pediatric malignancies.^{4,6} Clinical symptoms of an ovarian YST consist of enlarging abdominal or pelvic mass (median diameter 15 cm). Abdominal pain is the most prevalent symptom. Because abdominal pain is a common disorder in children, this symptom has less sensitivity in the infant compare with other age groups. However, patients with OYSTs have a significantly worse prognosis. The patients suffering from this kind of tumor may have vaginal bleeding, fever, ascites, or peritonitis secondary to torsion, hemorrhage, infection, or tumor rupture.⁷ Duration of symptoms

is often brief due to the rapid growth. The etiology of YSTs of the ovary is still poorly understood. Magnetic resonance imaging (MRI) is so useful in making a preoperative diagnosis of YST and distinguishing YST from other malignant ovarian tumors. The final diagnosis of YST is usually confirmed following pathologic examination after surgery. Due to the rarity of this ovarian neoplasm in infants, little information about the causes of this tumor during pregnancy and postpartum especially in infants has been released. This can be one of the limitations of the study. From 2010 to 2019, only 17 cases of YST were reported. The youngest case was 9 months old and the eldest 13 years.⁸

Differential diagnoses consist of clear cell or endometrioid carcinoma of the ovary, embryonal carcinoma, Sertoli-Leydig cell tumor, juvenile granulosa cell tumor, dysgerminoma, and metastatic hepatocellular carcinoma.⁵ FIGO (International Federation of Gynecology and Obstetrics) stage at diagnosis, residual disease after surgery, and declining AFP levels are prognostic markers in GCTs. In our patient, the FIGO stage was determined as IIA. Generally, the FIGO stage of 75% of all ovarian malignancies rang from stage two to stage four at diagnosis.^{9, 10} Sonographic features, in combination with clinical information and immunohistochemical markers of YSTs [(S-CA 125, Beta-hCG, glypican-3 and SALL-like protein 4 (SALL4), S-AFP, AFP and other plasma proteins (albumin, prealbumin, urantitrypsin, transferrin, haptoglobin, Gc-globin, urmacroglobulin, hemopexin, ceruloplasmin, IgG, IgA and Cluster of Differentiation (CD) markers in immunology consist of CD99, CD34, CD31, CD17, CD68)], can aid in the diagnosis of ovarian YSTs, although negative tumor markers do not exclude the possibility of malignancy.¹¹

Our case also underwent serial serum AFP determinations, which can be a reliable indicator for monitoring the results of treatment and early detection of metastases and recurrences. The national comprehensive cancer network (2016) recommends that patients who completed clinical course are monitored by AFP every 2 to 4 months for 2 years after treatment.⁶

In most infants, serum AFP levels decrease to normal adult levels within the first 8-10 months, while in a significant proportion of children AFP levels do not normalize until the end of the 2nd year of life. Although childhood ovarian malignancy is not prevalent, it poses a clinical challenge due to its varied histologic nature and fatal outcome. Regardless of their malignant potential, YSTs are treated effectively with a combination of surgery and chemotherapy. Optimal management includes surgery, followed by the administration of platinum (cisplatin)-based multi-agent chemotherapy regimen. BEP (Bleomycin, etoposide, and platinum) therapy with fertility-conserving surgery is the gold standard resulting in long remissions and successful pregnancy.^{9, 12} Here it should be noted that follow-up consist of clinical evaluation, abdominal imaging (ultrasound, CT or MRI) and evaluating their level of the serum alpha-fetoprotein.

Conclusion

To the best of our knowledge, this case is the youngest case of OYST with the involvement of the fallopian tube that has been reported in the literature. Since surgery is the primary therapeutic action for ovarian tumors, preservation of ovaries and reproductive function use of a minimally invasive surgical technique is crucial.

Acknowledgment

This case report has been adapted from a Maryam Hospital in the Alborz University of Medical Sciences. We thank Dr. F.Sharifi for providing technical guidance for immunohistochemistry. We would like to thank Dr. Parham Mardi for his help in the study. We would like to thank all Maryam hospital staff assisted in this study. Finally, we wish to thank our parents for their all support and encouragement over the years.

Informed Consent

We obtained written informed consent from the parent for the publication of this case report

and any accompanying images.

Conflict of Interest

None declared.

References

1. Calaminus G, Bamberg M, Baranzelli MC, Benoit Y, di Montezemolo LC, Fossati-Bellani F, et al. Intracranial germ cell tumors: a comprehensive update of the European data. *Neuropediatrics*. 1994;25(1):26-32. doi: 10.1055/s-2008-1071577.
2. Taskinen S, Fagerholm R, Lohi J, Taskinen M. Pediatric ovarian neoplastic tumors: incidence, age at presentation, tumor markers and outcome. *Acta Obstet Gynecol Scand*. 2015;94(4):425-9. doi: 10.1111/aogs.12598.
3. Trott P. International classification of diseases for oncology. *J Clin Pathol*. 1977;30(8):782. doi: 10.1136/jcp.30.8.782-c.
4. de La Motte Rouge T, Pautier P, Rey A, Duvillard P, Kerbrat P, Troalen F, et al. Prognostic factors in women treated for ovarian yolk sac tumour: a retrospective analysis of 84 cases. *Eur J Cancer*. 2011;47(2):175-82. doi: 10.1016/j.ejca.2010.08.012.
5. Saksela E. Immunohistochemical markers of yolk sac tumors. In: Francisco F, editor. *The Human yolk sac and yolk sac tumors*. 1st ed. Berlin: Springer; 1993. p. 216-27.
6. He Y, Lu H, Zhang L. Serum AFP levels in patients suffering from 47 different types of cancers and noncancer diseases. *Prog Mol Biol Transl Sci*. 2019;162:199-212. doi: 10.1016/bs.pmbts.2019.01.001.
7. Eddaoualline H, Sami H, Rais H, Belbaraka R, El Omrani A, Khouchani M. Ovarian yolk sac tumor: a case report and literature review. *Clin Case Rep Int*. 2018; 2:1057.
8. Kurman RJ, Norris HJ. Endodermal sinus tumor of the ovary: a clinical and pathologic analysis of 71 cases. *Cancer*. 1976;38(6):2404-19. doi: 10.1002/1097-0142(197612)38:6<2404::aid-cnrcr2820380629>3.0.co; 2-3.
9. Chen LH, Yip KC, Wu HJ, Yong SB. Yolk Sac Tumor in an eight-year-old girl: A case report and literature review. *Front Pediatr*. 2019;7:169. doi: 10.3389/fped.2019.00169.
10. Mahadik K, Ghorpade K. Childhood ovarian malignancy. *J Obstet Gynaecol India*. 2014;64(2):91-4. doi: 10.1007/s13224-014-0533-4.
11. Prat J; FIGO Committee on Gynecologic Oncology. FIGO's staging classification for cancer of the ovary, fallopian tube, and peritoneum: abridged republication. *J Gynecol Oncol*. 2015;26(2):87-9. doi: 10.3802/jgo.2015.26.2.87.
12. Anfelter P, Testa A, Chiappa V, Froyman W, Fruscio R, Guerriero S, et al. Imaging in gynecological disease

- (17): ultrasound features of malignant ovarian yolk sac tumors (endodermal sinus tumors). *Ultrasound Obstet Gynecol.* 2020;56(2):276-84. doi: 10.1002/uog.22002. Erratum in: *Ultrasound Obstet Gynecol.* 2020;56(6):966.
13. Nasioudis D, Chapman-Davis E, Frey MK, Caputo TA, Holcomb K. Management and prognosis of ovarian yolk sac tumors; an analysis of the National Cancer Data Base. *Gynecol Oncol.* 2017;147(2):296-301. doi: 10.1016/j.ygyno.2017.08.013.