

Multicentric Astrocytoma Presenting with Supra- and Infratentorial Involvement: A Case Report

Farhad Emadi*, Afshin Borhanihaghghi**♦

*Research Center for Traditional Medicine and History of Medicine and Department of Neurology, Shiraz University of Medical Sciences, Shiraz, Iran

**Transgenic Technology Research Center and Department of Neurology, Shiraz University of Medical Sciences, Shiraz, Iran

Abstract

This report describes the case of a 56 year-old man with a history of diplopia. His brain imaging showed multiple lesions with a metastatic appearance, however all investigations to determine the primary source of malignancy were negative. The patient underwent a brain biopsy, which was positive for anaplastic astrocytoma, a rare tumor that should be considered in the differential diagnosis of secondary brain tumors.

Keywords: Multiple brain lesions, Metastases, Astrocytoma

Introduction

The presence of multiple brain lesions in a patient is often due to metastases. However, this can also be seen in primary brain tumors that have a glial origin. Based on the Budka classification, multifocal gliomas are categorized into four groups: diffuse, multiple, multiple-organ and multicentric.¹ Since the introduction of multicentric gliomas by Bradley in 1880², a number of reports have been published. Of these, glioblastoma is the most common type of multicentric glioma. The clinical and radiological features of multicentric astrocytoma can be

quite misleading as a result of significant overlap with secondary malignancies and other histotypes of multicentric gliomas. Here, we present a patient with tissue confirmed multicentric astrocytoma.

Case Report

A 56 year-old man presented with a two week history of diplopia prior to admission. He had no known risk factors for cardiovascular diseases and his medical history was unremarkable. He did not smoke and there was no history of any occupational exposure to toxins or special chemical agents. General

♦Corresponding Author:

Afshin Borhanihaghghi, MD,
Department of Neurology,
Nemazee Hospital, Shiraz
University of Medical Sciences,
Shiraz, Iran
Tel/Fax: +98-711-6121065
E-mail: borhanihaghghi@yahoo.com

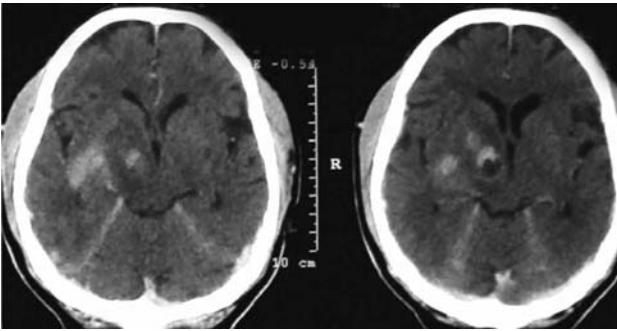


Figure 1. Axial brain CT scan showing multiple enhancing brain lesions.

physical examination was within normal limits. Neurologic examination showed a normal fundoscopy, recent memory impairment, binocular diplopia compatible with left 6th cranial nerve palsy and mild gait ataxia with a positive tandem gait. Brain CT scan showed multiple enhancing lesions (Figure 1), brain magnetic resonance imaging (MRI) demonstrated multiple separate lesions involving the right cerebral hemisphere, right thalamus and brain stem with an increased signal on T2 weighted and FLAIR sequences (Figure 2). There was marked enhancement of the lesions after injection of gadolinium (Figure 3). These MRI findings were suggestive of metastatic brain lesions. Thus the patient underwent a full workup to locate the possible primary source of the lesions, including: blood tests, urine and stool studies, chest and abdominal CT scans, whole body bone scan, endoscopy and colonoscopy. All tests were within normal ranges. Therefore, a stereotactic brain biopsy was taken from the right temporal mass. The pathologist noted fragments of astrocytic tumoral tissue with a neurofibrillary background, high cellularity, severe nuclear atypia and hyperchromasia, focal endothelial proliferation and a low mitotic count. These findings were compatible with anaplastic astrocytoma (Figure 4). Upon diagnosis, the patient began a series of radiotherapy and chemotherapy treatments. At the last follow up, his headache and diplopia had decreased. Brain MRI at follow up showed a decrease in the sizes of the lesions.

Discussion

We conducted a number of tests and

examinations to identify the primary source of malignancy in this patient who had multiple supra- and infratentorial ring enhancing lesions, however stereotactic brain biopsy revealed a diagnosis of multicentric glioma.

Multicentric gliomas (including astrocytomas) are uncommon lesions of the central nervous system.³⁻⁵ The terminology used in the literature is not uniform; as the term 'multifocal gliomas' describes all cases with two or more sites of tumor growth as well as a pathological defined subgroup of these cases.⁶ This results from dissemination by pathologically defined routes, either by direct extension or by metastasis through the cerebrospinal fluid or the blood^{4,6}, which does not occur in multicentric gliomas. Regarding the imaging investigations, only non-contiguous lesions are considered to be multicentric.⁷ Our patient is a case of multicentric glioma due to his imaging and pathology diagnosis (see Figures 1-4). When intracranial multiple lesions are found, metastatic brain tumors must initially be considered. However, both multicentric and multifocal gliomas can mimic metastatic brain lesions and a differential diagnosis should be made between them due to the different therapeutic strategies needed for treatment. Adult patients with multicentric gliomas commonly present with

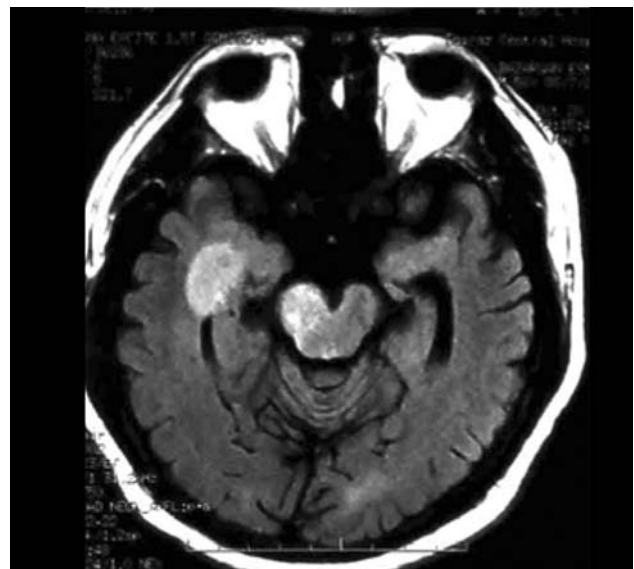


Figure 2. Axial brain MRI FLAIR images showing two separate hyperintense lesions, one at the right medial temporal lobe and another at the right cerebellar peduncle.

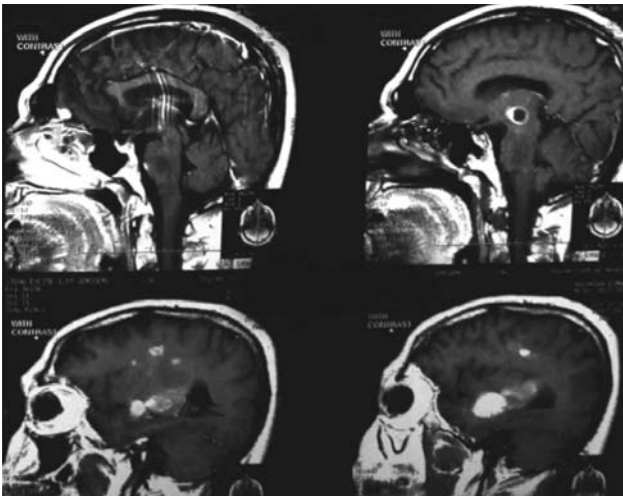


Figure 3. Sagittal brain MRI T1 images with gadolinium contrast administration showing multiple enhancing lesions.

symptoms and signs that could be explained by cerebral hemisphere lesions such as hemiparesis, decreased mental activity, aphasia and focal seizures.⁸ Our patient presented with signs of brain stem involvement. Multicentric gliomas usually involve the supratentorial compartment and supra-infratentorial involvement (as seen with our patient) has been rarely reported.⁴

The pathogenesis of multicentric gliomas is still unknown but there have been case reports of familial aggregation⁹, associations with phakomatosis¹⁰ and multiple sclerosis¹¹, and induction by radiation¹² which may shed light on this area. There have been some speculative pathomechanisms for its multicentricity. Willis hypothesized that an "initiation" neoplastic

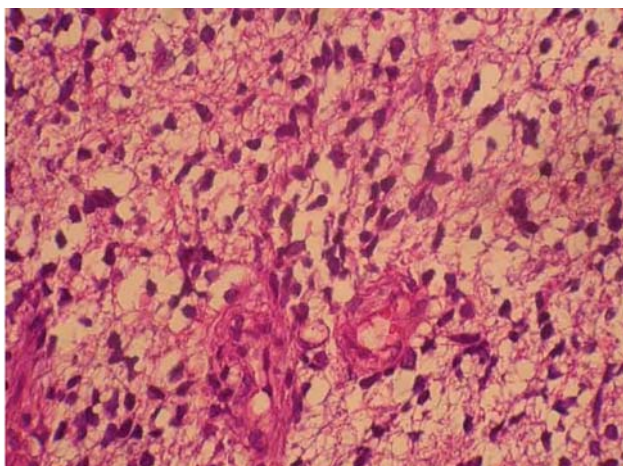


Figure 4. Astrocytic tumoral tissue with neurofibrillary background (H & E, 400×).

transformation commenced in a larger area followed by a secondary "promotion" proliferative process due to biochemical, hormonal, mechanical, or viral stimulation in particular sites. However Zulch has considered "multicentricity" to be "multifocality" due to currently unknown pathways of metastasis.⁴

In conclusion, this case reconfirms that multicentric gliomas should always be kept in mind in the differential diagnosis of multiple ring-enhancing brain lesions, in addition to an infectious process, inflammatory diseases and metastases. As neuroimaging studies have their own shortcomings, stereotactic brain biopsy and histopathologic examination should be conducted for definitive diagnosis.

Acknowledgement

We thank Dr. Yahya Daneshbod for preparation of the pathology slides.

References

1. Budka H, Podreka I, Reisner T, Zeiler K. Diagnostic and pathomorphological aspects of glioma multiplicity. *Neurosurg Rev* 1980;3(4):233-41.
2. Bradley WL. Case of gliosarcomatous tumors of the brain. *Proc Conn Med Soc* 1880;2:39-41.
3. Mishra HB, Haran RP, Singh JP, Joseph T. Multicentric gliomas: Two case reports and a review of the literature. *Br J Neurosurg* 1990;4(6):535-9.
4. Salvati M, Caroli E, Orlando ER, Frati A, Artizzu S, Ferrante L. Multicentric glioma: Our experience in 25 patients and critical review of the literature. *Neurosurg Rev* 2003;26(4):275-9.
5. Ozawa Y, Machida T, Noda M, Harada M, Akahane M, Kiryu S, et al. MRI findings of multiple malignant gliomas: Differentiation from multiple metastatic brain tumors. *Radiat Med* 1998;16(2):69-74.
6. Synowitz M, von Eckardstein K, Brauer C, Hoch HH, Kiwit JC. Case history: Multicentric glioma with involvement of the optic chiasm. *Clin Neurol Neurosurg* 2002;105(1):66-8.
7. Djalilian HR, Shah MV, Hall WA. Radiographic incidence of multicentric malignant gliomas. *Surg Neurol* 1999;51(5):554-8.
8. Khongkhatithum C, Visudtibhan A, Chiemchanya S, Visudhiphan P, Sanvivad P, Larbcharoensub N, et al. Multicentric anaplastic astrocytoma in a child. *J Clin Neurosci* 2007;14(2):176-9.
9. Iza B, Mateo-Sierra O, Ruiz-Juretszke F, Garbizu J, Guzmán de Villoria J, Carrillo R. Familiar glioblastoma

- presenting as a true multicentric tumor: Etiopathogenic and prognostic features. *Neurocirugia (Astur)*. 2006;17(4):340-6.
10. Saikali S, Le Strat A, Heckly A, Stock N, Scarabin JM, Hamlat A. Multicentric pleomorphic xanthoastrocytoma in a patient with neurofibromatosis type 1. Case report and review of the literature. *J Neurosurg* 2005;102(2):376-81.
 11. Kotwica Z, Papierez W. Cerebral and cerebellar glial tumors in the same individual. *Neurosurg* 1992;30:439-442.
 12. Tsutsumi S, Yasumoto Y, Ito M. Pediatric multicentric glioma occurring after cranial irradiation. *J Clin Neurosci* 2009;16(8):1086-8.