

Subcosto-midline Abdominal Incision: A New Incision for Resection of Large Renal Masses with or without Vascular Involvement

Mehdi Salehipour*, Reza Mohammadian, Abdolreza Haghpanah, Ali Ariafar,
Hadi Rezaee, Mohammadreza Jaafari

Department of Urology, Shiraz University of Medical Sciences, Shiraz, Iran

Abstract

Background: Renal cell carcinoma is the third most common urological cancer. Surgical resection is still the mainstay of treatment for this tumor. Here we present a new surgical approach for the management of locally advanced renal cell carcinoma.

Methods: We chose ten patients with extensive renal masses. The patient, under general anesthesia after preparation and draping, was placed in the supine position. We made either a right or left classic subcostal incision which was then extended as a midline incision through the linea alba to the lower abdomen. After mobilization of the right ascending or left descending colon, the renal artery and vein were detected, ligated and divided. Next, the involved kidney was released from the adjacent structures and removed, including Gerota's fascia.

Results: The study included 6 men (60%) and 4 women (40%) with a mean age of 57 years. Mean blood loss was 1500 mL and mean operative time was 180 minutes. The patients' surgical wounds were checked for two weeks after the operation; none of the patients developed wound infections or dehiscence. At the time of writing this manuscript, in January 2011, 7 patients (70%) were alive with no evidence of abdominal herniation at the surgical site.

Conclusion: A subcosto-midline incision or anterior triangular flap incision is a modified abdominal incision. In our experience, this incision is useful for the resection of locally advanced large renal masses.

Keywords: Renal cell carcinoma, Surgical resection

♦Corresponding Author:
Mehdi Salehipour, MD
Associate Professor of Urology
and Kidney Transplantation
Shahid Faghihi Hospital, Shiraz
University of Medical Sciences,
Shiraz, Iran
Tel: +98-711-2330724
Email:salehipourmehdi@yahoo.com

Introduction

Renal cell carcinoma (RCC) is the third most common urological cancer worldwide.¹ Since RCC is resistant to chemotherapy and

radiotherapy, surgical resection is still the mainstay of treatment for this tumor, even for advanced cases.² Until now, different open surgical approaches have been used for

successful radical nephrectomy. Here we present a new incision technique for the management of locally advanced RCC.

Materials and Methods

Patient Selection and Preoperative Evaluation

This study included ten patients with extensive renal masses who were treated by the Urology Department of Shiraz University of Medical Sciences between March 2009 and September 2010. Renal masses were detected by history, physical examination and abdominopelvic ultrasound, and later confirmed by abdominopelvic spiral computed tomography (Figure 1). All patients were admitted to Nemazee Hospital two days prior to surgery. Laboratory analyses included blood urea nitrogen, serum creatinine, sodium, potassium, hemoglobin, and liver function tests. Each patient also underwent a chest X-ray to check for possible lung metastases. Coagulopathy was ruled out in each patient. Since there was a probability of bowel involvement, each patient received bowel preparation before the operation.

Operative technique

The patient was administered general anesthesia and placed in the supine position. After preparation and draping, we made either a right or left classic subcostal incision which was extended as a midline incision through the linea

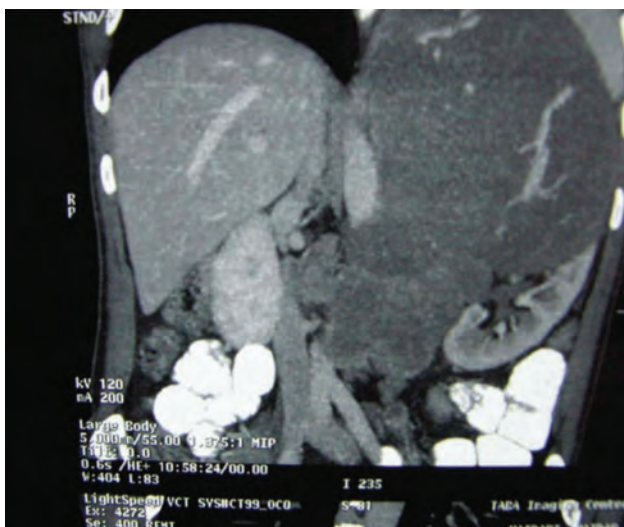

Figure 1. Large left renal mass.

alba to the lower abdomen. After making an incision in the subcutaneous tissue, the fasciomuscular layers of the anterior abdominal wall and the peritoneum, the surgeon created a triangular flap and retracted it outward (Figure 2A). The right ascending or left descending colon was mobilized, and the renal artery and vein were detected, ligated and divided. Then the involved kidney was released from adjacent structures and removed, including Gerota's fascia. In cases with invasion of the abdominal aorta or inferior vena cava (IVC), vascular reconstruction was performed after nephrectomy. After hemostasis and irrigation with saline solution, a Hemovac drain was inserted in the nephrectomy site. The peritoneum was closed with chromic 4-0 sutures and the fasciomuscular layer closed with running 1-0 PDS sutures. The skin was closed with nylon 3-0 mattress sutures. Bleeding was assessed by measuring the amount of blood in the suction machine container and counting the bloody gauzes and sponges.

Postoperative care

We transferred all patients to the intensive care unit after the operation for better postoperative care and management.

Results

We enrolled ten patients with extensive renal masses in this study. Their preoperative characteristics are listed in Table 1. The operations were well-tolerated by all patients. Of the ten patients, 4 (40%) required reconstruction of the IVC and 1(10%) underwent aortic reconstruction.

The operative findings are listed in Table 2. Early after the operation, one patient developed ileus that was successfully treated with insertion of a nasogastric tube and conservative management. The patients' surgical wounds were checked for two weeks postoperatively and none developed evidence of wound infection or dehiscence (Figures 2B and 2C). In one patient with a right renal mass and extensive involvement of the abdominal aorta, the left renal artery and kidney were also sacrificed during the operation. The patient subsequently required hemodialysis

and died six months later due to lung metastases and complicated renal failure. There were two other patients with extensive RCC (one on the right side and one on the left side) and aortic involvement who also died at one month and nine months after the operation. At the time of writing this manuscript in January 2011, 7 (70%) patients were alive with no evidence of abdominal herniation at the surgical site. The pathology findings of the renal masses from all patients are listed in Table 3.

Discussion

Renal cell carcinoma is the most lethal urological malignancy. Approximately 30% of patients with RCC develop metastatic disease, of whom 4% to 25% will have associated venous tumor thrombosis.³ Open radical nephrectomy is the standard of care in patients with large or locally advanced RCC.⁴ Until now, various incisions, each with advantages and disadvantages, have been proposed for removal of the renal mass. The choice of incision depends on several factors and includes the tumor size, surgeon's preference and experience, involvement of the adjacent organs or great vessels, and the patient's body habitus. A flank incision provides adequate exposure for small renal masses. Moreover, urologists are more familiar with the flank approach compared to other approaches, and it also offers an extraperitoneal approach with minimal manipulation of the peritoneal viscera. However, the inability to examine the intraperitoneal organs, minimal exposure to the renal vascular pedicle, and increased probability of vertebral disk disease deterioration are some of the disadvantages of this approach. In addition, venous return may be impaired during flank position procedures, which can lead to hypotension and cardiac arrhythmia.⁵

The anterior 11th rib incision is similar to the flank incision; however, this approach offers the benefits of a smaller incision, obviates the need to remove the rib, and minimizes the risk of pneumothorax.⁶

The anterior subcostal incision is a transperitoneal approach which is valuable for small to

medium-sized tumors. The advantages of this approach include the ability to examine the

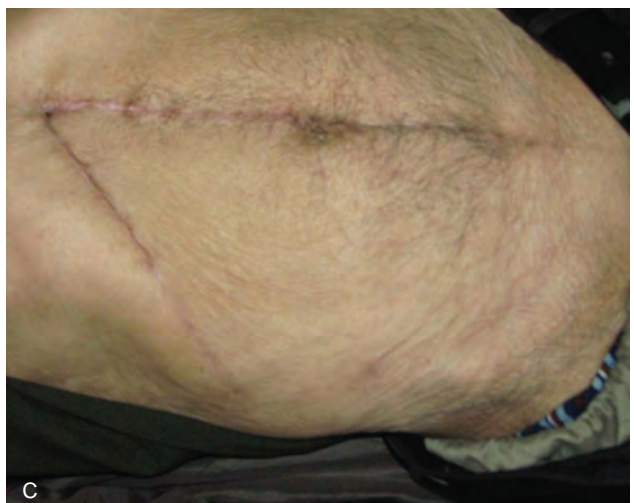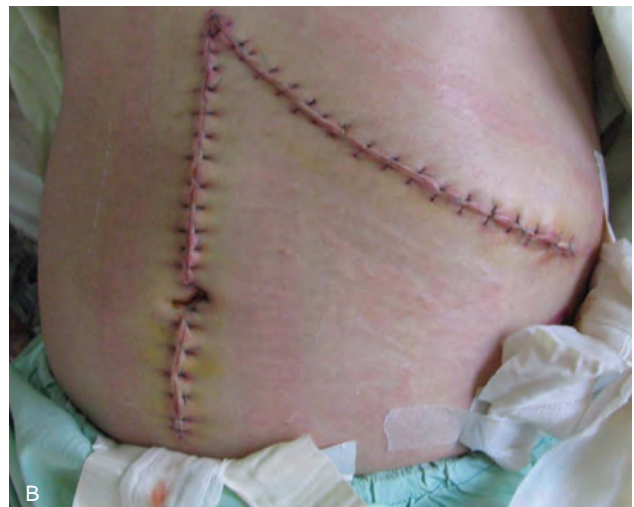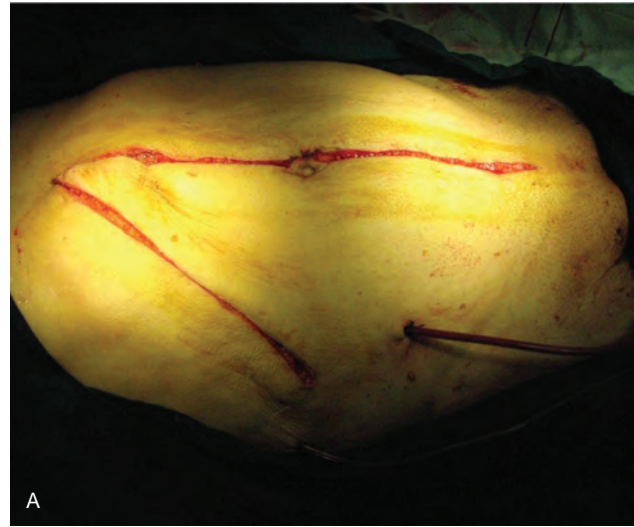


Figure 2. Left subcosto-midline incision (A); Appearance of the site of the right subcosto-midline incision several days after surgery (B); Appearance of the site of left subcosto-midline incision two months after the surgery (C).

intraoperative organs, excellent access to upper pole renal tumors or adrenal masses, and good exposure of the renal vascular pedicle.⁶

The chevron incision is similar to the subcostal incision and is suitable for large renal masses. It also provides very good exposure in cases with involvement of the renal vein and minimal IVC tumor or thrombus extension.⁶

The thoracoabdominal incision is useful in patients with large upper pole renal masses. It provides access to the thoracic cavity and allows hepatic mobilization in renal tumors that involve the IVC. The disadvantages of this approach include the need for chest tube insertion, longer operative time, and increased postoperative pain.⁷

One drawback of all the incisions noted above is that they do not provide adequate exposure in obese patients, those with giant renal masses, and with extensive encasement of the abdominal great vessels or extensive IVC thrombosis, for whom surgery requires prolonged exposure of the aorta or IVC. The subcosto-midline incision is useful in patients who present these challenges, since it offers excellent exposure of the liver and upper left quadrant with suitable access to the lower portions of the aorta and IVC. Obesity and prior abdominal surgery are challenging problems in radical nephrectomy, especially in patients with very large renal masses. Difficult exposure of the renal hilum and inability to mobilize the kidney well may cause injury to vascular or adjacent organs. In our experience the subcosto-midline incision decreases the chances of the complications reported in the literature.

Conclusion

In conclusion, like Sherlock Holmes, who said, “data, data, data”, a surgeon would say, “exposure, exposure, exposure” when faced with a difficult surgery. The subcosto-midline incision or anterior triangular flap incision is a modified abdominal incision, and our experience has shown it to be useful for resecting locally advanced large renal masses. Good exposure is the key to success when we perform challenging operations, since the goal is to increase the patient's chances of complete

tumor resection and to improve survival, which is the ultimate goal of management in patients with huge renal masses.

List of Abbreviations

RCC: Renal cell carcinoma

IVC: Inferior vena cava

Acknowledgements

This work was supported by the Shiraz University of Medical Sciences. We thank K. Shashok (AuthorAID in the Eastern Mediterranean) for improving the use of English in the manuscript, and M. Gholami at the Center for Development of Clinical Research of Nemazee Hospital for research assistance.

References

1. Jemal A, Siegel R, Ward E, Hao Y, Xu J, Murray T, et al. Cancer Statistics, 2008. *CA Cancer J Clin* 2008;58(2):71-96.
2. Ather MH, Masood N, Siddiqui T. Current management of advanced and metastatic renal cell carcinoma. *Urol J* 2010;7(1):1-9.
3. Zisman A, Pontuck AJ, Chao DH, Wieder JA, Dorey F, Said JW, et al. Renal cell carcinoma with tumor thrombosis: Is cytoreductive nephrectomy for advanced disease associated with an increased complication rate? *J Urol* 2002;168(3):962-7.
4. Ljunberg B, Cowan NC, Hanbury DC, Hora M, Kzyk MA, Merseburger AS, et al. EAU pocket guidelines on renal cell carcinoma: The 2012 update. *Eur Urol* 2010;58(3):398-406.
5. Wein AJ, Kavoussi LR, Novick AC, Partin AW, Peters CE. *Campbell-Walsh urology*, 10th ed. Philadelphia: WB Saunders, 2012.
6. Jaan JM, Dela Rosette, Sternberg CN, Hein P, Van Poppel. *Renal Cell Cancer: Diagnosis and Therapy*, 5th ed. London Ltd: Springer, 2008.
7. Graham JR, Kean TE. *Glenn's urologic surgery*, 7th ed. Philadelphia: Lippincott, Williams and Wilkins; 2010.