

Case Report

Middle East Journal of Cancer; October 2014; 5(4): 225-228

Bilateral Ovarian Dermoid Cyst with Bladder Involvement and Hematuria: A Case Report and Literature Review

Mohammad Mehdi Hosseini, Shahrokh Jahanbini, Sara Pakbaz, Shahryar Zeighami*

Nephrology-Urology Research Center, Shiraz University of Medical Sciences, Shiraz, Iran

Abstract

Bilateral ovarian dermoid tumor with invasion to surrounding organ is a rare entity. We report the case of a 63-year-old woman with prolonged dysuria and hematuria who had bilateral ovarian dermoid cysts with urinary bladder involvement.

Keywords: Ovarian tumor, Dermoid, Hematuria

Introduction

Mature ovarian dermoid cysts are the most common benign ovarian neoplasms which comprise approximately 10% to 25% of all ovarian neoplasms. Of these, about 1% to 3% may become malignant and occur most often in women older than 40 years of age. Squamous cell carcinoma, the most common, is observed in approximately 80% of cases. In 10% of cases dermoid cysts are bilateral.¹ They are usually asymptomatic unless torsion, infection or rupture develop.

In rare conditions the cyst may involve surrounding organs such as the colon, rectum or urinary bladder.

Case Report

A 63-year-old multiparous, postmenopausal woman presented

with dysuria and intermittent gross hematuria for six months. On physical examination she had only mild suprapubic tenderness. Routine hematological investigations were normal, however urine analysis revealed microscopic hematuria and pyuria. Ultrasound examination revealed a right ovarian cyst and sessile mass in the left posterior wall of the urinary bladder. A cystoscopy was performed and it was determined that the mass protruded into the bladder lumen on the posterior wall with congested mucosa and a smooth surface. The patient underwent a transurethral resection of the left bladder wall mass but after resection of superficial layer, hair and creamy discharge drained from the tumor bed. The procedure was stopped and a urethral catheter inserted for additional

*Corresponding Author:
Shahryar Zeighami, MD
Urology Office, Faghihi
Hospital, Zand Blvd., Shiraz,
Iran
Tel: +98 711 2331006
Fax: +98 711 2330724
Email: zeyghamishahryar@yahoo.com

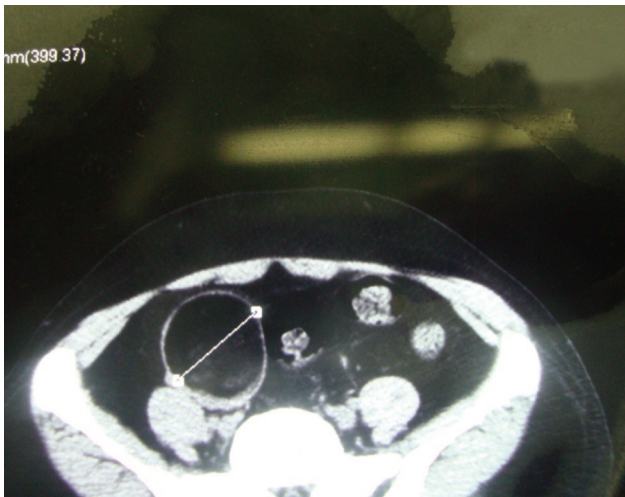


Figure 1. Pelvic CT scan showing the right ovarian cyst marked on the left side and remnant of the resected left ovarian cyst (right side).

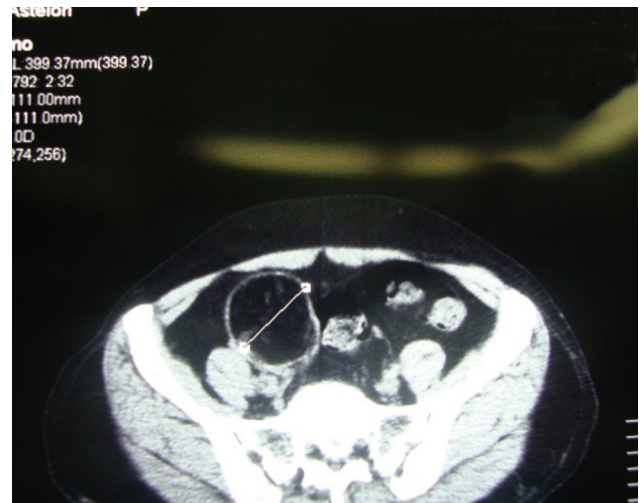

Figure 2. Pelvic CT scan showing more prominent view of the remnant of the left cyst.

evaluation.

Abdominal and pelvic CT scans revealed a 5×6 cm cystic mass in the right ovary. The left ovary showed a remnant of the partially resected cyst, which was located between the bladder dome and uterus (Figures 1 and 2).

The patient underwent a laparotomy which showed that the right ovary was cystic, about 5×7 cm, with no adhesion to the surrounding organs. However the left side was 2×3 cm with a single twist over the infundibulopelvic ligament and located between the bladder and uterus. The cyst infiltrated into the bladder wall with loose adhesion to the uterus. Both ovaries were resected with 1 cm of the

bladder wall at the adhesion site of the left ovary. The patient had an uneventful hospital course, improved urinary symptoms, and was subsequently discharged in good condition. Histopathologic examination revealed a bilateral benign cystic ovarian teratoma with a mature component (Figures 3-5).

Discussion

Ovarian teratoma is a germ cell ovarian neoplasm that may contain all three germ layers, the ectoderm, mesoderm and endoderm.² It usually is filled with sebaceous secretion, hair and occasional nodular tissue that may transform into teeth, bone, cartilage,

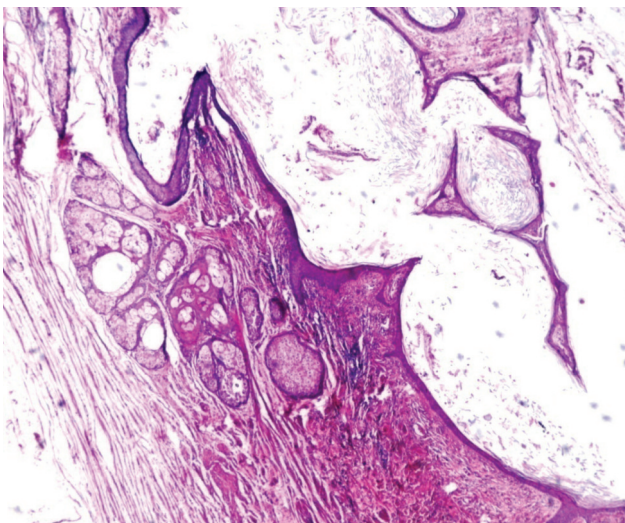


Figure 3. Mature teratoma. Cystic space filled with keratin material and lined by stratified squamous epithelium with some sebaceous tissue in the wall (H&E; 40×).

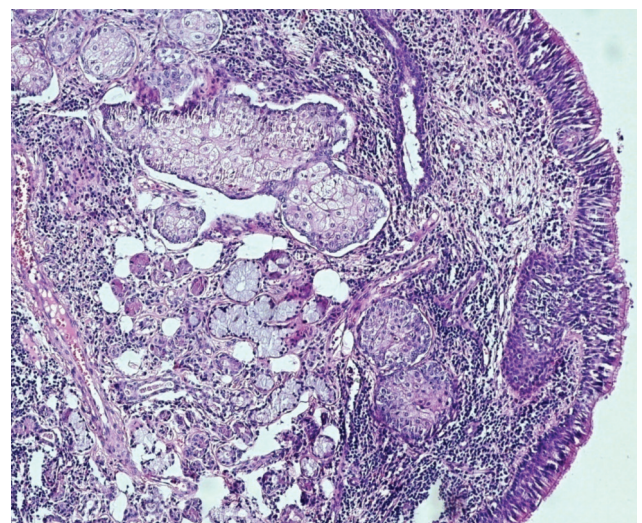


Figure 4. Mature teratoma. Respiratory epithelium with underlying sebaceous tissue and a number of different types of glands (H&E; 200×).

bronchial and gastrointestinal epithelium.³ The teratoma is a spectrum of tumors from immature to mature teratoma with different behavior from malignant to benign. Ultrasonography and computerized tomography scan are two valuable modality for diagnosis of teratoma.⁴ Torsion is the most reported complication of the dermoid cyst, where approximately 1% to 3% develop malignancy. Risk factors include age over 45 years and tumor size larger than 9.9 cm, which has 86% sensitivity for malignancy.⁵

Tekwavi Deepa et al. have reported the case of a 40-year-old woman with a solid cystic ovarian teratoma that had squamous cell carcinoma arising from the teratoma which involved the urinary bladder, uterus, and other adjacent organs.⁶ According to Chong et al., an 80-year-old woman had a large abdominal gas-filled squamous cell carcinoma mass which arose from a mature cystic teratoma of the ovary that communicated to the sigmoid colon.⁷ Presentation of benign cystic ovarian teratoma with fistula to adjacent organs is a rare condition; the most common presentation is into the urinary bladder. Landmann has also reported a benign ovarian teratoma that fistulated to the rectum which presented with rectal bleeding and a polypoid mass in the rectum.⁸ Khanna et al. reported the case of an 18-year-old woman who had a left teratoma that ruptured into the sigmoid colon⁹ and a 39-year-old woman with lower abdominal pain and hematochezia which, upon evaluation, had a mass in the anterior rectal wall from a benign cystic teratoma in her left ovary.¹⁰ Invasion into the urinary bladder is a rare entity. Rantomalala et al. discussed a case that had a right ovarian dermoid cyst which fistulated to the bladder who presented with recurrent urinary infection¹¹ and Tandon et al. presented the case of a 30-year-old woman with urethral discharge after laparotomy. Invasion of ovarian tumor to bladder was detected. Pathologic evaluation confirmed the presence of a benign cystic teratoma.¹² The current case had a bilateral ovarian cystic teratoma with invasion of the left side into the bladder. She presented with dysuria and episodes of gross hematuria for six months duration.

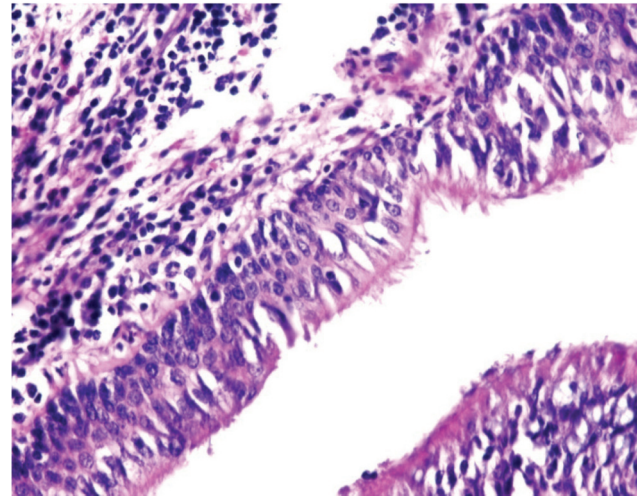


Figure 5. Mature teratoma. Cystic space lined by ciliated pseudostratified columnar epithelium characteristic of the respiratory system (H&E; 400×).

Conclusion

Ovarian dermoid cysts are common ovarian tumors that have an indolent course which may become symptomatic due to complications such as torsion, hemorrhage, infection, and malignant change. Rare fistula to adjacent organs may be present. Spontaneous rupture of a teratoma due to wall thickness is a rare event and usually presents with an acute abdomen. Rupture into a hollow viscous such as the bladder is extremely rare, however in a female patient with chronic urinary symptoms the physician must be aware of this condition.

Conflict of Interest

No conflict of interest is declared.

Reference

1. Katsube Y, Berg JW, Silverberg SG. Epidemiologic pathology of ovarian tumors: a histopathologic review of primary ovarian neoplasms diagnosed in the Denver Standard Metropolitan Statistical Area, 1 July-31 December 1969 and 1 July-31 December 1979. *Int J Gynecol Pathol.* 1982;1(1):3-16.
2. Heinsman AB, Hoffman BL. Pelvic mass. In: Hoffman BL, Schorge Jo, Schaffer JI, et al (eds). *Williams gynecology.* 2nd ed. McGraw-Hill: Texas, 2012:246-75.
3. MontagA , Kumar V. The female genital system and breast. In: Kumar V, Abba AK, Fouston (eds). *Robbins basic pathology.* 8th ed. Saunders: Philadelphia 2007:711-51.
4. Patel MD, Feldstein VA, Lipson SD, Chen DC, Filly RA.

- Cystic teratomas of the ovary: diagnostic value of sonography. *AJR Am J Roentgenol.* 1998;171(4):1061-5.
5. Kikkawa F, Nawa A, Tamakoshi K, Ishikawa H, Kuzuya K, Suganuma N, et al. Diagnosis of squamous cell carcinoma arising from mature cystic teratoma of the ovary. *Cancer.* 1998; 82(11):2249-55.
 6. Tekwavi Deepa T, Joshi Sneha R, Kukrimti Manjiri M. Malignant transformation in an ovarian mature cystic teratoma: A Case Report. *Indian Journal of Basic & Applied Medical Research.* 2012;5(2):432-5.
 7. Chong HMD, Lee FYJ, Lo A, Li CMJ. A giant gas-filled abdominal mass in an elderly female: A case report. *World J Gastroenterol.* 2011;17(31):3659-69.
 8. Landmann DD, Lewis RW. Benign cystic ovarian teratoma with colorectal involvement. Report of a case and review of the literature. *Dis Colon Rectum.* 1988; 31(10):808-13.
 9. Khanna S, Srivastava V, Saroj S, Mishra SP, Gupta SK. An unusual presentation of ovarian teratoma: a case report. *Case Rep Emerg Med.* 2012; 2012: 845-198.
 10. Wickremasinghe D, Samarasekera DN. A benign teratoma of the ovary fistulating into the rectum. *Ceylon Med J.* 2010; 55(4):133.
 11. Rantomalala HY, Raveloson JR, Rakotoarisoa B, Rabesata JO, Tovone XG. Bladder fistula of an ovarian dermoid cyst. *Ann Urol (Paris).* 2003;37(3):102-4.
 12. Tandon A, Gulleria K, Gupta S, Goel S, Bhargava SK, Vaid NB. Mature ovarian dermoid cyst invading the urinary bladder. *Ultrasound Obstet Gynecol.* 2010;35(6):751-3.