

Epididymal Inflammatory Pseudotumor: A Case Report

Mehdi Salehipour**†, Akbar Safaei**, Hamid Arasteh*, Pooya Hekmati*

*Department of Urology, Shahid Faghihi Hospital, Shiraz University of Medical Sciences, Shiraz, Iran

**Department of Pathology, Shahid Faghihi Hospital, Shiraz University of Medical Sciences, Shiraz, Iran

Abstract:

Inflammatory pseudotumor refers to a group of benign tumor like lesions that they are composed of a mixed inflammatory infiltrates. The diagnosis of these lesions and differentiation of them from malignant process may be difficult. We report on a 35-year-old man who presented with multiple painless palpable masses in his right hemiscrotum for about 6 months. Right epididymal involvement with intact testicle and spermatic cord were observed during scrotal exploration. After classic right epididymectomy, histopathologic studies revealed inflammatory pseudotumor of the right epididymis. No remarkable abnormal signs and symptoms were observed in the follow up visits after 8 months.

Keywords: Inflammatory pseudotumor, Inflammatory myofibroblastic tumor, Epididymis

Introduction

Scrotal masses can be generally classified as either malignant or benign. These masses are divided into testicular or paratesticular, according to their origin. The majority of testicular masses are malignant, however most epididymal masses are benign. In some instances differentiation between malignant and benign masses may be difficult. Herein we report a case of inflammatory pseudotumor (IPT) of the epididymis. Inflammatory pseudotumor is defined as a group of benign tumor-like lesions composed of a mixture of inflammatory

infiltrates such as plasma cells, eosinophils, neutrophils and histiocytes. They are non-capsulated, well-defined lesions that occur in various sites of the body, but are most commonly observed in the lungs.

Case Report

A 35-year-old man referred with multiple painless palpable masses in the right hemiscrotum, since 6 months ago. The patient has no history of fever, trauma, urethral discharge, or urinary tract infection. He had 3 children (two boys and one girl) and had no plan for further fertility. We counseled with him about

†Corresponding Author:

Mehdi Salehipour, MD
Associate Professor of Urology
Department of Urology, Shahid
Faghihi Hospital, Zand Ave.,
Shiraz, Iran
Tel: +987112330724
Fax: +987116474307
Email: salehipour@sums.ac.ir

possibility of orchiectomy versus epididymectomy and reduction in his further fertility. Also orchiectomy consent was taken. Familial and past medical history for tumor and tuberculosis were negative. Physical examination revealed multiple nontender, firm masses involving the right epididymis, but the right testis was intact. Physical examination of the left hemiscrotum was normal. Complete blood count, blood chemistries, urinalysis and urine culture were normal. Urine for acid-fast bacilli was negative. Serum betahuman chorionic gonadotropin (β -HCG), alpha-fetoprotein (AFP) and lactate dehydrogenase (LDH) were within normal range. Scrotal sonography demonstrated multiple hypoechoic oval shaped masses in the right epididymis and moderate hydrocele in the right hemiscrotum. Both testes were normal.

Because of uncertain etiology, scrotal exploration was done which revealed, multiple firm nodules in the right epididymis (Figure 1).

Therefore, right classic epididymectomy was performed. The patient has uneventful post-operative hospital course and no evidence of recurrence after 8 months of follow up.

Histopathology examination demonstrated polymorphic infiltration of the cells that were composed of spindle cells arranged in a vaguely fascicular fashion, in addition to plasma cells, lymphocytes and other inflammatory cells (Figure 2).

Immunohistochemistry was strongly positive for vimentin (Figure 3) and negative for cytokeratin. CD3 and CD20 stains showed a normal mixture and distribution of T and B cell lymphocytes. Kappa and lambda light chain stains showed a polyclonal plasma cell population. No cellular atypia was found and very rare mitoses were observed.

Discussion

Inflammatory pseudotumor is a rare, but well-described entity that can involve any organ in the body. This pseudotumor has other synonyms such as inflammatory myofibroblastic tumor, atypical myofibroblastic tumor, plasma cell granuloma, and pseudosarcomatous myofibroblastic proliferation.^{1,2}

The most common sites that they are involved by IPT are lung and orbital cavity but it has also described in other organs.³ In genitourinary tract it most frequently involves urinary bladder and prostate, and the epididymis is the least common one.⁴ Up to now, only 9 cases of epididymal IPT have been reported in literature.²

The pathophysiology of IPT is still unknown, various etiologies have been proposed including infection, chromosomal abnormality, auto immune mechanism, trauma and over expression of different cytokines like interleukin 1 and 6.^{1, 2, 4}

Epstein-Barr virus (EBV), *Mycobacterium avium-intracellulare* and Herpes virus type 8 are among possible infectious causes of IPT.² Chan et al. have shown the role of EBV in two cases of epididymal IPT.⁵

Because of cytogenic clonality, the recurrent involvement of chromosomal region 2P23, occasional aggressive behavior and metastatic potential of IPT, some recent studies have proposed that IPT may be a neoplasm.⁶

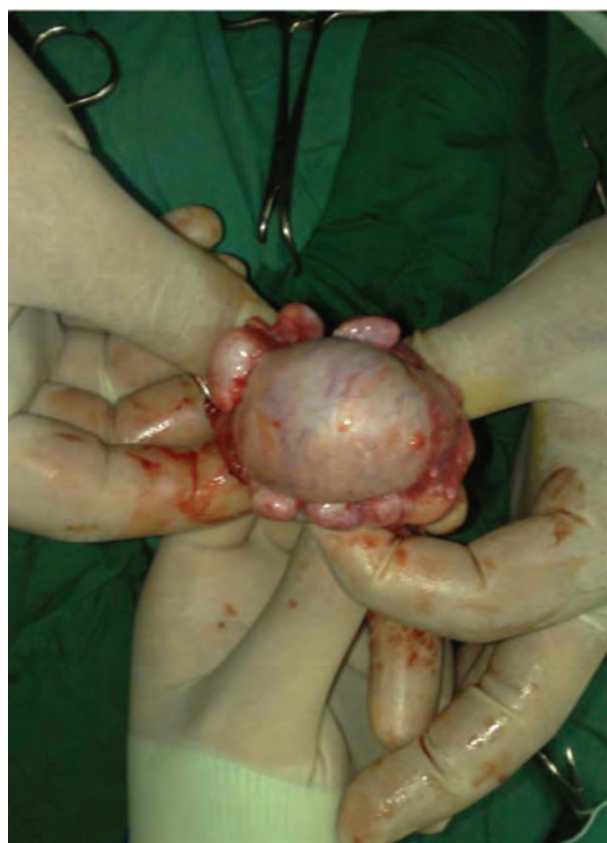

Figure 1. Multiple variable size oval shape nodules in the right epididymis.

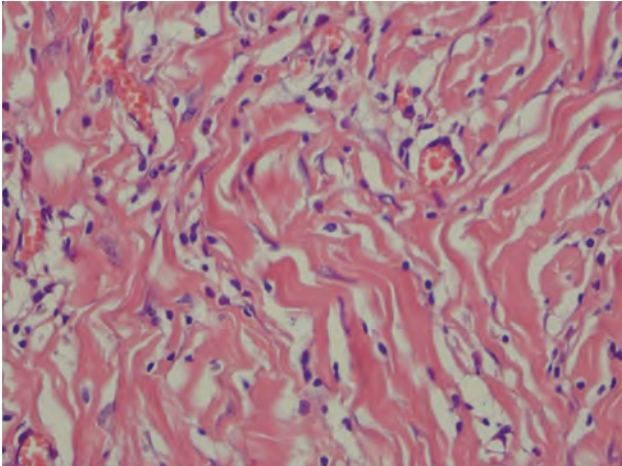


Figure 2. Proliferation of spindle cells and infiltration of mononuclear inflammatory cells.

Histologically, IPT is characterized by the presence of spindle myofibroblastic cells with lymphocytes and plasma cell infiltration. On immunohistochemistry, IPT is usually positive for vimentin, smooth muscle actin and desmin. It has been reported that approximately 50% of IPT are positive for anaplastic lymphoma kinase.^{2, 3, 6}

Patients with IPT may present with systemic symptoms of fever, night sweats, weight loss, and malaise and elevated acute-phase-reactants (i.e., high ESR and CRP, leukocytosis). However those patients with epididymal IPT rarely present with systemic symptoms.⁷ The most common manifestation of epididymal IPT is a painless palpable mass that is frequently indistinguishable from other scrotal masses, including testicular malignancy.^{2, 4, 8}

Surgical excision is the preferred treatment for the majority of genitourinary tract IPTs. Epididymectomy is the modality of choice in cases of a solid epididymal mass, including IPT. However, it might be impossible to perform local excision due to the difficulty in differentiating the mass from the testis; orchiectomy may be necessary in some patients. In conclusion, IPT of the epididymis should be considered in the differential diagnosis of a solid epididymal mass. Since they can mimic malignant tumors, both clinically and radiographically, surgical excision is required to establish a diagnosis.

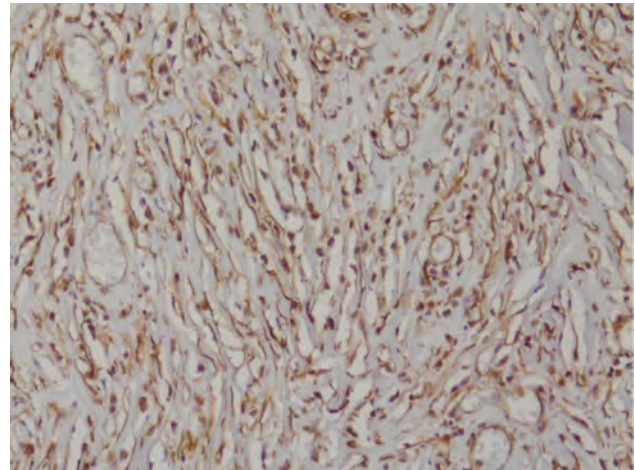


Figure 3. Positive immunohistochemistry for vimentin.

References

1. Das Narla LD, Newman B, Spottswood SS, Narla S, Kolli R. Inflammatory pseudotumor. *Radiographics* 2003;23(3):719-29.
2. Tunuguntla H, Mishra A, Jorda M, Gosalbez R. Inflammatory myofibroblastic tumor of the epididymis: Case report and review of the literature. *Urolog* 2011;78(1):183-5.
3. Park SB, Cho KS, Kim JK, Lee JH, Jeong AK, Kwon WJ, et al. Inflammatory pseudotumor (myofibroblastic tumor) of the genitourinary tract. *AJR* 2008;191(4):1255-62.
4. Dangle PP, Wang WP, Pohar K. Inflammatory myofibroblastic tumor of epididymis: A case report and review of literature. *World J Surg Oncol* 2008;6:119.
5. Chan KW, Chan KL, Lam KY. Inflammatory pseudotumor of the epididymis and Epstein-Barr virus: A study of two cases. *Pathology* 1997; 29(1):100-1.
6. Attili SVS, Chandra CR, Hemant DK, Bapsy PP, Rama Rao C, Anupama G. Retroperitoneal inflammatory myofibroblastic tumor. *World J Surg Oncol* 2005;3:66.
7. Coffin CM, Watterson J, Priest JR, Dehner LP. Extrapulmonary inflammatory myofibroblastic tumor (inflammatory pseudotumor). A clinicopathologic and immunohistochemical study of 84 cases. *Am J Surg Pathol* 1995;19(8):859-72.
8. Lam KY, Chan KW, Ho MHM. Inflammatory pseudotumor of the epididymis. *Br J Urol* 1995; 75(2):255-7.