

Stereotactic Body Radiotherapy in Bulky Hepatocellular Carcinoma with or without Portal Vein Thrombosis: A Feasibility Review in an Egyptian Cohort

Mohamed Wahba Hegazy^{*†}, MD, Hany Attallah^{**}, MD, Khaled M. El-Shahat^{***}, MD, Emad Mostafa^{****}, PhD, Adel Yassin^{***}, PhD, Ibraheem Haggag^{****}, PhD, Talaat Fathy^{*****}, MD, Sameh M. Abdel Monem^{*****}, MD, Ahmed Abdelmoaty^{*****}, MD, Ahmed A. Bessar^{*****}, MD

^{*}Department of Clinical Oncology and Nuclear Medicine, Medicine College, Zagazig, Egypt

^{**}Department of Radiation Oncology, International Medical Center (IMC), Cairo, Egypt

^{***}Department of Clinical Oncology, Al-Azhar College of Medicine, Cairo, Egypt

^{****}Medical Radiation Physics, International Medical Center, Cairo, Egypt

^{*****}Tropica Department, College of Medicine, Zagazig, Egypt

^{*****}Radiology Department, College of Medicine, Zagazig, Egypt

Please cite this article as: Hegazy MW, Attallah H, El-Shahat KM, Mostafa E, Yassin A, Haggag I, et al. Stereotactic body radiotherapy in bulky hepatocellular carcinoma with or without portal vein thrombosis: A feasibility review in an Egyptian cohort. Middle East J Cancer. 2024;15(3):242-48. doi:10.30476/mejc.2023.98866.1918.

Abstract

Background: Hepatocellular carcinoma (HCC) complicated by portal vein thrombosis presents significant clinical challenges. This study aims to retrospectively assess the feasibility of stereotactic irradiation for treating bulky HCC, with or without vascular invasion.

Method: In this retrospective analysis, the radiotherapy treatment plans and clinical follow-up data of 22 patients diagnosed with HCC, with or without portal vein thrombosis, were reviewed. These patients underwent stereotactic body radiation therapy (SBRT) between September 2019 and September 2022. Treatment involved administering 40-50 Gy in 5 fractions using SBRT with volumetric modulated arc therapy (VMAT)/4D-computed tomography. Descriptive statistics were utilized without the application of statistical tests.

Results: The mean age of the patients was 65 years, with 77% being male. Portal vein thrombosis was present in 73% of the cases, and the average tumor size was 7.2 cm (range 5-12 cm). 59% of patients were classified as Child-Pugh B. The median follow-up duration was 8 months (range 3-36 months). At 3 months, tumor response assessments revealed that 59% of patients had a partial response and 41% had stable disease; by 6 months, 37% achieved complete response, 26% maintained a partial response, and 37% had stable condition. Failure patterns included intrahepatic failure in two patients (at 7 and 9 months) and extrahepatic loss in two others (at 6 and 10 months). Radiation-induced liver disease occurred in two patients at 9- and 11-weeks post-treatment, respectively. Liver cancer-specific mortality was 13.6%, while non-liver cancer-specific mortality stood at 9%. The progression-free survival rate was 82%.

Conclusion: SBRT via VMAT represents a highly cost-effective, non-invasive local therapy with a favorable therapeutic ratio for treating bulky HCC cases, with or without vascular invasion.

Keywords: Stereotactic, Hepatocellular, Portal, Veins, Thrombosis

Corresponding Author:

Mohamed Wahba Hegazy, MD
Department of Clinical
Oncology and Nuclear
Medicine, Medicine College,
Zagazig University, Egypt
Tel: +201090063872
Email: F1501625@gmail.com



Background

Hepatocellular carcinoma (HCC) accounts for 4.7% of all cancers and 8.3% of causes of cancer death worldwide.¹ Conventional or stereotactic irradiation is feasible in most liver tumors regardless of their location.² Localized unresectable cases can be treated by hypofractionated irradiation of different dose schedules.³ Most stereotactic irradiation doses are between 30-50 Gy in 3-5 fractions delivered every other day.⁴

The treatment strategies for such HCC cases, usually decided by a multidisciplinary team, are systemic therapy, the combination of transcatheter arterial chemoembolization (TACE) and irradiation. Stereotactic body radiation therapy (SBRT) can be used alone in some selected patients who are not eligible for local ablative procedures, e.g., HCC with portal vein thrombosis and/or having a bulky HCC (more than 5 cm in maximum diameter).⁵⁻⁷ One of the challenging issues in treating HCC is the background hepatic status represented as the Child-Pough score. Child A and early Child B patients usually tolerate irradiation better than late Child B and Child C.⁸⁻¹⁰

Our aim in this study is to review the pattern of failure as the primary endpoint and toxicity as the secondary endpoint after SBRT. This study represents the first experience in the Middle East region using SBRT in patients with bulky HCC with or without portal vein thrombosis.

Patients and Methods

This retrospective study encompassed 22 patients diagnosed with HCC and referred to the International Medical Center (IMC) in Cairo, Egypt, for irradiation treatment. These patients received treatment between September 2019 and September 2022 using SBRT facilitated by volumetric modulated arc therapy (VMAT) and 4D-computed tomography (CT) scanning. The VMAT treatment was administered using a Varian TrueBeam system equipped with a high-definition multi-leaf collimator in conjunction with Varian's Eclipse Treatment Planning System, version 15.6. The treatment plans incorporated partial multiple arcs to optimize dose distribution.

Eligibility criteria

1. Diagnosis of HCC confirmed through one or more standard methods: triphasic CT scan, dynamic magnetic resonance imaging (MRI), elevated alpha fetoprotein (AFP) levels exceeding 400 ng/ml, or image-guided biopsy.
2. Patients classified as Child-Pugh A and early Child-Pugh B, with a score up to 8.
3. Performance status ranging from 0 to 2.
4. Tumor size between 5 and 12 cm, with or without vascular invasion.
5. Age range of 18 to 75 years.
6. Informed consent was obtained from all patients' post-explanation of radiotherapy (RT) details.
7. Non-metastatic HCC cases are confirmed

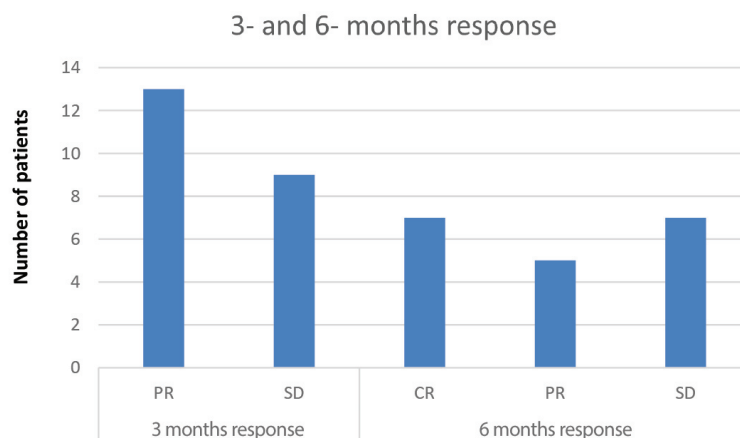


Figure 1. This figure illustrates the treatment outcomes at 3 months post-SBRT, with 13 patients achieving a PR and 9 patients experiencing SD. 6 months post-SBRT, 7 patients achieved a CR, 5 had a PR, and 7 maintained SD.

PR: Partial response; SD: Stable disease; CR: Complete response; SBRT: Stereotactic body radiation therapy

through bone scans, whole-body CT, and/or positron emission tomography (PET)/CT scans.

Exclusion criteria

1. Patients with metastatic HCC.
2. Presence of multifocal HCC or extrahepatic nodal disease.
3. Prior history of liver irradiation.
4. Any single HCC lesion exceeding 12 cm.
5. Local invasions of surrounding organs, such as the small or large intestines and stomach.

Previous systemic or local therapy

Three patients had undergone previous therapies before SBRT: one received Lenvatinib, another Sorafenib, and the third had undergone TACE.

Simulation

A multi-slice CT scan was performed for the simulation with oral and intravenous contrast. Patients were positioned supine, and images were captured in 2.5 mm slices from the mid-chest to the iliac crest. Immobilization was achieved using knee-foot support devices, with arms positioned outside the field. Patients were instructed to maintain an empty bowel during the CT simulation and each treatment session. Pretreatment imaging, including triphasic CT with contrast, magnetic resonance imaging (MRI), and/or PET/CT scans, was fused with the 4D-CT scan for comprehensive assessment.

Table 1. Dosimetric constraints for HCC

Target	Dose constraints
PTV95	100% ± 5
Mean liver-GTV	<14 Gy or ALAP
Stomach Dmax	<35 Gy
Bowel Dmax	<35 Gy
Spinal cord Dmax	<30 Gy
Esophagus Dmax	<34 Gy
Chest wall Dmax	<39 Gy
Kidney mean	< 10 Gy
Lungs V20	10%
Heart Dmax	<29 Gy

ALAP: As low as possible; Dmax: Maximum point dose; V20: Volume receiving 20Gy; PTV95: Planning target volume receiving 95% of target dose; GTV: Gross target volume; HCC: Hepatocellular carcinoma

Planning and dose parameters

The gross target volume (GTV) was delineated based on primary imaging data. The internal target volume included the GTV, augmented by a 2-5 mm radial margin, while carefully avoiding critical structures. The planning target volume (PTV) was defined by adding an anisotropic 5 mm margin to the internal target volume. Contouring of organs at risk was conducted following the Radiation Therapy Oncology Group (RTOG) guidelines. Treatment involved administering 40-50 Gy in 5 fractions, delivered every other day, and each session utilized 4D-cone beam CT (CBCT) for verification. The dose constraints for organs at risk and PTV are detailed in table 1.

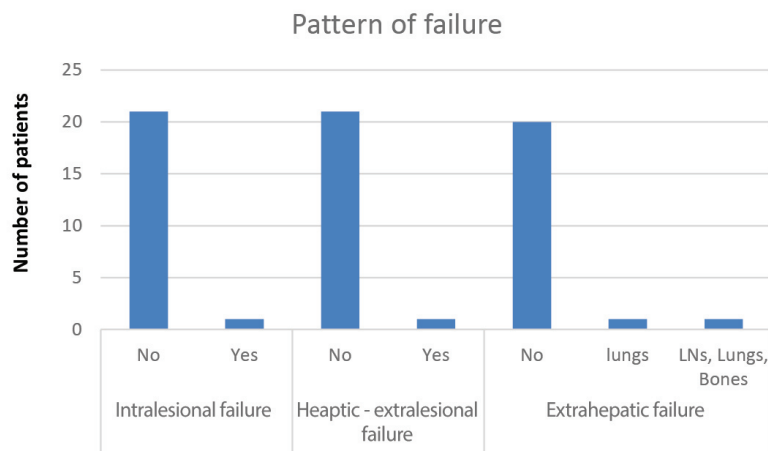


Figure 2. This figure highlights various failure patterns following treatment. One patient experienced hepatic intralesional failure at 7 months post-SBRT, while another patient suffered hepatic extralesional loss at 9 months post-treatment. Additionally, there was one case of extrahepatic failure with diffuse metastasis at 6 months post-treatment and one case of extrahepatic failure with pulmonary metastasis at 10 months post-treatment.

LNs: Lymph nodes; SBRT: Stereotactic body radiation therapy

Table 2. Patients' characteristics and disease criteria

Age in years, mean, range		65 (48-74)	
Sex (no)			
Male		17	77%
Female		5	23%
CT findings			
Not consistent		2	9%
Consistent		20	91%
PVT			
No		6	27%
Yes		16	73%
Pathology proven			
No		20	91%
Yes			29%
AFP level ng/mL	4488 (4-35000)		
Child-Pough score, mean, range	7 (5-8)		
Tumor size (cm), mean, range	7.2 (5-12)		
GTV volume (ml), mean, range	154 (25-990)		
Liver-GTV volume (ml), mean, range	1565 (720-2340)		
GTV/ mean liver dose %, mean, range	10% (2-42)		

PTV: Planning target volume; GTV: Gross target volume; PVT: Portal vein thrombosis; CT: Computed tomography; AFP: Alpha fetoprotein

Follow-up visits

Patients underwent weekly evaluations during RT treatment. Acute toxicities encompassed events occurring during and within 90 days post-RT, and late toxicities, those occurring beyond 90 days post-RT, were documented according to the Common Toxicity Criteria for adverse events, version 4. Post-RT follow-up visits were scheduled every 3 months during the initial 2 years, followed by subsequent intervals of every 4-6 months over the next 3 years. These visits included comprehensive assessments, including blood tests, triphasic CT or MRI scans, and/or whole-body PET/CT scans. Response evaluation was conducted using a combined set of criteria, with complete response defined as the disappearance of lesions or total necrosis, irrespective of size or the presence of non-enhancing residual cavities. Partial response was described as a reduction in lesion size by more than 30% without total necrosis or lobulated enhancement, while stable disease referred to cases that did not meet the criteria for partial response or progressive disease. Progressive disease was defined as a 20% increase in lesion size or the presence of lobulated enhancement.

Ethical considerations

This review received approval from the International Medical Center Committee (Egypt

Center of Research and Regenerative Medicine [E.C.R.R.M] under the Ministry of Defense) with IRB00012517 and Decision number 2/01-2023, granted on 30/1/2023; and adhered to the ethical standards established in the 1964 Declaration of Helsinki. All individuals provided informed consent before undergoing therapy.

Statistical analysis

All data were collected, tabulated, and subjected to statistical analysis using Microsoft Office Excel 2010 for Windows (Microsoft Corporation, Redmond, WA, USA) and SPSS 22.0 for Windows (IBM Inc., Chicago, IL, USA). Continuous quantitative variables were expressed as the mean \pm standard deviation (SD) and median (range), while categorical qualitative variables were presented as absolute frequencies (number) and relative frequencies (percentage).

Results

Patient characteristics

Tables 2 and 3 display the details of all patients. At a median follow-up duration of 8 months (3 to 36 months), the mean age was 65 years (ranging from 48 to 74). Among the patients, 77% were male, and 73% exhibited vascular invasion. The mean tumor size measured 7.2 cm (ranging from 5 to 12 cm), with a mean tumor volume of 154 ml (ranging from 25 to 990 ml). Child B status

Table 3. GTV metrics, maximum tumor diameter, and dose parameters for GTV and PTV

		Maximum diameter (cm)	GTV volume (cc)
		Mean	Mean
GTV Dose/5 fractions	40 Gy	6.0	80
	45 Gy	12.8	111
	50 Gy	7.2	219
PTV Dose/5 fractions	35 Gy	6.8	97
	40 Gy	6.0	70
	45 Gy	18.5	111
	50 Gy	8.2	340

PTV: Planning target volume; GTV: Gross target volume

was observed in 59% of patients, and one patient presented with biopsy-proven advanced laryngeal cancer and HCC. The mean radiation dose was 47 Gy (40 to 50 Gy). Notably, the target dose did not influence tumor response, as only one out of 22 patients experienced intralesional failure within the treatment field.

At the 3-month follow-up, 13 patients (59%) exhibited partial response, while 9 (41%) maintained stable disease. At the 6-month follow-up, 7 patients (37%) achieved complete response, 5 (26%) showed partial response, and 7 (37%) retained stable disease, as depicted in figure 1.

Pattern of failure and survival

Concerning hepatic failure, one patient experienced intralesional failure at 7 months, while another patient encountered extralesional failure at 9 months. In terms of extrahepatic loss, one patient developed diffuse metastasis at 6 months, while another patient had pulmonary metastasis at 10 months, as illustrated in figure 2.

Three patients succumbed at 7 months due to liver cell failure, with two of them developing radiation-induced liver disease (RILD). Another patient passed away at 7 months due to the coronavirus disease of 2019 (COVID-19), and a fifth patient expired at 19 months due to widespread laryngeal cancer. The mortality specific to liver cancer was 13.6%, while non-liver cancer-related mortality stood at 9%. Progression-free survival (PFS) was calculated at 82%.

Toxicity

All patients tolerated the course of RT well, with acute toxicity predominantly rated at grades 1 and 2. However, RILD was recorded in two patients at 9 and 11 weeks post-RT, primarily

attributable to their initial Child B score of 8. Late toxicity manifested as a mild to moderate increase in liver enzymes in 3 patients (13.6%) but exhibited rapid recovery. No grade 3 or 4 late toxicities were observed during follow-up. Furthermore, no acute or late toxicities related to the heart, lungs, or kidneys were documented, as presented in table 4.

Discussion

When we started treating this cohort, we kept in mind that the majority of cases would have vascular invasion (73%), big tumor size (5-12cm), and impaired liver functions (59% of Child B), so after literature review about such cases treated by SBRT and previous practice extrapolation; we modify the practice by different points; firstly to deliver target dose as high as possible every other day in 5 fractions, secondly to paint the target volume dose (2-3 dose levels inside the target volume like 35, 40, 45 or 50Gy), so we can deliver amounts >35Gy to targets near gastrointestinal (GI) tract or > 40Gy to targets near chest wall and lastly consumption of more than usual time in planning to keep the mean liver dose -GTV as low as possible and sometimes ≤5Gy in lesions 8-10cm diameter.

Regarding to SBRT toxicity of such bulky cases; this series of such frail challenging patient's characteristics recorded RILD in 2 patients (9%) post 9 and 11 weeks of therapy similar to Bujold et al.,⁶ who reported RILD in 7 patients (7%) [102 patients; all Child-A, median diameter was 7.2 cm and 55% with vascular invasion], Que et al.,¹¹ series who recorded 8 patients (7%) [115 patients; Child A in 90%, vascular invasion in 30% and tumor size between 4-9cm in 41%], and

Table 4. Evaluation of acute and late liver SBRT toxicity

	Acute toxicity		Late toxicity	
	G1	G2	G1	G2
Esophagitis	4.5%	0	0	0
Gastritis	9%	4.5%	0	0
Pain	4.5%	9%	0	0
Fatigue	27%	0	0	0
Liver enzymes	0	0	4.5%	9%

SBRT: Stereotactic body radiation therapy

Lo et al.,¹² who reported five patients (9.4%) [53 patients and median tumor size 4.3cm], while it was in 14% of Child B cases of series by Lasley et al.¹³ [59 patients; 64% of Child-A, maximum tumor size was 6 cm and 20% had vascular invasion]; also a series by Gkika et al.¹⁴ who treated 47 patients with median tumor diameter 7 cm, median GTV 77 ml with Child-A in 60%, where GI toxicities grade ≤ 2 in 6.4% and RILD in 10.6% of patients; as well as a series by Chopra et al.¹⁵ (21 patients, median tumor size and volume were 9.6 cm and 350 ml), where overall rate of $>$ grade 3 toxicity was 14 %; Contrary to these results, Seo et al.¹⁶ [38 patients, diameter <10 cm, post TACE and median tumor volume 40.5ml] noticed RILD in six patients (16%) and Grade 3 musculoskeletal toxicity in one patient (2.7%); while Beaton et al.¹⁷ [13 patients; median size 7.5 cm and Child A in 69% patients] reported grade 3 acute toxicities in 7 patients, of which six were haematological.

Regarding tumor response 3 months post SBRT, this series recorded 59% had a partial response, and 41% had stable disease, while at 6 months, 37% had a complete response, 26% had a partial response, and 37% had stable condition, similar to Seo et al.,¹⁶ who noted local response rate of 63% at 3 months, while Que et al.¹¹ found that 48.7 % achieved complete response and 40% achieved a partial response with a median follow-up of 15.5 months. Also, Lo et al.¹² recorded 32.8% complete responses with a median follow-up of 13.1 months; however, Bujold et al.⁶ noticed complete response in 11%, partial response in 43%, and stable disease in 44%.

Regarding local control (LC) and pattern of failure, this series had 4.5% intralesional failure at 7 months, 4.5% extralesional failure at 9 months, while extrahepatic failure was 4.5% with

diffuse metastasis at 6 months, and 4.5% with pulmonary metastasis at 10 months; however, Gkiki et al.¹⁴ found that with median 7 months, 7 lesions had intralesional (in-field) failure; two with extralesional, two with distant metastasis and three with both extralesional and distant metastases, also extralesional (out of the field) failure was observed in 3 cases, 16 as out of the area and distant metastasis progression and 10 with only distant metastases; while Que et al.¹¹ noted that at 1 and 2 years in-field recurrence-free survival was 85.3% and 81.6%, while out-field recurrence-free survival were 52.5% and 49.5% different to series by Lo et al.,¹² who recorded extralesional hepatic recurrence in 54% of cases, with 1 and 2-year intralesional failure-free rate was 73.3 and 66.8%.

Regarding survival outcome, the median follow-up of this cohort was 8 months (3-36); the median follow-up of survived patients was 9 months during 7 months in non-survived patients. Liver cancer-specific mortality was 13.6%, while non-liver cancer-specific mortality was 9%. Gkika et al.¹⁴ had a median follow-up of 19 months of alive patients with 1-year LC of 77% and a median overall survival (OS) of 9 months. Bujold et al.⁶ recorded 1-year LC of 87% and OS of 55%, comparable to Lasley et al.,¹³ who recorded 86.5% and 75.5% and Beaton et al.,¹⁷ who reported 92% and 62% with median follow-up of 17.7 months and median OS 17.7 months; however Que et al.,¹¹ noticed 1-year OS of 63.5%, PFS of 42.8 % with median survival 15 months similar to Lo et al.,¹² who caught 1-year OS of 70.1% with 20 months median survival and Chopra et al.,¹⁵ who noted 1-year LC of 88%.

Limitations of this study are its retrospective nature, low sample size, and short-term follow-up period, so a prospective trial should be

warranted.

Conclusion

SBRT via VMAT represents a highly cost-effective, locally non-invasive therapeutic approach with a favorable therapeutic ratio for patients presenting with bulky HCC, irrespective of the presence or absence of vascular invasion.

Conflict of Interest

None declared.

References

- Sung H, Ferlay J, Siegel RL, Laversanne M, Soerjomataram I, Jemal A, et al. Global cancer statistics 2020: GLOBOCAN estimates of incidence and mortality worldwide for 36 cancers in 185 countries. *CA Cancer J Clin*. 2021;71(3):209-49. doi: 10.3322/caac.21660.
- Apisarnthanarax S, Barry A, Cao M, Czito B, DeMatteo R, Drinane M, et al. External beam radiation therapy for primary liver cancers: An ASTRO clinical practice guideline. *Pract Radiat Oncol*. 2022;12(1):28-51. doi: 10.1016/j.prr.2021.09.004.
- Hong TS, Wo JY, Yeap BY, Ben-Josef E, McDonnell EI, Blaszkowsky LS, et al. Multi-institutional phase II study of high-dose hypofractionated proton beam therapy in patients with localized, unresectable hepatocellular carcinoma and intrahepatic cholangiocarcinoma. *J Clin Oncol*. 2016;34(5):460-8. doi: 10.1200/JCO.2015.64.2710.
- Ohri N, Tomé WA, Méndez Romero A, Miften M, Ten Haken RK, Dawson LA, et al. Local control after stereotactic body radiation therapy for liver tumors. *Int J Radiat Oncol Biol Phys*. 2021;110(1):188-95. doi: 10.1016/j.ijrobp.2017.12.288.
- Yoon SM, Ryoo BY, Lee SJ, Kim JH, Shin JH, An JH, et al. Efficacy and safety of transarterial chemoembolization plus external beam radiotherapy vs. sorafenib in hepatocellular carcinoma with macroscopic vascular invasion: a randomized clinical trial. *JAMA Oncol*. 2018;4(5):661-9. doi: 10.1001/jamaoncol.2017.5847.
- Bujold A, Massey CA, Kim JJ, Brierley J, Cho C, Wong RK, et al. Sequential phase I and II trials of stereotactic body radiotherapy for locally advanced hepatocellular carcinoma. *J Clin Oncol*. 2013;31(13):1631-9. doi: 10.1200/JCO.2012.44.1659.
- Tanguturi SK, Wo JY, Zhu AX, Dawson LA, Hong TS. Radiation therapy for liver tumors: ready for inclusion in guidelines? *Oncologist*. 2014;19(8):868-79. doi: 10.1634/theoncologist.2014-0097.
- Velec M, Haddad CR, Craig T, Wang L, Lindsay P, Brierley J, et al. Predictors of liver toxicity following stereotactic body radiation therapy for hepatocellular carcinoma. *Int J Radiat Oncol Biol Phys*. 2017;97(5):939-46. doi: 10.1016/j.ijrobp.2017.01.221.
- Parzen JS, Hartsell W, Chang J, Apisarnthanarax S, Molitoris J, Durci M, et al. Hypofractionated proton beam radiotherapy in patients with unresectable liver tumors: multi-institutional prospective results from the Proton Collaborative Group. *Radiat Oncol*. 2020;15(1):255. doi: 10.1186/s13014-020-01703-3.
- Culleton S, Jiang H, Haddad CR, Kim J, Brierley J, Brade A, et al. Outcomes following definitive stereotactic body radiotherapy for patients with Child-Pugh B or C hepatocellular carcinoma. *Radiother Oncol*. 2014;111(3):412-7. doi: 10.1016/j.radonc.2014.05.002.
- Que J, Kuo HT, Lin LC, Lin KL, Lin CH, Lin YW, et al. Clinical outcomes and prognostic factors of cyberknife stereotactic body radiation therapy for unresectable hepatocellular carcinoma. *BMC Cancer*. 2016; 16:451. doi: 10.1186/s12885-016-2512-x.
- Lo CH, Huang WY, Lee MS, Lin KT, Lin TP, Chang PY, et al. Stereotactic ablative radiotherapy for unresectable hepatocellular carcinoma patients who failed or were unsuitable for transarterial chemoembolization. *Eur J Gastroenterol Hepatol*. 2014;26(3):345-52. doi: 10.1097/MEG.000000000000032.
- Lasley FD, Mannina EM, Johnson CS, Perkins SM, Althouse S, Maluccio M, et al. Treatment variables related to liver toxicity in patients with hepatocellular carcinoma, Child-Pugh class A and B enrolled in a phase 1-2 trial of stereotactic body radiation therapy. *Pract Radiat Oncol*. 2015;5(5):e443-e449. doi: 10.1016/j.prr.2015.02.007.
- Gkika E, Schultheiss M, Bettinger D, Maruschke L, Neeff HP, Schulenburg M, et al. Excellent local control and tolerance profile after stereotactic body radiotherapy of advanced hepatocellular carcinoma. *Radiat Oncol*. 2017;12(1):116. doi: 10.1186/s13014-017-0851-7.
- Chopra S, George K, Engineer R, Rajamanickam K, Nojin S, Joshi K. et al. Stereotactic body radiotherapy for inoperable large hepatocellular cancers: results from a clinical audit. *Br J Radiol*. 2019;92(1101):20181053. doi: 10.1259/bjr.20181053.
- Seo YS, Kim MS, Yoo SY, Cho CK, Choi CW, Kim JH, et al. Preliminary result of stereotactic body radiotherapy as a local salvage treatment for inoperable hepatocellular carcinoma. *J Surg Oncol*. 2010;102(3):209-14. doi: 10.1002/jso.21593.
- Beaton L, Dunne EM, Yeung R, Rackley T, Weber B, Mar C, et al. Stereotactic body radiotherapy for large unresectable hepatocellular carcinomas - a single institution phase II study. *Clin Oncol (R Coll Radiol)*. 2020;32(7):423-32. doi: 10.1016/j.clon.2020.01.028.