

Endocan, ET-1, and ETAR Expression Profiles in Unicystic Ameloblastoma, Multicystic Ameloblastoma, and Ameloblastic Carcinoma

Soussan Irani^{*,***,♦}, Zhaleh Mohsenifar^{***}

**Dental Research Center, Oral Pathology Department, Dental Faculty, Hamadan University of Medical Sciences, Hamadan, Iran*

***Pathology Department, School of Medicine, Griffith University, Gold Coast, Australia*

****Pathology Department, Taleghani Hospital, Shahid Beheshti University of Medical Sciences, Tehran, Iran*

Abstract

Background: Odontogenic lesions range from simple cysts to benign tumors and carcinomas. Unicystic ameloblastoma is a monocystic lesion and a less aggressive tumor compared to multicystic ameloblastoma. Ameloblastic carcinoma is the malignant variant of the multicystic ameloblastoma and may arise de novo or from malignant transformation of a long-standing multicystic ameloblastoma.

Methods: We collected 54 tissue samples obtained from patients from 2000-2017 that were stored in the archives section of the Pathology Department of Taleghani Educational Hospital, Tehran, Iran. The specimens were processed for immunohistochemistry analysis. Immunostaining of the markers was assessed via quantitative methods. Statistical analysis was performed using one-way ANOVA and the chi-square test.

Results: One-way ANOVA analysis and the chi-square test did not reveal any statistically significant differences between the expression levels of endocan, ET-1, and ETAR and lesion type. A positive correlation existed between ET-1 and ETAR expression levels in unicystic ameloblastoma and multicystic ameloblastoma (Pearson's $r = 0.506$, $P < 0.002$), and between ET-1 and ETAR expression levels in unicystic ameloblastoma and ameloblastic carcinoma (Pearson's $r = 0.376$, $P < 0.024$).

Conclusion: This study revealed a positive correlation between the histological degree of lesion and endocan, ET-1, and ETAR expression levels. Hence, it might suggest that multicystic ameloblastoma develops from unicystic ameloblastoma. Over time, multicystic ameloblastoma may undergo a malignant transformation to ameloblastic carcinoma. Possibly, a simple cystic neoplasm can progress to a cystic lesion with invasion to the connective tissue wall and a gradual development into a true neoplasm (multicystic ameloblastoma), with potential for malignant transformation (ameloblastic carcinoma). Endocan, ET-1, and ETAR can be used as prognostic biomarkers for different variants of multicystic ameloblastoma and possible new targets for cancer therapy.

♦Corresponding Author:

Soussan Irani, DDS, OMP, PhD
Dental Faculty, Dental Research Center, Research Center for Molecular Medicine Hamadan University of Medical Sciences, Shahid Fahmideh Street, Postal code: 65178-38741, Hamadan, Iran
Tel: +98813-8354250
Fax: +98813-8354220
Email: sousanirani@gmail.com

Introduction

Odontogenic lesions range from a simple cyst to a benign tumor and even a carcinoma.¹ Unicystic ameloblastoma (UA) is a monocystic lesion with a lining composed of ameloblastic cells. It is a less aggressive tumor compared to the solid/multicystic/conventional type of ameloblastoma. Unicystic ameloblastoma constitutes 5%-15% of all ameloblastomas.² In some cases, one or more nodules project into the lumen of the cyst cavity and may mimic a plexiform ameloblastoma. In addition, a few UAs may have mural nodules or local thickenings of the cyst wall.³ Histologically, UAs present in 3 different patterns: simple cyst or luminal type, intraluminal type, and mural type.⁴ Unicystic ameloblastoma is a less aggressive tumor with a variable recurrence rate.⁵ However, multicystic ameloblastoma (AM) is a benign but locally aggressive odontogenic tumor. It comprises about 1%–3% of all jaw tumors and cysts.⁶ Histologically, AM displays two patterns: follicular and plexiform type⁷ and is composed of a neoplastic odontogenic epithelium with mature fibrous stroma.⁸ Although the etiology of AM is unknown, a growing body of evidence indicates that mutation or molecular alteration is the first event in the development of the tumor; however, the sequence of events is not clear.⁶ According to a previous study, epithelial cells in AM have some stem cell properties; therefore, the tumor maintains stemness by the expression of transcription factor SRY-related HMG-box gene 2 (SOX2), which influences the tumor's biological

behavior.⁹ Researchers have demonstrated an interaction between stem cell properties and tumor-stromal cells in AM by evaluating the expression levels of CD90 and P75NTR.⁹ Ameloblastic carcinoma (AC) is a rare malignant variant of AM that may arise de novo or from malignant transformation of a long-standing AM that has undergone several surgical excisions. Less than 1% of AMs undergo malignant transformation.¹⁰ Ameloblastic carcinoma shows the overall histological patterns of an AM along with cytological atypia that includes abnormal mitotic figures, cellular and nuclear hyperchromatism, and focal necrosis.¹¹ Pathogenesis of AM involves multiple cellular pathways. A better understanding of the pathogenic pathways involved in AM will provide new therapeutic approaches such as molecular targeted treatment.¹²

Endocan, also known as endothelial cell specific molecule-1 (ESM-1), participates in adhesion between cells and the cell matrix because of its homology with the amino acid sequence of adhesion molecules. Endocan is overexpressed in tumor and endothelial cells, and promotes tumor growth.¹³ Thereby, it has prognostic value in breast, renal, and lung cancers.¹⁴ Endocan is a secreted proteoglycan that is upregulated by growth factors and chemokines on tumor vasculature in several types of cancers. However, it plays diverse biologic roles. Its high expression in glioma has a positive correlation with the degree of malignancy;¹⁵ whereas, in pancreatic neuroendocrine tumors, a negative correlation has been found between endocan expression levels

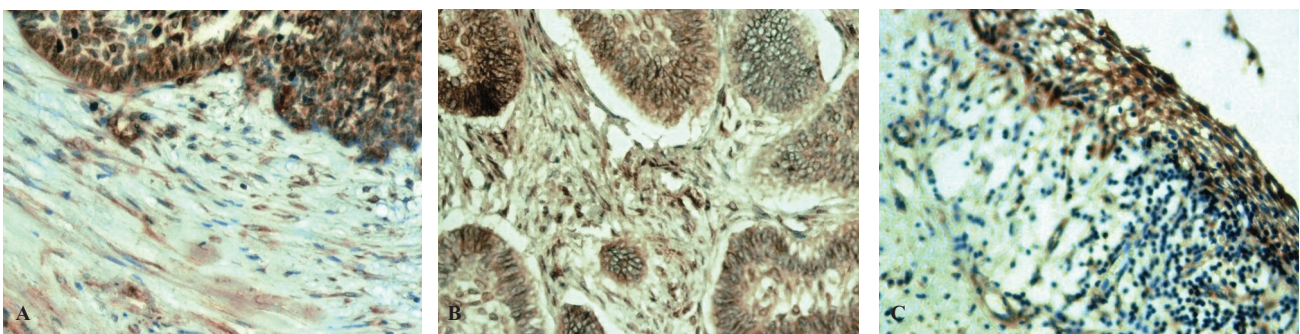


Figure 1. High magnification of immunohistochemical strong expression of endocan in ameloblastic carcinoma (A), multicystic ameloblastoma (B) and unicystic ameloblastomas (C). Notice the stroma staining with endocan (fibroblasts and vascular endothelial cells) near the odontogenic neoplastic nest/cord and cystic epithelial lining.

and prognosis.¹⁶ Endocan expression is regulated by some cytokines and growth factors such as tumor necrosis factor- α , transforming growth factor- β 1, and vascular endothelial growth factor (VEGF).¹⁷ Endocan may be a therapeutic target of chemotherapy to control tumor angiogenesis and tumor growth.¹⁸

Endothelin-1 (ET)-1, a tumor marker, has a mitogenic activity which can be amplified by synergistic interactions with other growth factors such as epidermal growth factor (EGF) and basic fibroblast growth factor (bFGF).¹⁹ Endothelin-1 contributes to tumor growth by enhancing cell adhesion, cell migration, and angiogenesis.^{20,21} Endothelin-1 and its receptors, ETA and ETB, are expressed in higher amounts in papillary thyroid cancer and glioblastoma multiforme.²⁰⁻²² A previous study on head and neck squamous cell carcinoma (HNSCC) has demonstrated activation of the ET axis.²³⁻²⁵ Endothelin-1 stimulates the proliferation of cancer cells through ETAR and ETBR, which are amplified by the presence of oral fibroblasts.²⁶ Endothelin-1 induces the activity of some metastasis related factors such as MMPs and the urokinase-type plasminogen activator (uPA) system via ETAR.²⁷ Cell proliferation plays a critical role in tumor growth and is dysregulated in neoplasms. Therefore, analysis of cell proliferation activity is an important tool to study tumor behaviors.²⁸

Materials and Methods

The Ethics Committee of Hamadan University of Medical Sciences approved this study

(Institutional Review Board approval number res. proj. 9504222160). A total of 54 samples (18 samples for each lesion type) were collected from the archives of the Pathology Department of Taleghani Educational Hospital, Tehran, Iran from 2000-2017. Only the follicular type of AM and luminal type of UA were evaluated in the present study. Hematoxylin and eosin (H&E) staining was performed to confirm the previous diagnosis.

Immunohistochemistry staining

The specimens were processed for immunohistochemistry analysis. Monoclonal anti mouse antibodies used in the immunohistochemistry assay consisted of ESM1 (1:170; Abcam; 56914) and ET-1 (1:170; Abcam; 2786), in addition to polyclonal anti-rabbit ET A receptor antibody (1:170; Abcam; 76259). Briefly, we sliced the paraffin blocks into 4 μ m thick sections. The sections were subsequently deparaffinized and dehydrated in graded alcohol series. Antigen retrieval was performed in citrate buffer (pH 6). We used a Leica detection kit to block endogenous peroxidase activity. After 3 washes in tris-buffered saline (TBS), the samples were incubated with primary antibodies for one hour. Negative controls were prepared by omitting the primary antibody. After TBS washing, the slides were developed in freshly prepared diaminobenzidine solution (DAB) for 6 min, followed by counterstaining with hematoxylin, dehydration, and mounting.

Detection and scoring

We evaluated endocan and ET-1 expression levels in the cytoplasm and ETAR expression in

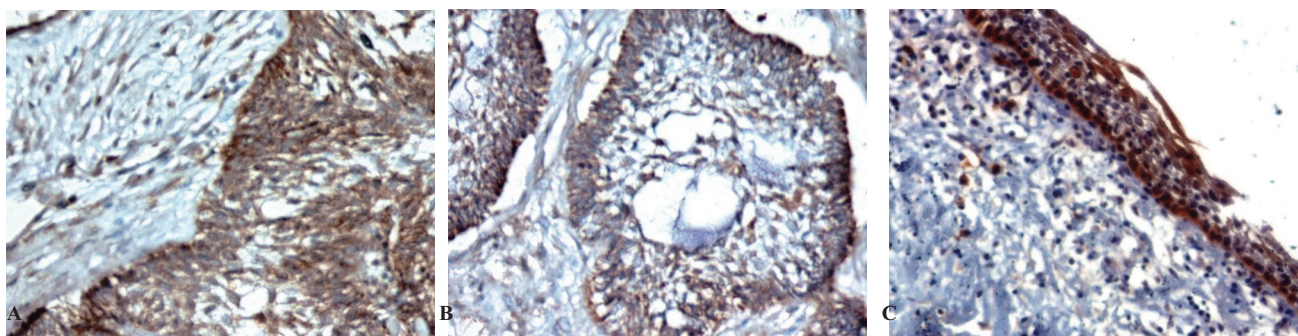


Figure 2. High magnification illustrates a strong cytoplasmic ET-1 expression in ameloblastic carcinoma (A), in multicystic ameloblastoma (B), and in unicystic ameloblastoma (C). Cytoplasmic staining is evident in stellate reticulum cells as well as stroma cells including fibroblasts and vascular endothelial cells.

Table 1. The relationships between Endocan, ET-1 and ETAR expression levels and unicystic ameloblastoma, multicystic ameloblastoma and ameloblastic carcinoma (Chi-square test results).

Biomarker	Unicystic ameloblastoma	Multicystic ameloblastoma	Ameloblastic carcinoma	P-value
Endocan				
Weak and Moderate	11 (61.1 %)	8(44.4 %)	6 (33.3%)	0.243
Strong	7 (38.9%)	10(55.6 %)	12 (66.7%)	
ET-1				
Weak and Moderate	10 (55.6 %)	9(50%)	6 (33.3%)	0.380
Strong	8(44.4 %)	9(50%)	12(66.7%)	
ETAR				
Weak and Moderate	10(55.6 %)	10(55.6%)	7 (38.9 %)	0.594
Strong	8(44.4 %)	8 (44.4%)	11(61.1%)	

the membrane of cells from the tissue samples. We performed quantitative immunostaining of the markers. A total of 5 photomicrographs of each sample were acquired. The percentage of positive cells was expressed as the ratio between the number of positive tumor cells and the total number of tumor cells counted in the high power fields. The abundance of positive cells for the biomarkers was graded as follows: 1 (weak) for <20% positive cells; 2 (moderate) for 20%-50% positive cells; and 3 (strong) for >50% positive cells.²⁹ For all cases, immunostaining was evaluated in the basal cell layer.

Statistical analysis

We used the Statistical Package for Social Sciences software version 22.0 (Chicago, IL, USA) for statistical analysis. Data were also analyzed by one-way ANOVA to determine if a significant difference of endocan, ET-1, and ETAR

expression levels existed between the examined groups. The samples were divided into a weak and moderate expression group (group A) and a strong expression group (group B) in order to perform the chi-square test.

Results

We used 54 samples for the immunohistochemical study. One-way ANOVA and the chi-square test did not reveal any statistically significant differences between expression levels of endocan, ET-1, and ETAR, and lesion type in the studied groups. However, there was a positive correlation between ET-1 and ETAR expression levels in UA and AM tissues (Pearson's $r = 0.506$, $P < 0.002$) and between ET-1 and ETAR expression levels in UA and ameloblastic carcinoma (AC; Pearson's $r = 0.376$, $P < 0.024$). Table 1 summarizes the chi-square test results.

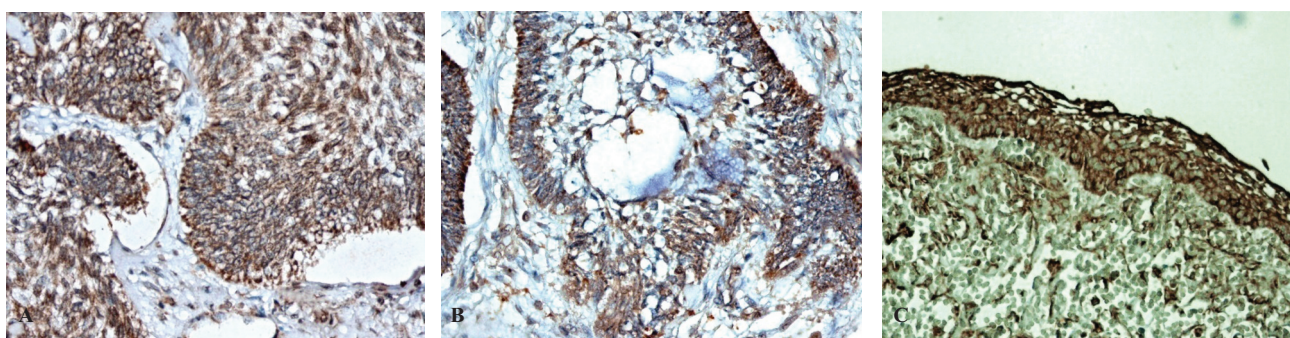


Figure 3. High magnification of immunohistochemically stained sections of ameloblastic carcinoma (A), multicystic ameloblastoma (B) and unicystic ameloblastoma (C) demonstrate cell membrane ETAR strong expression in the basal layer as well as stellate reticulum cells. Cell membrane staining is also evident in stroma cell and vascular endothelial cells.

Discussion

In the present study, we investigated the expression levels of endocan, ET-1, and ETAR at the tissue level for UA, AM, and AC. According to the statistical analysis, there was strong endocan expression in the AC (n=12; 66.7%) tissues, followed by the AM tissues (n=10; 55.6%). A previous study also indicated a steady increase in levels of endocan in different grades of gliomas. The results indicated a positive correlation between the degree of malignancy and endocan level, where the most aggressive tumor had a higher level of endocan. The authors suggested the use of endocan as a marker for malignancy.¹⁵ However, another study on colon cancer tissue samples showed endocan positive staining in well- and moderately-differentiated colorectal cancer, and weak staining in poorly differentiated colorectal cancer samples. The authors suggested that endocan might be closely related with differentiation and development of colorectal cancer.³⁰ Another study of clear cell renal cell carcinoma found rare endocan immunoreactivity in tumor epithelial cells and in intra-tumor vessels.³¹ A published work on pituitary adenoma demonstrated a positive correlation with endocan overexpression and tumor invasiveness.³² In gastric cancer, an association existed between endocan expression and pathological tumor stage.³³ In addition, endocan inhibited gastric cancer cell migration and invasion, and promoted differentiation and apoptosis.³⁴

In our investigation, we did not observe any statistically significant difference between ET-1 expression levels in the studied lesions. However, immunostaining for ET-1 showed strong expression in 66.7% (n=12) of AC cases, followed by 50% (n=9) of AM cases. Endothelin promotes cell proliferation and activates proto-oncogenic genes.³⁵ A steady increase in ET-1 expression levels in UA, AM, and AC can confirm the role of ET-1 in cell proliferation and tumor growth. In addition, these findings have confirmed previous results where peripheral cells (ameloblast-like cells) in AM and AC, and the basal layer cells in UA were involved in tumor growth.³⁶ A high

expression level of ET-1 was detected in 94% of papillary thyroid carcinoma cases.²² Godara et al, in a study on prostate cancer, found a positive correlation between ET-1 expression level with pathologic stage and tumor recurrence.³⁷

In the current study, we observed a high expression level of ETAR in 61.1% (n=11) of AC cases followed by 55.6% (n=10) of AM cases. A study on papillary thyroid cancer reported a high expression level of ETAR in 95% of cases.²¹ Overexpression of ETAR was reported in more aggressive ovarian cancer.³⁸ Additionally, there were higher expression levels of ET-1 and ETAR in primary and metastatic ovarian cancer tissues.³⁹ Although the difference was not significant, our data also showed a trend toward increased ET-1 and ETAR expressions in more aggressive tumors. Previous studies suggested that ETs could activate proto-oncogenic genes and promote cell division.²⁰ In recent years, researchers investigated the association between ETs with tumor growth and metastasis.³⁵ Therefore, it could be hypothesized that ETAR or ET-1 overexpression enhanced tumor progression. The correlations between ET-1 and ETAR expression levels in the examined lesions in the current study have shown that the ET-1/ETAR autocrine pathway is implicated in progression. Notwithstanding, this pathway acts through different tumor relevant processes that include proliferation, angiogenesis, inhibition of apoptosis, migration, invasion, and metastasis.²⁰ Upregulation of ET-1/ETAR proteins occurs in some cancers. However, the expression level is cancer type dependent, which shows a tendency for cancer cell types to use vascular triggers. The expression levels of ET-1 and ETAR might be an indicator that predicts the behavior of the lesion, such as aggression levels and the possibility of metastasis, in addition to the presence and location of metastasis.^{20,21} Several studies have assessed the molecular pathogenesis of AM. They used the cancer stem cell marker (CSC), CD133 in AM and determined that the positive cells were present in the peripheral cell layer of the follicles.⁴⁰ Ki67 positive staining was also found in the peripheral cells of the follicles of AM, and in the basal layer cells of UA.⁴¹

Another finding in this study was the expression levels of endocan, ET-1, and ETAR in the endothelial and stromal cells. Endocan is an endothelial cell activation marker that expresses in vascular endothelial cells in normal tissues. Endocan plays a role in angiogenesis in pathologic processes. Previous studies have indicated that tumor epithelial cells secrete a number of growth factors that stimulate proliferation of endothelial cell and secretion of endocan. In turn, endocan promotes tumor cell proliferation and secretion of more growth factors.¹³

In a published study, elevated ET-1 increased the migration of oral fibroblasts in oral squamous cell carcinoma cells, which promoted cancer cell invasion and showed the contribution of ET-1 in signaling between stromal fibroblasts and cancer cells through both of its receptors.²⁵ Additionally, ET-1 is upregulated in cancer cells due to hypoxia. In turn, ET-1 expression stimulates hypoxic pathways. These events maintain constant vascular expansion.²⁰ A previous report on human colonic fibroblasts has shown that ET-1 and ETAR expressions enhanced production of extracellular matrix modifying proteins and were also involved in tumor development, growth, and migration.⁴² Previous studies have indicated that ET-1 plays a role in tumorigenesis in ovarian, prostate, colon, and oral cancer, and functions on both epithelial cells and the surrounding stroma. In the stroma, fibroblasts are the major cells which undergo several changes such as the acquisition of a myofibroblastic phenotype in response to signals released by malignant epithelial cells. In some diseases, including oral cancer, ET-1 promotes myofibroblast transdifferentiation.²⁵ ET-1 enhances stromal-epithelial interactions in head and neck cancer.⁴³ All three examined markers expressed in the endothelial cells and fibroblasts near the neoplastic odontogenic epithelium. This finding may highlight the supporting role of the tumor stroma in tumor growth.⁴⁴

Additionally, endocan and ET-1 promotes the mitogenic and promigratory activity of VEGF which induces proliferation and migration of endothelial cells.^{13,45} Vascular endothelial growth

factor has been studied in ameloblastoma and ameloblastic carcinoma.¹² These findings suggest that disruption of endocan and ET-1 interactions with VEGF may inhibit tumor angiogenesis.

Conclusion

This study revealed a steady decrease in expression levels of endocan, ET-1, and ETAR from AC (the most aggressive tumor) to UA (the less aggressive lesion). There was a positive correlation between the histological degree of the lesion and endocan, ET-1, and ETAR expression levels.

Hence, it is possible that AM develops from UA and, over time, AM may undergo some malignant transformation to develop into AC. As UA is a variant of AM47 and AC may arise from carcinomatous changes of a pre-existing AM48, it may be logical to conclude that a simple cystic neoplasm progresses to a cystic lesion which invades to the connective tissue wall with gradual development into a true neoplasm (AM) and a possible malignant transformation (AC). There are reports that UA or AM have arisen from a dentigerous cyst.⁴⁸ Tumor growth from an apparently cystic lesion to a carcinoma is a complex process and employs many signals and pathways. Cell proliferation, invasion, and angiogenesis are needed for tumor development. The high expression levels of examined markers in the peripheral and basal layer cells may suggest that these cells are stem cells in different variants of AM. Current research also indicates that endocan, ET-1, and ETAR affect the immunological characteristics of the tumor and angiogenesis. Taken together, endocan, ET-1, and ETAR can be used as prognostic biomarkers in different variants of AM and as possible new targets for cancer therapy. Further research is required to understand the structure and function of these markers.

Acknowledgment

The authors would like to acknowledge funding received from Hamadan University of Medical Sciences.

Conflict of Interest

None declared.

References

- Irani S, Foroughi F. Histologic variants of calcifying odontogenic cyst: A study of 52 cases. *J Contemp Dent Pract.* 2017;18(8):688-94.
- Masthan KM, Anitha N, Krupaa J, Manikkam S. Ameloblastoma. *J Pharm Bioallied Sci.* 2015;7(Suppl 1):S167-70. doi: 10.4103/0975-7406.155891.
- Ricci M, Mangano F, Tonelli P, Barone A, Galletti C, Covani U. An unusual case of unicystic intramural ameloblastoma and review of the literature. *Contemp Clin Dent.* 2012;3(Suppl 2):S233-9. doi: 10.4103/0976-237X.101104.
- Ackermann GL, Altini M, Shear M. The unicystic ameloblastoma: a clinicopathological study of 57 cases. *J Oral Pathol.* 1988;17(9-10):541-6.
- Mahadesh J, Rayapati DK, Maligi PM, Ramachandra P. Unicystic ameloblastoma with diverse mural proliferation - a hybrid lesion. *Imaging Sci Dent.* 2011;41(1):29-33. doi: 10.5624/isd.2011.41.1.29.
- Gomes CC, Duarte AP, Diniz MG, Gomez RS. Review article: Current concepts of ameloblastoma pathogenesis. *J Oral Pathol Med.* 2010;39(8):585-91. doi: 10.1111/j.1600-0714.2010.00908.x.
- Hertog D, Bloemena E, Aartman IH, van-der-Waal I. Histopathology of ameloblastoma of the jaws; some critical observations based on a 40 years single institution experience. *Med Oral Patol Oral Cir Bucal.* 2012;17(1):e76-82.
- Silva FP, Dias A, Coelho CA, Guerra EN, Marques AE, Decurcio DA, et al. Expression of CD90 and P75NTR stem cell markers in ameloblastomas: a possible role in their biological behavior. *Braz Oral Res.* 2016;30(1):e109. doi: 10.1590/1807-3107BOR-2016.vol30.0109.
- Juuri E, Isaksson S, Jussila M, Heikinheimo K, Thesleff I. Expression of the stem cell marker, SOX2, in ameloblastoma and dental epithelium. *Eur J Oral Sci.* 2013;121(6):509-16. doi: 10.1111/eos.12095.
- Yoshioka Y, Toratani S, Ogawa I, Okamoto T. Ameloblastic carcinoma, secondary type, of the mandible: a case report. *J Oral Maxillofac Surg.* 2013;71(1):e58-62. doi: 10.1016/j.joms.2012.09.005.
- Effiom OA, Ogundana OM, Akinshipo AO, Akintoye SO. Ameloblastoma: current etiopathological concepts and management. *Oral Dis.* 2018;24(3):307-16. doi: 10.1111/odi.12646.
- Nagi R, Sahu S, Rakesh N. Molecular and genetic aspects in the etiopathogenesis of ameloblastoma: An update. *J Oral Maxillofac Pathol.* 2016;20(3):497-504.
- Yang J, Yang Q, Yu S, Zhang X. Endocan: A new marker for cancer and a target for cancer therapy. *Biomed Rep.* 2015;3(3):279-83.
- Huang GW, Tao YM, Ding X. Endocan expression correlated with poor survival in human hepatocellular carcinoma. *Dig Dis Sci.* 2009;54(2):389-94. doi: 10.1007/s10620-008-0346-3.
- Atukeren P, Kunbaz A, Turk O, Kemerdere R, Ulu MO, Turkmen Inanir N, et al. Expressions of endocan in patients with meningiomas and gliomas. *Dis Markers.* 2016;2016:7157039. doi: 10.1155/2016/7157039.
- Lin LY, Yeh YC, Chu CH, Won JGS, Shyr YM, Chao Y, et al. Endocan expression is correlated with poor progression-free survival in patients with pancreatic neuroendocrine tumors. *Medicine (Baltimore).* 2017;96(41):e8262. doi: 10.1097/MD.00000000000008262.
- Chang Y, Niu W, Lian PL, Wang XQ, Meng ZX, Liu Y, et al. Endocan-expressing microvessel density as a prognostic factor for survival in human gastric cancer. *World J Gastroenterol.* 2016;22(23):5422-9. doi: 10.3748/wjg.v22.i23.5422.
- Xu Z, Zhang S, Zhou Q, Wang Y, Xia R. Endocan, a potential prognostic and diagnostic biomarker of acute leukemia. *Mol Cell Biochem.* 2014;395(1-2):117-23. doi: 10.1007/s11010-014-2117-0.
- Battistini B, Chailier P, D'Orléans-Juste P, Brière N, Sirois P. Growth regulatory properties of endothelins. *Peptides.* 1993;14(2):385-99.
- Irani S, Salajegheh A, Smith RA, Lam AK. A review of the profile of endothelin axis in cancer and its management. *Crit Rev Oncol Hematol.* 2014;89(2):314-21. doi: 10.1016/j.critrevonc.2013.08.011.
- Irani S, Salajegheh A, Gopalan V, Smith RA, Lam AK. Expression profile of endothelin 1 and its receptor endothelin receptor A in papillary thyroid carcinoma and their correlations with clinicopathologic characteristics. *Ann Diagn Pathol.* 2014;18(2):43-8. doi: 10.1016/j.anndiagpath.2013.11.001.
- Hsieh WT, Yeh WL, Cheng RY, Lin C, Tsai CF, Huang BR, et al. Exogenous endothelin-1 induces cell migration and matrix metalloproteinase expression in U251 human glioblastoma multiforme. *J Neurooncol.* 2014;118(2):257-69. doi: 10.1007/s11060-014-1442-1.
- Alaizari NA, Abdelbary SN, Amin NR. Immunohistochemical expression of endothelin protein in oral squamous cell carcinoma. *Indian J Pathol Microbiol.* 2013;56(2):151-4. doi: 10.4103/0377-4929.118677.
- McKenzie GA, Hinsley EE, Hunter K, Lambert DW. The endothelin axis in head and neck cancer: a promising therapeutic opportunity? *J Oral Pathol Med.* 2014;43(6):395-404. doi: 10.1111/jop.12108.
- Hinsley EE, Kumar S, Hunter KD, Whawell SA, Lambert DW. Endothelin-1 stimulates oral fibroblasts to promote oral cancer invasion. *Life Sci.* 2012;91(13-14):557-61. doi: 10.1016/j.lfs.2012.04.001.
- Said N, Theodorescu D. Permissive role of endothelin receptors in tumor metastasis. *Life Sci.* 2012;91(13-14):522-7. doi: 10.1016/j.lfs.2012.03.040.
- Bagnato A, Rosanò L. Epithelial-mesenchymal transition in ovarian cancer progression: a crucial role for the endothelin axis. *Cells Tissues Organs.* 2007;185(1-3):85-94.

28. Carreón-Burciaga RG, González-González R, Molina-Frechero N, Bologna-Molina R. Immunoexpression of Ki-67, MCM2, and MCM3 in ameloblastoma and ameloblastic carcinoma and their correlations with clinical and histopathological patterns. *Dis Markers*. 2015;2015:683087. doi: 10.1155/2015/683087.
29. Irani S, Dehghan A. Expression of vascular endothelial-cadherin in mucoepidermoid carcinoma: role in cancer development. *J Int Soc Prev Community Dent*. 2017;7(6):301-7. doi: 10.4103/jispcd.JISPCD_323_17.
30. Zuo L, Zhang SM, Hu RL, Zhu HQ, Zhou Q, Gui SY, et al. Correlation between expression and differentiation of endocan in colorectal cancer. *World J Gastroenterol*. 2008;14(28):4562-8.
31. Leroy X, Aubert S, Zini L, Franquet H, Kervoaze G, Villers A, et al. Vascular endocan (ESM-1) is markedly overexpressed in clear cell renal cell carcinoma. *Histopathology*. 2010;56(2):180-7. doi: 10.1111/j.1365-2559.2009.03458.x.
32. Miao Y, Zong M, Jiang T, Yuan X, Guan S, Wang Y, et al. A comparative analysis of ESM-1 and vascular endothelial cell marker (CD34/CD105) expression on pituitary adenoma invasion. *Pituitary*. 2016;19(2):194-201. doi: 10.1007/s11102-015-0698-6.
33. Zhao W, Sun M, Li S, Wang Y, Liu J. Biological and clinical implications of endocan in gastric cancer. *Tumour Biol*. 2014;35(10):10043-9. doi: 10.1007/s13277-014-2287-0.
34. Sumei Z, Shaolong C, Xiang W, Yinliang Q, Qing Z, Yuan W. Endocan reduces the malign grade of gastric cancer cells by regulating associated protein expression. *Tumour Biol*. 2016;37(11):14915-21.
35. Zhang ZY, Chen LL, Xu W, Sigdel K, Jiang XT. Effects of silencing endothelin-1 on invasion and vascular formation in lung cancer. *Oncol Lett*. 2017;13(6):4390-4396. doi: 10.3892/ol.2017.6027.
36. Jääskeläinen K, Jee KJ, Leivo I, Saloniemä I, Knuutila S, Heikinheimo K. Cell proliferation and chromosomal changes in human ameloblastoma. *Cancer Genet Cytogenet*. 2002;136(1):31-7.
37. Godara G, Pecher S, Jukic DM, D'Antonio JM, Akhavan A, Nelson JB, et al. Distinct patterns of endothelin axis expression in primary prostate cancer. *Urology*. 2007;70(1):209-15.
38. Salani D, Di Castro V, Nicotra MR, Rosanò L, Tecce R, Venuti A, et al. Role of endothelin-1 in neovascularization of ovarian carcinoma. *Am J Pathol*. 2000;157(5):1537-47.
39. Bagnato A, Salani D, Di Castro V, Wu-Wong JR, Tecce R, Nicotra MR, et al. Expression of endothelin 1 and endothelin A receptor in ovarian carcinoma: evidence for an autocrine role in tumor growth. *Cancer Res*. 1999;59(3):720-7.
40. Sathi GA, Tamamura R, Tsujigiwa H, Katase N, Lefevre M, Siar CH, et al. Analysis of immunoexpression of common cancer stem cell markers in ameloblastoma. *Exp Ther Med*. 2012;3(3):397-402.
41. Bologna-Molina R, Mosqueda-Taylor A, Lopez-Corella E, Almeida OP, Carrasco-Daza D, Garcia-Vazquez F, et al. Syndecan-1 (CD138) and Ki-67 expression in different subtypes of ameloblastomas. *Oral Oncol*. 2008;44(8):805-11. doi: 10.1016/j.oraloncology.2007.10.007.
42. Knowles JP, Shi-Wen X, Haque SU, Bhalla A, Dashwood MR, Yang S, et al. Endothelin-1 stimulates colon cancer adjacent fibroblasts. *Int J Cancer*. 2012;130(6):1264-72. doi: 10.1002/ijc.26090.
43. Hinsley EE, Hunt S, Hunter KD, Whawell SA, Lambert DW. Endothelin-1 stimulates motility of head and neck squamous carcinoma cells by promoting stromal-epithelial interactions. *Int J Cancer*. 2012;130(1):40-7. doi: 10.1002/ijc.25968.
44. Principe S, Mejia-Guerrero S, Ignatchenko V, Sinha A, Ignatchenko A, Shi W, et al. Proteomic analysis of cancer-associated fibroblasts reveals a paracrine role for MFAP5 in human oral tongue squamous cell carcinoma. *J Proteome Res*. 2018;17(6):2045-59. doi: 10.1021/acs.jproteome.7b00925.
45. Wu MH, Huang CY, Lin JA, Wang SW, Peng CY, Cheng HC, et al. Endothelin-1 promotes vascular endothelial growth factor-dependent angiogenesis in human chondrosarcoma cells. *Oncogene*. 2014;33(13):1725-35. doi: 10.1038/onc.2013.109.
46. Chaudhary Z, Sangwan V, Pal US, Sharma P. Unicystic ameloblastoma: A diagnostic dilemma. *Natl J Maxillofac Surg*. 2011;2(1):89-92. doi: 10.4103/0975-5950.85863.
47. Gunaratne DA, Coleman HG, Lim L, Morgan GJ. Ameloblastic carcinoma. *Am J Case Rep*. 2015;16:415-9. doi: 10.12659/AJCR.893918.
48. Bhushan NS, Rao NM, Navatha M, Kumar BK. Ameloblastoma arising from a dentigerous cyst-a case report. *J Clin Diagn Res*. 2014;8(5):ZD23-5. doi: 10.7860/JCDR/2014/5944.4387.